

Differences between finger and toe Meissner corpuscles: Searching for the optimal place to analyze meissner corpuscles in cutaneous biopsy

Patricia Cuendias^{a,1}, Rebeca del Rio^{a,1}, Olivia García-Suárez^a, Ramón Cobo^a,
 Marialuisa Aragona^b, Jorge Feito^{a,c}, Benjamín Martín-Biedma^d, José A. Vega^{a,e,*},
 Yolanda García-Mesa^a

^a Grupo SINPOS, Departamento de Morfología y Biología Celular, Universidad de Oviedo, Spain

^b Dipartimento di Scienze Veterinarie, Università di Messina, Messina, Italy

^c Servicio de Anatomía Patológica, Complejo Asistencial Universitario de Salamanca, Salamanca, Spain

^d Departamento de Cirugía y Especialidades Médico-Quirúrgicas, Universidad de Santiago de Compostela, Spain

^e Facultad de Ciencias de la Salud, Universidad Autónoma de Chile, Santiago-Providencia, Chile

ARTICLE INFO

Keywords:

Meissner's corpuscles density
 Meissner's morphometry
 Finger
 Toe
 Cutaneous biopsy
 Human

ABSTRACT

Background: Skin biopsy is a minimally invasive and repeatable technique, applicable in any part of the body that can allow for diagnosis and control of treatments, but to analyze Meissner corpuscles biopsy of glabrous skin is necessary it is recommendable obtained the maximal amount it is possible. Changes in density, size, and morphology occurs in several peripheral neuropathies as well as diseases affecting the central nervous system.
Methods: We used immunohistochemistry and image analysis to establish differences in the immunohistochemical profile, density, morphology, size and depth relative to the epidermis of Meissner's corpuscles from fingers and toes in a homogeneous age-group.

Results: The morphology of Meissner corpuscles was variable. In fingers ellipsoidal non-lobulated corpuscles predominate (about 82%) while in toes most of them showed irregular morphology (60%). No differences between fingers and toes were noted in the basic immunohistochemical profile, except for capsulation. The mean density of Meissner corpuscles was $3,22 \pm 0,86/\text{mm}^2$ and $1,15 \pm 0,71/\text{mm}^2$, respectively; and the Meissner corpuscles index was $1,09 \pm 0,07$ and $0,28 \pm 0,09$, respectively. Regarding the size Meissner corpuscles from the fingers measured $108 \pm 24.2 \mu\text{m} \times 64 \pm 9 \mu\text{m}$, and those from toes $87 \pm 21.2 \mu\text{m} \times 34 \pm 6 \mu\text{m}$. Finally, the depth relative to the epidermis was $3.6 \pm 0.9 \mu\text{m}$ in fingers and $19 \pm 16.2 \mu\text{m}$ in toes.

Conclusion: the study of Meissner corpuscles in cutaneous biopsy from fingers may offer advantages over that from toes because in fingers Meissner's corpuscles are more abundant and superficial, larger, and express more regularly the defining markers of the main corpuscular components.

1. Introduction

The human glabrous skin of fingers, toes, palms, soles, lips, eyelids, nipples, and genital organs, typically contains a kind of mechanosensory organ called Meissner's corpuscle (MC), which are present at different densities in those anatomical localizations [1–3]. Similar structures are present in several mammalian species and are denominated Meissner-like corpuscles [1,4].

Typically MCs are show ellipsoid morphology and variable size with the main axis perpendicular to the skin surface (major axis of 80–150 μm

and minor axis of 20–40 μm). Structurally, they consist of a central axon from an A β low-threshold mechanoreceptor, non-myelinating terminal glial cells called lamellar cells, and a thin capsule of endoneurial cells [4, 5].

Since the last half of the past century, the analysis of MCs in cutaneous biopsy become a complementary method to diagnose peripheral neuropathies, and a reliable alternative to peripheral nerve biopsy [6–13]. Obviously, skin biopsy to analyze MCs can be virtually obtained from anybody area of glabrous skin. Nevertheless, to guarantee a maximal number of MCs the choice of the appropriate anatomical region

* Corresponding author. Grupo SINPOS, Departamento de Morfología y Biología Celular, Universidad de Oviedo, Spain.

E-mail address: javega@uniovi.es (J.A. Vega).

¹ Both authors contributed equally to this paper.

<https://doi.org/10.1016/j.tria.2023.100234>

Received 6 December 2022; Received in revised form 5 February 2023; Accepted 5 February 2023

Available online 10 February 2023

2214-854X/© 2023 The Authors. Published by Elsevier GmbH. This is an open access article under the CC BY-NC-ND license (<http://creativecommons.org/licenses/by-nc-nd/4.0/>).

is of interest.

Thus, we planned this research to compare the morphology, size and density of MCs in two anatomical regions easily accessible for biopsy, i.e. fingers and toes, to provide data that can serve as baseline for monitoring neurological diseases involving MCs.

2. Materials and methods

2.1. Materials

The study was performed on glabrous skin samples $0,5 \times 0,5 \times 0,5$ cm taken from the distal phalanx of the left and right second finger and second toe. The tissues were obtained from the Human Tissue Bank (National Registry of Biobanks, Collections Section; Ref. C-0001627) associated to the research Group SINPOS (Peripheral Nervous System and Sense Organs Group, Spanish acronym) of the University of Oviedo. They corresponded to 20 subjects with no clinical history of neurological disease, with an age-range between 40 and 65 years (mean age 54.6), and equality between men and women. The materials were fixed with 10% formol (in 1 M PBS, pH 7.4), routinely paraffin embedded, and cut at $7 \mu\text{m}$ thick perpendicular to the skin surface.

These materials are being used in different studies and its use has been authorized by the Research Ethics Committee of the Principality of Asturias (Cod CEIm P Ast: proyect 266/18). The materials were obtained in compliance with Spanish legislation (RD 1301/2006; Law 14/2007; RD 1716/2011; Order ECC/1404/2013) and in accordance with the guidelines of the Declaration of Helsinki II.

2.2. Simple immunohistochemistry

Sections were deparaffinized and rehydrated then permeabilized with 1 M PBS at pH 7.6 with 0.5% Tween-20 and endogenous peroxidase activity was blocked with 10% H_2O_2 for 30 min. Nonspecific binding was then blocked with 25% fetal bovine serum and samples were incubated at 4°C in a humid chamber with a rabbit polyclonal antibody against β -S100 protein (S100P) used diluted 1:1000 (Ventana Medical Systems, Oro Valley, Arizona, USA; Cobo et al., 2021). Slides were then incubated with anti-rabbit IgG for 90 min. After another washing in TBS-T, the specific antigen-antibody reaction was revealed using 3-3'-diaminobenzidine as chromogen. Finally, sections were counterstained with hematoxylin and mounted with Entellan®. Photographs of the samples were taken on a Nikon Eclipse® 80i optical microscope coupled to a Nokia® DS-5M camera.

As controls, representative sections were processed in the same way as described above using non-immune rabbit or mouse sera instead of primary antibodies or while omitting the primary antibodies during the incubation.

2.3. Double immunofluorescence.-

The main constituents of MCs were identified using antibodies against neurofilament proteins (NFP; clone 2F11; Cell Marke, Rocklin, California, USA; raised in mouse and used diluted 1:1000), synaptophysin (SYN; clone DAK-SYNAP; DAKO, Glostrup, Denmark; raised in mouse and used diluted 1:200); S100P (see above), CD34 (clone QB-END-10; Master Diagnostica, Granada, Spain; purchased prediluted), and collagen type IV (clone CIV22; ThermoFisher, Waltham, MA, USA; raised in mouse and used diluted 1:200).

Sections were deparaffinized and rehydrated using the same procedure described previously and washed in PBS-T for 20 min. Then, sections were incubated overnight at 4°C in a humid chamber with a 1:1 mixture of S100P together with NFP, SYN, CD34 or collagen type IV. Subsequently, the sections were washed with PBS-T for 30 min and incubated for 90 min with Alexa Fluor 488-conjugated goat anti-rabbit IgG (1:100; Serotec™, Oxford, UK) followed for 90 min with Cy3-conjugated donkey anti-mouse IgG (1:200; Jackson-

ImmunoResearch™, Baltimore, MD, USA). Both incubations were conducted in a humid chamber, in the dark and at room temperature. After washing in PBS the sections were stained with DAPI (4',6-diamino-2-phenylindole; 10 ng/ml) to contrast the nuclei (blue color) and mounted with diluted Fluoromount-G mounting medium (Southern-Biotech, Alabama, USA). Immunofluorescence was detected using a Leica DMR-XA automated fluorescence microscope coupled to Leica Confocal Software v2.5 fluorescence capture software (Leica Microsystems, Heidelberg GmbH, Germany), from the Image Processing Service of the University of Oviedo. Specific reaction controls were performed in the same way as for simple immunohistochemistry. Additional controls were conducted to confirm the absence of autofluorescence processes of the tissue or produced by the fixation process omitting both antibodies.

2.4. Quantitative study

The density of MCs in the glabrous skin of the fingers and toes was established analyzing 5 sections per skin sample, separated from each other by $100 \mu\text{m}$, processes for the detection of S100P. Once the immunoreaction was visualized and the coverslip was mounted, the sections were scanned using the SCN400F scanner (Leica Biosystems™) and computer processed with the SlidePath Gateway LAN program (Leica Biosystems™) at the Histopathology Laboratory, University Institute of Oncology of the Principality of Asturias. The number of MCs was evaluated by two independent observers in ten fields per sections enlarged $\times 10$, and the results obtained were averaged. Data are expressed as mean \pm standard deviation/ mm^2 . MCs density was calculated as follows:

$$\text{Density} = \frac{\text{Number of Meissner's corpuscles}}{\text{Skin area}}$$

In addition, the MCs Index was calculated on the same sections, using the method proposed by Refs. [14,15]. This method makes it possible to establish the number of MCs in relation to the total number of dermal papillae. To compare the groups, the measurements were standardized for the length of the skin sample analyzed (for details see Ref. [16]).

Using the same software, the size of MCs was calculated in 50 MCs from fingers and 50 MCs from toes randomly selected, measuring the major axis (the maximal distance between the two poles) and minor axis (evaluated perpendicular to the major axis at the middle length). Finally, the distance between the apical part MCs and the basement membrane at the dermo-epidermal junction was measured. Finally, Results for both parameters are in μm and the data are presented as mean \pm standard deviation/ mm^2 .

The normal distribution of all parameters was assessed using the Kolmogorov-Smirnov test: a *t*-test was used for paired data and analysis of variance for repeated measurements to assess differences between fingers and toes. A *p* value ≤ 0.05 was considered as significant.

3. Results

3.1. Morphology and basic immunohistochemical profile

MCs from fingers predominantly showed an ellipsoidal morphology (about 82%) but rounded (11%) and irregular (7%) were also found (Fig. 1); almost all were compact (around 88%), without lobulations (about 10%). By contrast, most MCs in toes displayed irregular morphology (60%), only a quarter showed typical ellipsoid morphology (27%) and the remaining ones were rounded (about 13%); consistently, the percentage of lobulated MCs in toes (21%) was higher than in fingers (Fig. 1; Table 1).

Regarding the basic immunohistochemical profile no differences between fingers and toes were noted, except for capsulation. In all cases the axons were immunoreactive for NFP and SYN while the lamellar cells displayed strong immunoreactivity for S100P. Nevertheless, MCs from fingers and toes differed in the expression of CD34. In fact, a CD34

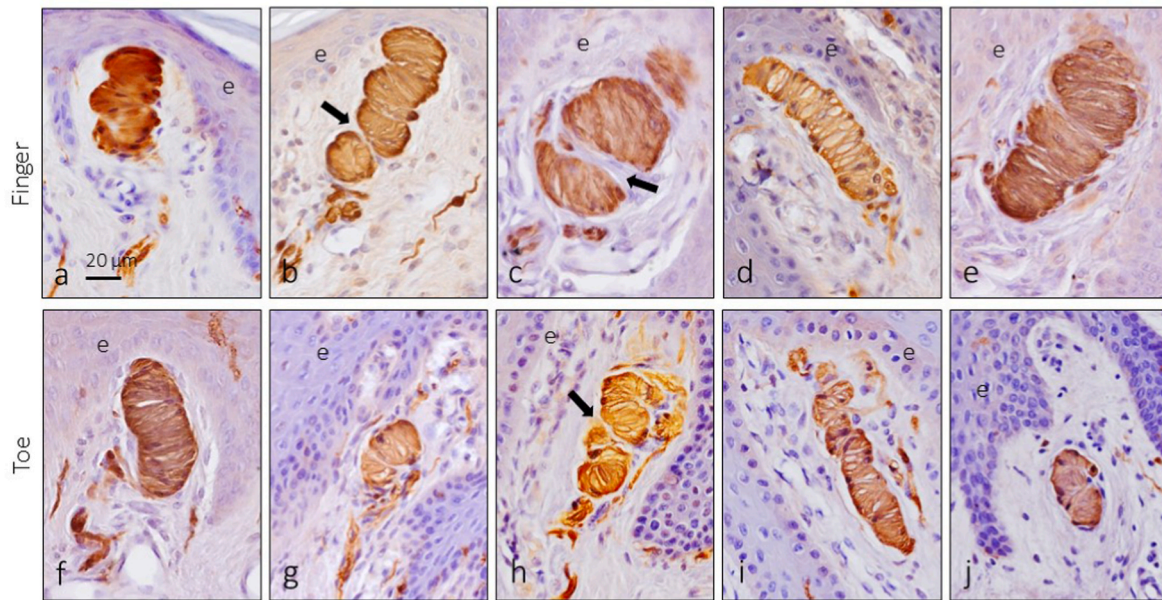


Fig. 1. Different morphotypes of Meissner corpuscles from fingers (upper figures, a-e) and toes (bottom figures, f-j) as showed using immunohistochemistry for S100 protein. Arrows indicate lobulations. e: epidermis. Scale bar is the same for all images.

Table 1
- Morphological and immunohistochemical differences between Meissner’s corpuscles from fingers and toes.

		Fingers	Toes
Morphology	Ellipsoidal	82%	27%*
	Rounded	11%	13%
	Irregular	7%	60%*
Lobulation	Yes	5%	21%*
	No	95%	79%
IHC Profile	NFP	Positive	Positive
	S100P	Positive	Positive
	C: 43%	C: 43%	C: 29%
	P: 38%	P: 38%	P: 26%
		NC: 19%	NC: 45%*
Density (MC/mm ²)		3,22 ± 0,86	1,15 ± 0,71*
MC index		1,09 ± 0,07	0,28 ± 0,09*
Size (µm)	Major axis	108 ± 24.2	87 ± 21.2*
	Minor axis	64 ± 9	34 ± 6*
Depth (µm)		3.6 ± 0.9 µm	19 ± 16.2*

C: total capsulation; P: partial capsulation; NC: no capsulation.

*p < 0.01.

positive capsule was observed complete (43%) or incomplete (38%) in fingers, while only about one half of MCs showed evidence of a complete (29%) or partial (26%) capsule in toes (Fig. 2 and 3; Table 1).

3.2. Density of meissner corpuscles

We analyzed the density of MCs in the palmar and plantar skin from the distal phalanx of the second fingers and toes. MCs were identified based on the immunoreactivity for S100 protein of the lamellar cells. The mean density of 3,22 ± 0,86 MCs/mm² and 1,15 ± 0,71 MCs/mm² in fingers and toes, respectively. Regarding the MC index the values were 1,09 ± 0,07 in fingers and 0,28 ± 0,09 in toes. Thus, the density of MCs in the skin of distal phalanx of the first finger almost doubled that of counterparts in toes (Fig. 4; Table 1).

3.3. Size of meissner corpuscles

We have randomly measured 100 Meissner’s corpuscles from the anatomical localizations selected. Both the major (longitudinal) and minor (transversal) axes varied between fingers and toes, as well as within the same section. Nevertheless, no differences were noted

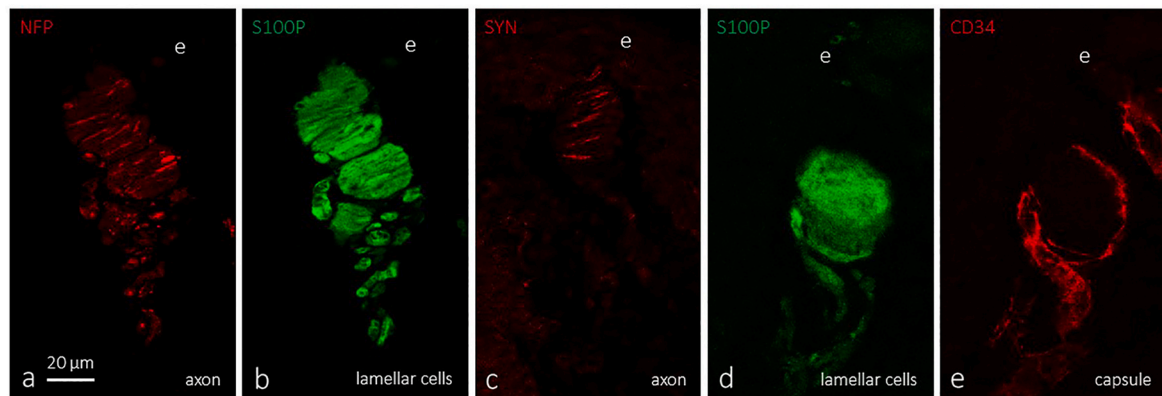


Fig. 2. Immunofluorescence for the main corpuscular constituents: axon (NFP and synaptophysin; a and c), lamellar cells (S100P; b and d) and capsule (CD34; e). Objective: 63X/1.40 oil; pinhole: 1.37; XY resolution: 139.4 nm; and Z resolution: 235.8 nm. e: epidermis. Scale bar is the same for all images.

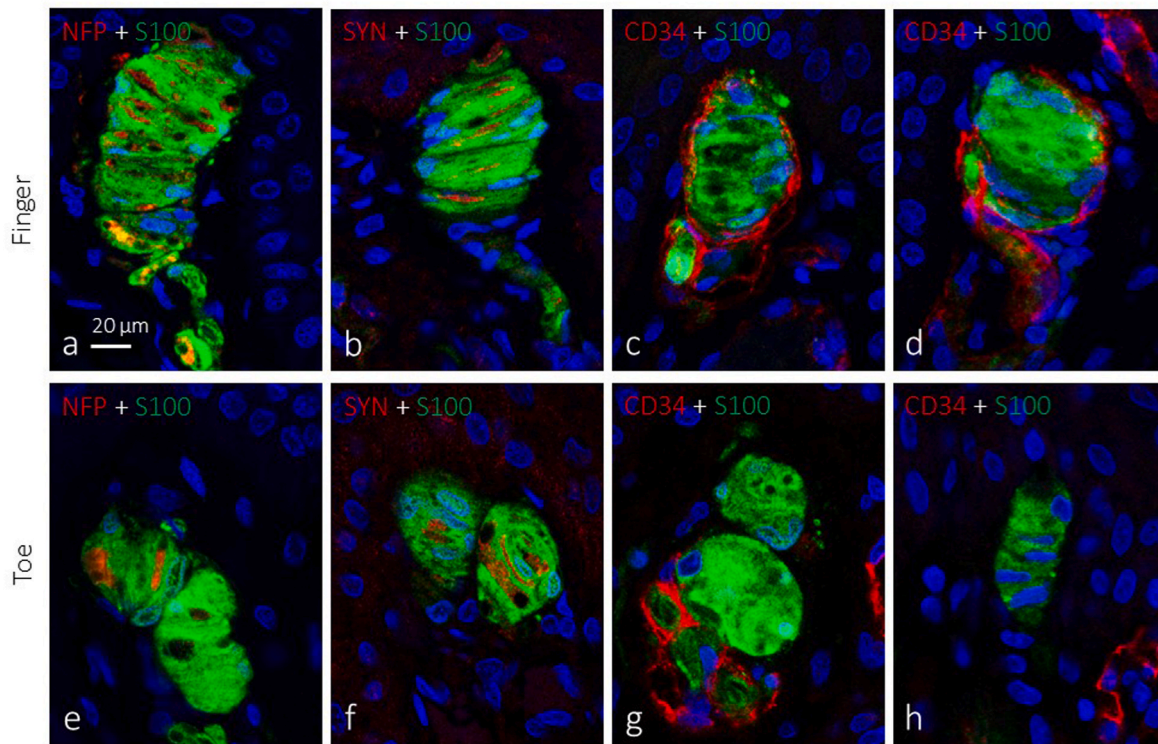


Fig. 3. Dual immunofluorescence for NFP and SYN (red fluorescence; a, b, e, and f) and S100 protein (green fluorescence; a-h) or CD34 (red fluorescence; c, d, g, and h) in finger and toe Meissner corpuscles. Objective: 63X/1.40 oil; pinhole: 1.37; XY resolution: 139.4 nm; and Z resolution: 235.8 nm. Scale bar is the same for all images. (For interpretation of the references to color in this figure legend, the reader is referred to the Web version of this article.)

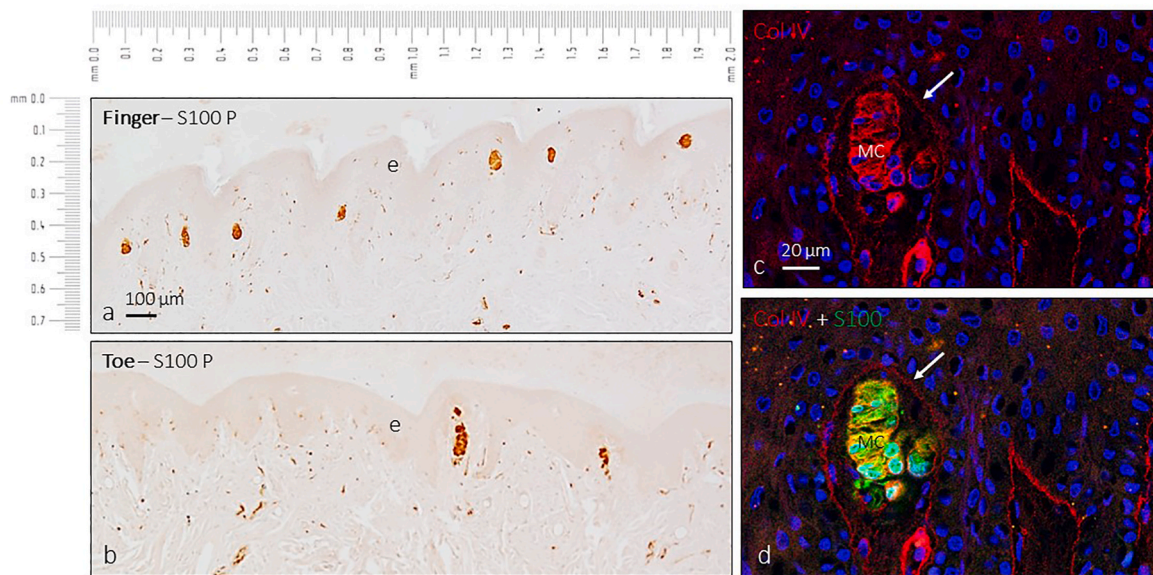


Fig. 4. Samples of images from the second finger (a) or toe (b) used to establish Meissner’s corpuscles density, size, and depth relative to the epidermis. c show immunofluorescence collagen type IV (red fluorescence); d show dual immunofluorescence S100 protein (green fluorescence; a-h) and collagen type IV (red fluorescence). Arrows indicate the basement membrane at the dermo-epidermal junction. Objective: 63X/1.40 oil; pinhole: 1.37; XY resolution: 139.4 nm; and Z resolution: 235.8 nm. Scale is the same for a and b; scale bar is the same for c and d. (For interpretation of the references to color in this figure legend, the reader is referred to the Web version of this article.)

between the first digits of the hand and foot. The mean values for finger MCs were $108 \pm 24.2 \mu\text{m}$ (range 61–167 μm) of longitudinal axis, and $64 \pm 9 \mu\text{m}$ (range 43–104) of transversal axis; for toe Meissner corpuscles were $87 \pm 21.2 \mu\text{m}$ (range 39–126 μm) of longitudinal axis, and $34 \pm 6 \mu\text{m}$ (range 19–77) of transversal axis (Table 1).

3.4. Depth relative to the epidermis

Finally, we measured the distance between the apical pole of Meissner’s corpuscles and the basement membrane of the dermo-epidermal junction at the level of the dermal papillae, immunolabelled for collagen type IV. As a rule MC in fingers were close to the

basement membrane ($3.6 \pm 0.9 \mu\text{m}$; range 1.9–11.0 μm) while in toes they were placed deeper in the dermis (19 ± 16.2 ; range 5.8–26.9 μm) (Table 1). It must be noted that in agreement with previous studies the basement membrane of the lamellar cells displayed collagen type IV immunoreactivity [17,18].

For all parameter evaluated no gender differences were observed.

4. Discussion

In this study we have investigated differences between finger and toe MCs, the research being aimed to recommend one or one other for cutaneous biopsy. We selected the distal phalanx of the second finger and toe since they are regarded as the zone of higher counts of MCs. Recently [3], observed that there are greater differences in the quantity of MCs between finger regions, or between individuals, but not between digits. Similar studies have not been published, to our knowledge, in toes. On the other hand, we have concentrated the study on a range of age in which the number of MCs remains stable [16]. Although some authors affirm that MCs density does not change significantly with age [19] age-dependent reduction was reported in both fingers [16,20] and toes [21].

Here we report that the density of MCs has a ratio of 3:1 in fingertips vs toe-tips, and those from toes are smaller, less organized structurally (since a high proportion are non-capsulated) and placed deeper in the dermis. We have not found gender differences in none of the evaluated parameters.

According to Ref. [22]; variations in the density and size (atrophy and/or hypertrophy) of MCs can reflect pathologies of the somatosensory peripheral nervous system, i.e., the primary sensory nerves, nerve fibres supplying them or in the cells forming MCs themselves. Thus, variations in the density and morphology of MC are evidenced in diabetic neuropathy [23,24], Charcot-Marie-Tooth disease [25–28], human immunodeficiency virus neuropathy [29], entrapment neuropathies [30,31], and other rare peripheral neuropathies [32–35]; for a review recent and references see Ref. [36].

Even more, changes in MCs might also reflect pathologies of the central nervous system [37–43] and psychiatric disorders and mental deficiencies [44,45].

Therefore, in some diseases of the peripheral and central nervous system the study of MCs from minimal invasiveness cutaneous biopsy (less invasive than nerve biopsy) becomes a method not only for diagnostics but also for following the progression or the effects of a treatment. Furthermore, new methods are emerging to evaluate MCs through noninvasive techniques, like *in vivo* reflectance confocal microscopy [20,46]. Nevertheless, variations in MCs size and morphology can be difficult to evaluate because of their large variability. In the absence of evident atrophy, hypertrophy, or corpuscular disruption, the evaluation of these parameters must be cautiously considered. Surely, apart from quantitative, qualitative data on changes in protein composition of MCs should be necessary to accurately obtain information from MCs for following of neurological diseases. In addition to immunohistochemical studies that can show changes in the patterns of protein expression with respect to healthy MCs [4], skin biopsy is amenable to mRNA extraction or microarrays for genes involved in neuropathies (see Ref. [47]).

In any case, in both quantitative and qualitative studies on MCs, the choice of biopsy site is important. Based on present results, we propose as priority the fingers over toes, because in fingers MCs are more abundant and easily accessible to cutaneous biopsy, larger, more superficial and express more regularly the defining markers of the main components of the corpuscles. However, further studies are necessary to definitively validate the use of cutaneous Meissner corpuscles as a clinical tool for diagnosis and following of neurological diseases. The present study is limited by the number of subjects analyzed, only 20, it would be convenient to extend it to a larger age-range, and include in the study other fingers of both the hand and the foot.

Ethical statement

This study was approved by the Ethical Committee for Biomedical Research of the Principality of Asturias, Spain (Cod. CELM, PAST: Proyecto 266/18).

Funding statement

Y. G-M. (PA-18-PF-BP17-044) and P.C. (PA-21-PF-BP20-122) were supported by Grants “Severo Ochoa Program” from the Govern of the Principality of Asturias.

CRediT authorship contribution statement

Patricia Cuendias: Conceptualization, Methodology, Experiments, Writing- Original draft. **Rebeca del Río:** Experiments, Writing- Original draft. **Olivia García-Suárez:** Visualization, Investigation. **Ramón Cobo:** Experiments, Writing- Original draft. **Marialuisa Aragon:** Experiments, Writing- Original draft. **Jorge Feito:** Experiments, Writing- Original draft. **Benjamin Martín-Biedma:** Experiments, Writing- Original draft. **José A. Vega:** Conceptualization, Methodology, Supervision, Writing – review & editing. **Yolanda García-Mesa:** Conceptualization, Methodology.

Declaration of competing interest

The authors declare that there are no conflict of interest regarding the publication of this paper.

Acknowledgements

P.C. (PA-21-PF-BP20-122) and Y. G-M. (PA-18-PF-BP17-044) were supported by Grants “Severo Ochoa Program” from the Govern of the Principality of Asturias. The assistance of Dr. Marta Guervos for confocal microscopy is acknowledged.

References

- [1] J.A. Vega, A. López-Muñiz, M.G. Calavia, O. García-Suárez, J. Cobo, J. Otero, O. Arias-Carrión, P. Pérez-Piñera, M. Menéndez-González, Clinical implication of Meissner's corpuscles. *CNS, Neurol. Disord. Drug. Targets.* 11 (2012) 856–868, <https://doi.org/10.2174/1871527311201070856>.
- [2] S.H. Kim, Y.H. Lee, Re-evaluation of the distribution of Meissner's corpuscles in human skin, *Anat. Cell. Biol.* 53 (3) (2020) 325–329, <https://doi.org/10.5115/acb.20.105>.
- [3] J. Ciano, B.L. Beatty, Regional variation in the density of Meissner's corpuscles in human fingers, *Ann. Anat.* 243 (2022), 151946. <https://doi.org/10.1016/j.aanat.2022.151946>.
- [4] R. Cobo, J. García-Piqueras, J. Cobo, J.A. Vega, The human cutaneous sensory corpuscles: an update, *J. Clin. Med.* 10 (2) (2021) 227. <https://doi.org/10.3390/jcm10020227>.
- [5] A. Zimmerman, L. Bai, D.D. Ginty, The gentle touch receptors of mammalian skin, *Science* 346 (2014) 950–954, <https://doi.org/10.1126/science.1254229>.
- [6] P.J. Dyck, R.K. Winkelmann, C.F. Bolton, Quantitation of Meissner's corpuscles in hereditary neurologic disorders. Charcot-Marie-Tooth disease, Roussy-Levy syndrome, Dejerine-Sottas, disease, hereditary sensory neuropathy, spinocerebellar degenerations, and hereditary spastic paraplegia, *Neurology* 16 (1966) 10–17, <https://doi.org/10.1212/wnl.16.1.10>.
- [7] P.J. Dyck, Enumerating Meissner corpuscles: future gold standard of large fiber sensorimotor polyneuropathy? *Neurology* 69 (2007) 2116–2118, <https://doi.org/10.1212/01.wnl.0000286934.55620.96>.
- [8] D.N. Herrmann, J.N. Boger, C. Jansen, C. Aessi-Fox, In vivo confocal microscopy of Meissner corpuscles as a measure of sensory neuropathy, *Neurology* 69 (2007) 2121–2127, <https://doi.org/10.1212/01.wnl.0000282762.34274.94>.
- [9] C. Sommer, Skin biopsy as a diagnostic tool, *Curr. Opin. Neurol.* 21 (2008) 562–568, <https://doi.org/10.1097/WCO.0b013e328309000c>.
- [10] M. Nolano, V. Provitera, G. Caporaso, A. Stancanelli, M. Leandri, A. Biasiotta, G. Cruccu, L. Santoro, A. Truini, Cutaneous innervation of the human face as assessed by skin biopsy, *J. Anat.* 222 (2013) 161–169. <https://doi.org/10.1111/joa.12001>.
- [11] V. Provitera, G. Piscoquito, F. Manganelli, S. Mozzillo, G. Caporaso, A. Stancanelli, I. Borreca, G. Di Caprio, L. Santoro, M. Nolano, A model to study myelinated fiber degeneration and regeneration in human skin, *Ann. Neurol.* 87 (2020) 456–465. <https://doi.org/10.1002/ana.25662>.

- [12] S.R. Ramnarine, P.M. Dougherty, R. Rolke, L.J. Williams, C. Alessi-Fox, A. J. Coleman, C. Longo, L.A. Colvin, M.T. Fallon, The value of in vivo reflectance confocal microscopy as an assessment tool in chemotherapy-induced peripheral neuropathy: a pilot study, *Oncol.* 27 (2022) e671–e680, <https://doi.org/10.1093/oncolo/oyac106>.
- [13] D.N. Herrmann, Noninvasive and minimally invasive detection and monitoring of peripheral neuropathies, *Expert Rev. Neurother.* 8 (2008) 1807–1816, <https://doi.org/10.1586/14737175.8.12.1807>.
- [14] M. Paré, P.J. Albrecht, C.J. Noto, N.L. Bodkin, G.L. Pittenger, D.J. Schreyer, X. T. Tigno, B.C. Hansen, F.L. Rice, Differential hypertrophy and atrophy among all types of cutaneous innervation in the glabrous skin of the monkey hand during aging and naturally occurring type 2 diabetes, *J. Comp. Neurol.* 501 (4) (2007) 543–567, <https://doi.org/10.1002/cne.21262>.
- [15] G. Bhat, M. Bhat, K. Kour, D.B. Shah, Density and structural variations of Meissner's corpuscle at different sites in human glabrous skin, *J. Anat. Soc. India* 57 (2008) 30–33.
- [16] J. García-Piqueras, Y. García-Mesa, L. Cárcaba, J. Feito, I. Torres-Parejo, B. Martín-Biedma, J. Cobo, O. García-Suárez, J.A. Vega, Ageing of the somatosensory system at the periphery: age-related changes in cutaneous mechanoreceptors, *J. Anat.* 234 (2019) 839–852, <https://doi.org/10.1111/joa.12983>.
- [17] J.A. Vega, I. Esteban, F.J. Naves, M.E. del Valle, L. Malinovsky, Immunohistochemical localization of laminin and type IV collagen in human cutaneous sensory nerve formations, *Anat. Embryol.* 191 (1995) 33–39, <https://doi.org/10.1007/BF00215295>. PMID: 7717531.
- [18] J. García-Piqueras, O. García-Suárez, Y. García-Mesa, B. García-Fernandez, L. M. Quirós, R. Cobo, B. Martín-Biedma, J. Feito, J.A. Vega, Heparan sulfate in human cutaneous Meissner's and Pacinian corpuscles, *Anat. Rec.* 303 (2020) 2262–2273, <https://doi.org/10.1002/ar.24328>.
- [19] E.J. Kelly, G. Terenghi, A. Hazari, M. Wiberg, Nerve fiber and sensory end organ density in the epidermis and papillary dermis of human hand, *Br. J. Plast. Surg.* 58 (2005) 774–779, <https://doi.org/10.1016/j.bjps.2004.12.017>.
- [20] P.D. Creigh, K. Du, E.P. Wood, J. Mountain, J. Sowden, J. Charles, S. Behrens-Spraggins, D.N. Herrmann, In vivo reflectance microscopy of meissner corpuscles and bedside measures of large fiber sensory function: a normative data cohort, *Neurology* 98 (2022) e750–e758, <https://doi.org/10.1212/WNL.0000000000003175>.
- [21] K. Schimrigk, H. Rüttinger, The touch corpuscles of the plantar surface of the big toe. Histological and histometrical investigations with respect to age, *Eur. Neurol.* 19 (1980) 49–60, <https://doi.org/10.1159/000115128>. PMID: 7371654.
- [22] M. Nolano, V. Provitiera, C. Crisci, Quantification of myelinated endings and mechanoreceptors in human digital skin, *Ann. Neurol.* 54 (2003) 197–205, <https://doi.org/10.1002/ana.10615>.
- [23] P.D. Creigh, M.P. McDermott, J.E. Sowden, M. Ferguson, D.N. Herrmann, In-vivo reflectance confocal microscopy of Meissner's corpuscles in diabetic distal symmetric polyneuropathy, *J. Neurol. Sci.* 378 (2017) 213–219, <https://doi.org/10.1016/j.jns.2017.05.025>.
- [24] Y. García-Mesa, J. Feito, M. González-Gay, I. Martínez, J. García-Piqueras, J. Martín-Cruces, E. Viña, T. Cobo, O. García-Suárez, Involvement of cutaneous sensory corpuscles in non-painful and painful diabetic neuropathy, *J. Clin. Med.* 10 (19) (2021) 4609, <https://doi.org/10.3390/jcm10194609>.
- [25] M.A. Saporta, I. Katona, R.A. Lewis, S. Masse, M.E. Shy, J. Li, Shortened internodal length of dermal myelinated nerve fibres in Charcot-Marie-Tooth disease typ. 1A, *Brain* 132 (2009) 3263–3273, <https://doi.org/10.1093/brain/awp274>.
- [26] J.L. Almodovar, M. Ferguson, M.P. McDermott, R.A. Lewis, M.E. Shy, D. N. Herrmann, In vivo confocal microscopy of Meissner corpuscles as a novel sensory measure in CMT1A, *J. Peripher. Nerv. Syst.* 16 (2011) 169–174, <https://doi.org/10.1111/j.1529-8027.2011.00342.x>.
- [27] F. Manganelli, M. Nolano, C. Pisciotta, V. Provitiera, G.M. Fabrizi, T. Cavallaro, A. Stancanelli, G. Caporaso, M.E. Shy, L. Santoro, Charcot-Marie-Tooth disease: new insights from skin biopsy, *Neurology* 85 (2015) 1202–1208, <https://doi.org/10.1212/WNL.0000000000001993>.
- [28] Hartmannsberger, B., Doppler, K., Stauber, J., Schlotter-Weigel, B., Young, P., Sereda, M.W., Sommer, C., 2109. Intraepidermal nerve fibre density as biomarker in Charcot-Marie-Tooth disease type 1A. *Brain Commun.* 2: fcaa012. <https://doi.org/10.1093/braincomms/fcaa012>.
- [29] J.L. Almodovar, G. Schifitto, M.P. McDermott, M. Ferguson, D.N. Herrmann, HIV neuropathy: an in vivo confocal microscopic study, *J. Neurovirol.* 18 (2012) 503–510, <https://doi.org/10.1007/s13365-012-0130-1>.
- [30] J. Márquez, M. Pérez-Pérez, F.J. Naves, J.A. Vega, Effect of spinal cord and peripheral nerve injury on human cutaneous sensory corpuscles. An immunohistochemical study, *J. Peripher. Nerv. Syst.* 2 (1997) 49–59.
- [31] A.B. Schmid, J.D. Bland, M.A. Bhat, D.L. Bennett, The relationship of nerve fibre pathology to sensory function in entrapment neuropathy, *Brain* 137 (2014) 3186–3199, <https://doi.org/10.1093/brain/awu288>.
- [32] V. Provitiera, M. Nolano, N. Pappone, C. di Girolamo, A. Stancanelli, F. Lullo, C. Crisci, L. Santoro, Distal degeneration of sensory and autonomic cutaneous nerve fibres in systemic sclerosis, *Ann. Rheum. Dis.* 64 (2005) 1524–1526, <https://doi.org/10.1136/ard.2005.038935>.
- [33] M. Nolano, V. Provitiera, A. Perretti, A. Stancanelli, A.M. Saltalamacchia, V. Donadio, F. Manganelli, B. Lanzillo, L. Santoro, Ross syndrome: a rare or a misdiagnosed disorder of thermoregulation? A skin innervation study on 12 subjects, *Brain* 129 (2006) 2119–2131, <https://doi.org/10.1093/brain/awl175>.
- [34] L. Santoro, F. Manganelli, R. Bruno, M. Nolano, V. Provitiera, F. Barbieri, Sural nerve and epidermal vascular abnormalities in a case of POEMS syndrome, *Eur. J. Neurol.* 13 (2006) 99–102, <https://doi.org/10.1111/j.1468-1331.2006.01117.x>.
- [35] B. Pan, K. Byrnes, M. Schwartz, C.D. Hansen, C.M. Campbell, M. Krupiczko, J. Caterina, M. Polydefkis, Peripheral neuropathic changes in pachyonychia congenita, *Pain* 157 (2016) 2843–2853, <https://doi.org/10.1097/j.pain.0000000000000711>.
- [36] M. Nolano, S. Tozza, G. Caporaso, V. Provitiera, Contribution of skin biopsy in peripheral neuropathies, *Brain Sci.* 10 (2020) 989, <https://doi.org/10.3390/brainsci10120989>.
- [37] M. Nolano, V. Provitiera, C. Crisci, A.M. Saltalamacchia, G. Wendelschafer-Crabb, W.R. Kennedy, A. Filla, L. Santoro, G. Caruso, Small fibers involvement in Friedreich's ataxia, *Ann. Neurol.* 50 (2001) 17–25, <https://doi.org/10.1002/ana.1283>.
- [38] M. Nolano, V. Provitiera, A. Estraneo, M.M. Selim, G. Caporaso, A. Stancanelli, A. M. Saltalamacchia, B. Lanzillo, L. Santoro, Sensory deficit in Parkinson's disease: evidence of a cutaneous denervation, *Brain* 131 (2008) 1903–1911, <https://doi.org/10.1093/brain/awn102>.
- [39] M. Nolano, V. Provitiera, F. Manganelli, R. Iodice, A. Stancanelli, G. Caporaso, A. Saltalamacchia, F. Califano, B. Lanzillo, M. Picillo, P. Barone, L. Santoro, Loss of cutaneous large and small fibers in naive and l-dopa-treated PD patients, *Neurology* 89 (2017) 776–784, <https://doi.org/10.1212/WNL.0000000000004274>.
- [40] F. Manganelli, V. Iodice, V. Provitiera, C. Pisciotta, M. Nolano, A. Perretti, L. Santoro, Small-fiber involvement in spinobulbar muscular atrophy (Kennedy's disease), *Muscle Nerve* 36 (2007) 816–820, <https://doi.org/10.1002/mus.20872>.
- [41] M. Ikemura, Y. Saito, R. Sengoku, Y. Sakiyama, H. Hatsuta, K. Kanemaru, M. Sawabe, T. Arai, G. Ito, T. Iwatsubo, M. Fukayama, S. Murayama, Lewy body pathology involves cutaneous nerves, *J. Neuropathol. Exp. Neurol.* 67 (2008) 945–953, <https://doi.org/10.1097/NEN.0b013e318186de48>.
- [42] Y. Ren, W. Liu, Y. Li, B. Sun, Y. Li, F. Yang, H. Wang, M. Li, F. Cui, X. Huang, Cutaneous somatic and autonomic nerve TDP-43 deposition in amyotrophic lateral sclerosis, *J. Neurol.* 265 (2018) 1753–1763, <https://doi.org/10.1007/s00415-018-8897-5>.
- [43] P.D. Creigh, J. Mountain, J.E. Sowden, K. Eichinger, B. Ravina, J. Larkindale, D. N. Herrmann, Measuring peripheral nerve involvement in Friedreich's ataxia, *Ann Clin Transl Neurol* 6 (2019) 1718–1727, <https://doi.org/10.1002/acn3.50865>.
- [44] F.J. Symons, G. Wendelschafer-Crabb, W. Kennedy, R. Hardrick, N. Dahl, J. W. Bodfish, Evidence of altered epidermal nerve fiber morphology in adults with self-injurious behaviour and neurodevelopmental disorders, *Pain* 134 (2008) 232–237, <https://doi.org/10.1016/j.pain.2007.07.022>.
- [45] S.W. Taylor, R.S. Laughlin, N. Kumar, B. Goodman, C.J. Klein, P.J. Dyck, P.J. B. Dyck, Clinical, physiological and pathological characterisation of the sensory predominant peripheral neuropathy in copper deficiency, *J. Neurol. Neurosurg. Psychiatry* 88 (2017) 839–845, <https://doi.org/10.1136/jnnp-2017-316304>.
- [46] W.R. Kennedy, M.M. Selim, T.S. Brink, J.S. Hodges, G. Wendelschafer-Crabb, S. X. Foster, M. Nolano, V. Provitiera, D.A. Simone, A new device to quantify tactile sensation in neuropathy, *Neurology* 76 (2011) 1642–1649, <https://doi.org/10.1212/WNL.0b013e318219fadd>.
- [47] J. Vider, A. Croaker, A.J. Cox, E. Raymond, R. Rogers, S. Adamson, M. Doyle, B. O'Brien, A.W. Cripps, N.P. West, Comparison of skin biopsy sample processing and storage methods on high dimensional immune gene expression using the Nanostring nCounter system, *Diagn. Pathol.* 15 (2020) 57, <https://doi.org/10.1186/s13000-020-00974-4>.