

Post-infectious acute myocardial infarction following COVID-19 infection in a young patient

Rodolfo Caminiti^{a,b}, Giampaolo Vetta^{a,c}, Antonio Parlavecchio^{a,b},
Michele Magnocavallo^c, Stefano Postorino^b, Scipione Carerj^a,
Francesco Antonio Benedetto^b

^a Cardiology Unit, Department of Clinical and Experimental Medicine, University of Messina, Messina, Italy

^b Interventional Cardiology Unit, Department of Cardiology, Grande Ospedale Metropolitano "Bianchi-Melacrino-Morelli", Reggio Calabria, Italy

^c Department of Clinical, Internal, Anesthesiology and Cardiovascular Sciences, Policlinico Universitario Umberto I, Sapienza University of Rome, Rome, Italy

ARTICLE INFO

Article history:

Submitted: 10. 4. 2022

Accepted: 2. 6. 2022

Available online: 20. 2. 2023

Klíčová slova:

Akutní infarkt myokardu

Covid-19

Kardiovaskulární onemocnění

Mladí pacienti

Keywords:

Acute myocardial infarction

Cardiovascular disease

COVID-19

Young patients

SOUHRN

Dnes je již dobře známo, že onemocnění covid-19 může mít i různé extrapulmonální projevy. Mezi možné mechanismy poškození kardiovaskulárního systému patří přímé poškození myokardu v důsledku hyperkoagulability vyvolané systémovým zánětem, což může vyústit i v destabilizaci plátů v koronárních tepnách.

Popisujeme případ 30letého mladého muže po asymptomatickém onemocnění covid-19, který byl přijat na oddělení akutních příjmů nemocnice Grande Ospedale Metropolitano di Reggio Calabria (Itálie) s typickou bolestí na hrudi. U pacienta nebyla stanovena diagnóza kardiovaskulárního onemocnění, nebyly přítomny žádné rizikové faktory, ani kardiovaskulární onemocnění v rodinné anamnéze.

Urgentní koronarografie prokázala kritickou (80%) stenózu ve střední a proximální části r. interventricularis anterior tvořenou plátem vzhledu ateromového vředu.

Naše kazuistika upozorňuje na nutnost – bez ohledu na rizikové faktory kardiovaskulárního onemocnění – ověřit přítomnost či nepřítomnost onemocnění covid-19 u všech pacientů s akutním infarktem myokardu během této pandemie.

© 2023, ČKS.

ABSTRACT

It is now widely known that COVID-19 can also cause various extrapulmonary manifestations. Possible mechanisms of cardiovascular damage include direct myocardial damage due to hypercoagulability caused by systemic inflammation, which may also lead to destabilisation of coronary plaques.

We present a case of a 30-year-old young man following asymptomatic COVID-19 infection, who was admitted to the emergency room of the Grande Ospedale Metropolitano di Reggio Calabria, Italy, with typical chest pain. The patient had no cardiovascular disease, cardiovascular risk factors including no family history of cardiovascular disease.

Urgent coronary angiography showed critical stenosis of the middle-proximal portion of the left anterior descending artery (80%) with ulcerated plaque appearance.

Regardless of cardiovascular risk factors, our case report emphasises the need to determine COVID-19 status in all patients with acute myocardial infarction during this pandemic.

Address: Rodolfo Caminiti, MD, Cardiology Unit, Department of Clinical and Experimental Medicine, University of Messina, Messina, Italy,

e-mail: rodolfocaminiti@msn.com

DOI: 10.33678/cor.2022.064

Introduction

Severe acute respiratory syndrome coronavirus 2 virus and associated coronavirus disease 2019 (COVID-19) was officially detected for the first time in Wuhan and has spread throughout the world becoming a pandemic. Although COVID-19 causes respiratory symptoms in most patients, several studies showed extrapulmonary involvement, including the cardiovascular system. Possible mechanisms of cardiovascular damage include direct myocardial damage from hemodynamic derives or hypoxemia, myocarditis, microvascular dysfunction, or thrombosis due to hypercoagulability due to systemic inflammation, which can also lead to destabilization of coronary plaques.¹ In literature, there is evidence of the link between COVID-19 and coagulation abnormalities and the predisposition of patients to thrombotic disease, in both the venous and arterial circulation.² At coronary angiography, patients with COVID-19 and myocardial infarction may show both typical obstructive coronary arteries and normal angiographic epicardial coronary arteries.³ We present a case of a 30-year-old young man following asymptomatic COVID-19 infection, who was admitted to the emergency room of the Grande Ospedale Metropolitano di Reggio Calabria, Italy, with typical chest pain.

Case report

A 30-year-old young man was admitted to the emergency department of the Grande Ospedale Metropolitano of Reggio Calabria, Italy, for typical chest pain.

The patient had no cardiovascular disease, cardiovascular risk factors including no family history of cardiovascular disease. He was infected with asymptomatic COVID-19 about 20 days previously. An antihygienic nasopharyngeal swab resulted negative 10 days before admission to the emergency department.

On admission, electrocardiogram showed hyperacute T waves on precordial leads V_2 – V_4 (Fig. 1A). Admission blood tests demonstrated increased level of high sensitivity (HS) cardiac I-troponin 1260 ng/L (normal <12 ng/L) with increase of creatine phosphokinase (231 U/L; normal <170 U/L) and creatine kinase MB levels (17 U/L; normal <16 U/L). The C-reactive protein was just above the maximum limit (5.57 mg/L; normal <5 mg/L). The echocardiogram showed akinesia of the whole apex with a reduced ejection fraction (42%). Urgent coronary angiography within 1 h from hospital admission revealed critical stenosis of the middle-proximal portion of the left anterior descending artery (80%) with ulcerated plaque appearance (Fig. 1B). The coronary

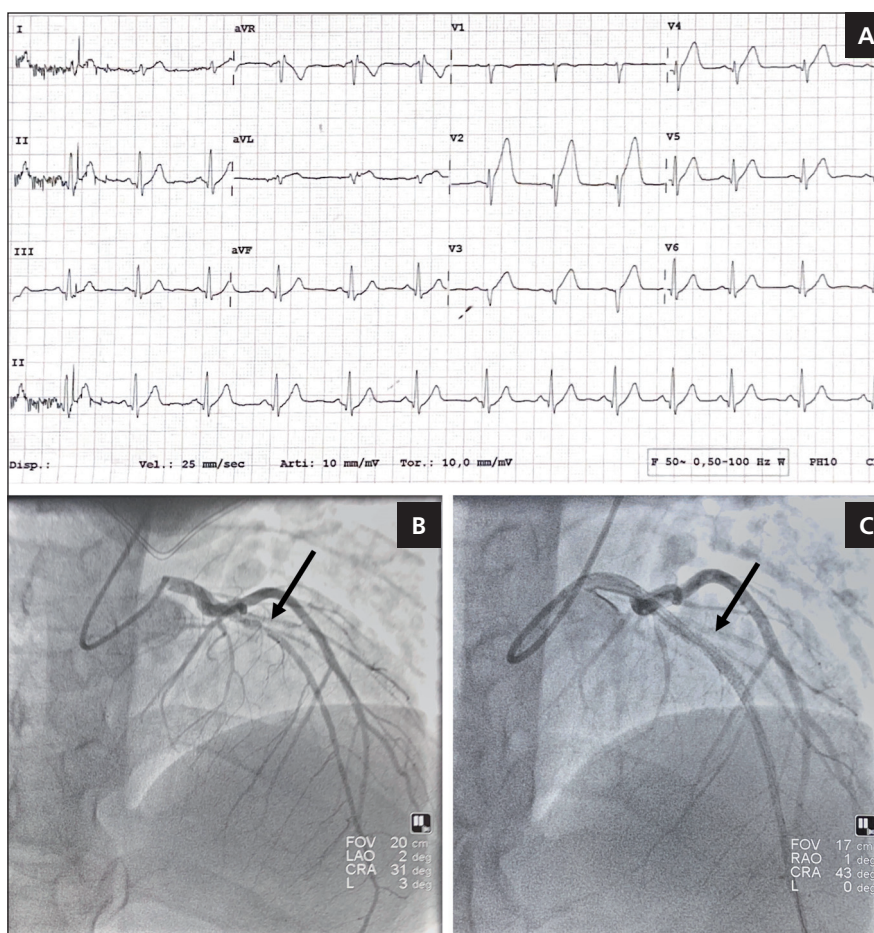


Fig. 1 – (A) Electrocardiogram at admission showing hyperacute T waves from V_2 – V_4 leads. (B) Baseline coronary angiogram showing severe stenosis of middle-proximal left descending coronary artery (black arrow). (C) Coronary angiogram after angioplasty (black arrow).

obstruction was successfully recanalized by the deployment of one Synergy everolimus-eluting stent 3.0 × 32 mm (Boston Scientific, Marlborough, MA, USA) (Fig. 1C). The patient was admitted to our Cardiology Intensive Care Unit.

The following day, laboratory tests showed HS I-troponin 25 260 ng/L, total cholesterol 190 mg/dL, HDL 29 mg/dL, LDL 85 mg/dL, Triglycerides 93 mg/dL. The patient was treated with acetylsalicylic acid, ticagrelor, high dose atorvastatin, sacubitril/valsartan and bisoprolol.

A new echocardiographic check before discharge showed a hypokinesia of the whole apex with an improvement of the ejection fraction (45%), normal right ventricular function, normal pulmonary systolic pressure and no valvular disease. The discharge electrocardiogram showed ST segment normalization.

Patient hospitalisation occurred without complications, with no evidence of arrhythmias on electrocardiographic monitoring.

The patient was discharged completely asymptomatic, after the markers of myocardial necrosis were negative.

Discussion

In our case report we describe a case of acute myocardial infarction in a young patient without cardiovascular risk factors following asymptomatic COVID-19 infection. To date, our case represents the youngest patient to suffer a type 1 acute myocardial infarction following an asymptomatic COVID-19 infection. In the case series by Sisakian and colleagues, STEMI patients with COVID-19 infection were young (33 and 35 years) without cardiovascular risk factors (one of the patients had a history of transient ischaemic attack) with onset of ventricular fibrillation.^{4,5} Instead, in the case-series by Bangalore and colleagues, patients with acute myocardial infarction and COVID-19 infection had different clinical as well as angiographic presentations.^{6,7} Indeed, the mean age of the patients was 63 years and most of them suffered from hypertension and diabetes mellitus. In addition, in 33% of patients at coronarography the coronary arteries were angiographically normal. In 37% of COVID-19 patients with acute myocardial infarction, there was no evidence of a culprit lesion on coronarography.^{3,8} These evidences suggest that several mechanisms are involved in the aetiology of acute myocardial infarction in COVID-19 patients, leading to an increased risk of myocardial infarction during COVID-19 infection, even in the absence of cardiovascular risk factors. Myocardial ischaemia in COVID-19 patients could be triggered by coronary dysfunction due to hyperinflammatory response.^{2,6} Cytokine release promotes T-cell and monocyte activation within an existing atherosclerotic plaque, destabilizing it through the release of histotoxic mediators leading to acute coronary syndrome. Moreover, the cytokines release, as interleukin-6, exerts proatherogenic effects, causing vascular smooth muscle proliferation, endothelial cell activation, and platelet activation.^{9,10}

Myocardial ischaemia can also be caused by microvascular dysfunction due to endothelial impairment.³

Endothelial dysfunction in COVID-19 patients is caused primarily by the downregulation of angiotensin-converting enzyme-2 (ACE-2) receptors, triggering the kallikrein-bradykinin system and resulting in increased vascular permeability. Virus-mediated vasculitis could be a further mechanism of microvascular dysfunction as the virus penetrates vascular endothelial cells via ACE-2 receptors, leading to inflammation and apoptosis. The multitude of pathways involved in the pathophysiology of myocardial infarction in COVID-19 infection results in a complex diagnostic and therapeutic management.^{7,10,11} Thus, the European Society of Cardiology developed Guidance for the Diagnosis and Management of Cardiovascular Disease during the COVID-19 Pandemic to guide the cardiologist's choices balancing the exposure of the health professional with the benefit to the patient.

Conclusion

COVID-19 infection by multiple pathophysiological mechanisms can lead to myocardial infarction even in young people without cardiovascular risk factors. Regardless of cardiovascular risk factors, our case report underlines the need to determine COVID-19 status in all patients with acute myocardial infarction during this pandemic. Further studies are needed to investigate the multiple mechanisms responsible for myocardial infarction in patients with COVID-19 infection and to assess optimal acute and long-term therapy.

Acknowledgements

None.

Conflict of interest

The authors declare that there is no conflict of interest.

Funding

The authors did not receive support from any organization for the submitted work.

Ethical approval

Ethical approval was waived by the local Ethics Committee of Grande Ospedale Metropolitano of Reggio Calabria in view of the retrospective nature of the study and all the procedures being performed were part of the routine care.

References

1. Stefanini GG, Montorfano M, Trabattoni D, et al. ST-Elevation Myocardial Infarction in Patients With COVID-19: Clinical and Angiographic Outcomes. *Circulation* 2020;141:2113–2116.
2. Huertas A, Montani D, Savale L, et al. Endothelial cell dysfunction: a major player in SARS-CoV-2 infection (COVID-19)? *Eur Respir J* 2020;56:2001634.
3. Musher DM, Abers MS, Corrales-Medina VF. Acute Infection and Myocardial Infarction. *N Engl J Med* 2019;380:171–176.
4. Sisakian H, Martirosyan S, Shekoyan S, et al. Asymptomatic COVID-19 and ST-elevation myocardial infarction in young adults: lessons learned from two similar cases. *ESC Heart Fail* 2022;9:775–781.

5. Caminiti R, Colarusso L, Vizzari G, Crea P. Tolerance of sustained ventricular fibrillation during left ventricular assist device support with IMPELLA CP®. *Cardiovasc Revasc Med* 2022;40S:305–307.
6. Bangalore S, Sharma A, Slotwiner A, et al. ST-Segment Elevation in Patients with Covid-19 – A Case Series. *N Engl J Med* 2020;382:2478–2480.
7. Afshar ZM, Babazadeh A, Javanian M, et al. A review of cardiac involvement in COVID-19 infection. *Cor Vasa* 2020;62:610–615.
8. Varvařovský I, Mates M, Bernat I, et al. Working in the cathlab during COVID-19 pandemic. *Cor Vasa* 2020;62(Suppl.1):34–36.
9. Casale M, Imbalzano E, Morabito C, et al. Early antithrombotic therapy and COVID-19: a better clinical course? New evidences from real-life cases. *Cor Vasa* 2020;62(Suppl.1):37–40.
10. Ferri C, Giuggioli D, Raimondo V, et al. Covid-19 and rheumatic autoimmune systemic diseases: Role of pre-existing lung involvement and ongoing treatments. *Curr Pharm Des.* 2021;27:4245–4252.
11. Skoda R, Fülöp G, Csulak E, et al. The secondary effect of the first wave of COVID-19 and its consequences on myocardial infarction care in a high volume Hungarian cardiovascular centre. *Cor Vasa* 2021;63:345–349.