

LUNGWORM DISEASE IN CATS

ABCD guidelines on prevention and management



Maria Grazia Pennisi, Katrin Hartmann, Diane D Addie, Corine Boucraut-Baralon, Herman Egberink, Tadeusz Frymus, Tim Gruffydd-Jones, Marian C Horzinek, Margaret J Hosie, Albert Lloret, Hans Lutz, Fulvio Marsilio, Alan D Radford, Etienne Thiry, Uwe Truyen and Karin Möstl

Overview: Cardiopulmonary nematodes are emerging parasites of cats in Europe. A number of helminth parasites may be involved. The most prevalent lungworm in domestic cats is *Aelurostrongylus abstrusus*. *Oslerus rostratus* and *Troglostrongylus* species are found mainly in wild cats. The trichurid *Capillaria aerophila* has a low host specificity and is not uncommon in cats. Additionally the lung flukes *Paragonimus* species are reported in many species outside of Europe, including cats.

Clinical signs: Lungworm infections may be asymptomatic, or cause mild to severe respiratory signs, dependent on the worm species and burden; mixed infections are observed. Kittens can be vertically infected and may develop a more severe disease. Affected cats show a productive cough, mucopurulent nasal discharge, tachypnoea, dyspnoea and, in severe cases, respiratory failure and death.

Management: Early diagnosis and treatment greatly improves the prognosis. First-stage larvae can be easily detected in fresh faecal samples; the Baermann migration method is the enrichment technique of choice, but takes 24 h. Lungworm larvae can be found in tracheal swabs and bronchoalveolar lavage fluid, but with less sensitivity than in faeces. Molecular methods have been developed that exhibit high specificity and sensitivity, and allow diagnosis in the prepatent phase. Treatment options include fenbendazole paste, milbemycin oxime/praziquantel and various spot-on formulations. Severe cases should receive prompt medical care in an intensive care unit.

Prevention: Avoiding predation is at present the only preventive measure for pulmonary worms with indirect life cycles.

Zoonotic risk: *C. aerophila* has zoonotic potential, causing severe pulmonary disease in humans. Some *Paragonimus* species are also of zoonotic concern.

Introduction

Cardiopulmonary nematodes are emerging parasites of cats and dogs in Europe and have received growing attention from researchers in recent years.^{1–4} Significant progress has been made, mainly in the diagnosis and treatment of infection.

Disease agents

Infection of the lower respiratory tract can be caused by a number of parasitic nematodes. Certain metastrongyloid worms are commonly defined as lungworms because the adult stage is located in the lungs of their hosts, but actually some trichurids and flukes also live in the respiratory system.^{1–3,5} *Aelurostrongylus abstrusus* (*Strongylida*, *Angiostrongylidae*) is the most well known feline lungworm and is regarded as the most prevalent in domestic cats. It is small (5–10 mm) and very narrow (less than 100 µm) and capable of colonising the respiratory bronchioles and alveolar ducts of domestic cats and other felids worldwide.^{2,6} Other respiratory mollusc-borne metastrongylids are commonly reported at necropsy in wild felids but are considered very rare in domestic cats. *Oslerus rostratus* (*Strongylida*, *Filaroididae*) exceeds 30–40 mm in length and infects the bronchial submucosa mainly in wild cats such as bobcats or in feral cats.^{5,7–10} *Troglostrongylus* species (*Strongylida*, *Crenosomatidae*) is reported in a wide variety of wild cats and occasionally in domestic cats,^{4,9,11–14} these worms vary in length, according to the species, from about 10–25 mm and are up to 0.5 mm in width. They are located in the trachea and bronchi or even the bronchioles for the smallest species (*T. brevior*).^{12,15}

The trichurid *Capillaria aerophila* (syn *Eucoleus aerophilus*) has a low host specificity and is not uncommon in cats and dogs as well as wild carnivores.¹⁶ It is also a zoonotic parasite, causing a potentially severe pulmonary disease in humans.¹⁷ *C. aerophila* is found in the submucosa of the trachea, bronchi and bronchioles.^{2,16}

Mixed infections by respiratory nematodes are sometimes reported^{7,9,14,18–20} and both *Troglostrongylus* species and *O. rostratus* may be more prevalent than presumed in domestic cats since there is a risk



European Advisory Board
on Cat Diseases
www.abccatsvets.org
www.abcd-vets.org

Corresponding author: Maria Grazia Pennisi
Email: mariagrazia.pennisi@unime.it



that these infections are being misdiagnosed as *A abstrusus* because of morphometric similarities of their first-stage larvae (L1) in faeces.^{3,4}

Paragonimus species are lung flukes reported in many animals, including cats and humans, and some species are of zoonotic concern. Many species are found in cats, including *P kellicotti*, and between one and 10 adults measuring 8–18 mm x 4–8 mm live in subpleural cysts or bullae.¹

Life cycle and transmission

A abstrusus, *O rostratus* and *Troglostrongylus* species all have an indirect life cycle involving terrestrial molluscs. Eggs of *A abstrusus* laid by female worms hatch in the respiratory tract and L1 larvae are coughed up, swallowed and eliminated in the environment with the faeces. They can actively enter slugs or snails where they moult into the infectious L3 stage.^{21–24} The biological cycle in the intermediate host is influenced by environmental temperature: a higher rate of larval development is observed at warmer temperatures.²³ The L3 larvae are also found in a wide range of paratenic hosts (rat, mouse, lizard, frog, bird) commonly predated by cats.^{1,5,22} The ingestion of L3 larvae by the cat is the best recognised means of transmission of lungworms, but vertical transmission via the placenta or milk cannot be excluded, as adult egg-laying worms have been found in kittens as young as 8 weeks of age.¹⁴ Experimentally, it has been demonstrated that egg production starts 4–6 weeks after infection and may last for months, although it can be irregular.^{6,25–28}

Vertical transmission of *T brevior* was recently observed in a queen and patent infection was detected in 1-month-old kittens.^{13,14,29} *T brevior* and *A abstrusus* larvae may develop simultaneously in the same mollusc host (*Helix aspersa*) and overwinter for at least 120 days.²⁴ Very recently environmental contamination has been suggested as an alternative means of transmission for both *A abstrusus* and *T brevior* L1 on the basis of an experimental study;³⁰ live larvae were found in the pedal mucus excreted by *H aspersa* and in the water where the snails died.

C aerophila has a direct life cycle and eggs laid by female worms in the respiratory tract are swallowed and reach the environment in the faeces. After 30–45 days, embryonated eggs become infective when ingested by cats. Earthworms are facultative paratenic hosts.¹⁶ When cats ingest infective eggs or earthworms carrying larvae, the larvae migrate to the lung and develop into the adult stage in 3–6 weeks.³¹

The life cycle of *Paragonimus* species is asso-

European Advisory Board on Cat Diseases
The European Advisory Board on Cat Diseases (ABCD) is a body of experts in immunology, vaccinology and clinical feline medicine that issues guidelines on prevention and management of feline infectious diseases in Europe, for the benefit of the health and welfare of cats. The guidelines are based on current scientific knowledge of the diseases and available vaccines concerned.

The latest version of the lungworm disease in cats guidelines is available at www.abcdcatsvets.org and www.abcd-vets.org



Difficulties with morphometric differentiation of L1 larvae have meant that many cases of (co)infection by other metastrongylids may have been erroneously attributed to the better-known *A abstrusus* lungworm.

ciated with freshwater environments and is complex as it involves two intermediate hosts. Motile miracidia are released from eggs when swallowed and then passed in faeces from infected cats and penetrate aquatic snails; cercarial stages developed in snails will move from them, actively entering the second intermediate host (crab or crayfish). Cats are infected after eating the second intermediate host where metacercariae finally develop. Young flukes develop from metacercariae in the cat intestine, and cross the intestinal wall and the diaphragm to the pleural cavity where they penetrate the lung parenchyma and become reproducing adults in about 6 weeks.¹

Epidemiology

Feline lungworm infection is receiving increasing attention.^{2,6} *A abstrusus* is a well recognised agent of lower respiratory tract disease in cats.^{1,2} Epidemiological studies and case reports have confirmed the presence of the parasite in the Americas, Europe, Asia and Australia.^{1,14,32–40} Prevalence rates vary and endemicity is linked to climatic and ecological factors that may influence: (a) the vitality and developmental capacity of L1; (b) the presence of suitable intermediate hosts in the environment; and (c) the number of days needed for development of the infective stage (L3). The diagnostic method used in epidemiological studies and the characteristics of the population investigated heavily influence the results.^{2,37,41,42} Feral and free-roaming cats are at higher risk because of their predator activity, as are cats with respiratory signs and young cats.^{43,44} In Tirana (Albania), post-mortem examination of the lungs of 18 feral cats revealed that nine (50%) were positive for *A abstrusus*.⁴⁵ Use of a low-sensitivity diagnostic method, such as the standard faecal flotation technique, showed a prevalence rate of 1–25% in a general cat population (see Table 1).^{14,46–49}

O rostratus is considered an uncommon parasite in domestic cats, but the prevalence in feral cats was found to be 24% in Majorca (Spain). It was also reported in a cat in northern Spain.^{7,8} Very recently, the incidental occurrence of a few adult *O rostratus* worms was reported in Sicily (Italy) at the necropsy of an adult cat that had died following a road traffic accident.¹⁰

C aerophila has a sporadic occurrence in cats, dogs and humans in Europe. In central Italy, a prevalence of 3–14% was found in the feline population.^{2,16,36}

Single cases of *Troglostrongylus* species infection were recently reported in cats from Ibiza (Spain), central and southern Italy and Crete (Greece).^{9,12,13,15,19,20,29,50} The first epidemiologi-

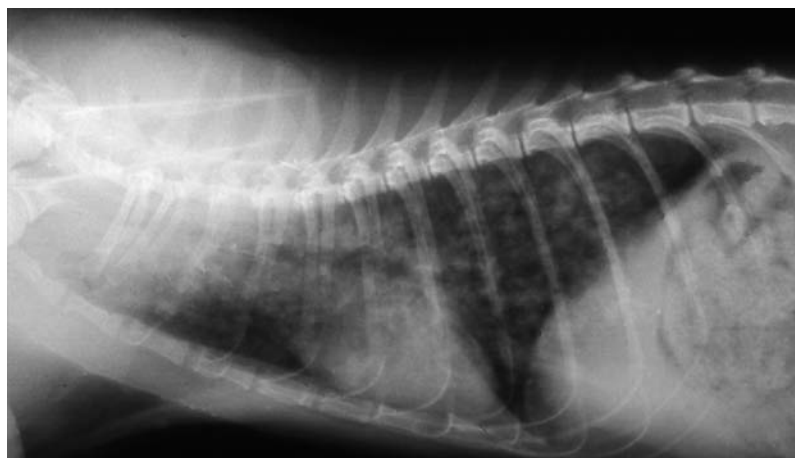

Figure 1 Right lateral thoracic radiograph of a kitten with severe aelurostrongylosis, showing a diffuse focal alveolar pattern. Courtesy of Maria Grazia Pennisi, Department of Veterinary Sciences, University of Messina, Italy

cal data on *T brevior* in domestic cats were recently provided in Sardinia (Italy) where 6.5% of a sample of 107 cats tested positive compared with 25.2% that tested positive for *A abstrusus*,¹⁴ confirming that *Troglostrongylus* is not a negligible lungworm of domestic cats.

The recent development of molecular assays specific for mollusc-borne feline lungworms sharing the same ecological niches, as well as for *C aerophila*, is likely to be of great value for epidemiological investigations, overcoming the difficulties of copromicroscopy for differentiating the metastrongylid L1 larvae.^{3,9,50–52}

Paragonimus species infections are reported in cats from the Americas, Africa and Asia.^{1,53,54} Paragonimiasis is most prevalent in cats and dogs in some parts of Asia.⁵⁵

Prevalence rates and/or documented cases of *A abstrusus*, *C aerophila*, *O rostratus* and *Troglostrongylus* species in some European countries are shown in Table 1.

Pathogenesis

The severity of lesions depends on the worm species and burden. Kittens also seem to develop a more severe disease.^{18,26,27,67} This may be explained by the smaller lung volume and small diameter of the trachea and bronchi, which are more easily blocked by worms, in particular by the larger *Troglostrongylus* species. The immature immune system also seems to facilitate infection: experimental reinfection of kittens with *A abstrusus* L3 larvae about 1 year after the initial symptomatic infection failed to induce respiratory signs or lung lesions.²⁵ In cats with natural aelurostrongylosis, the more severe

radiological abnormalities and the higher larval burdens were found in younger animals (Figure 1).⁶⁸

An infective dose of <100 L3 *A abstrusus* larvae does not induce clinical signs but infective doses of 800–3200 larvae severely affect the lung and may even be lethal.^{69,70} However, at normal infective doses, the individual immune response significantly disrupts the parasite life cycle.²⁸ Cats repeatedly infected with a low number of larvae do not develop clinical disease when challenged with a high dose.⁷¹

The role of immunity is confirmed also by the protective effect of passive immunisation in experimentally infected kittens. In some cases it can halt the parasite life cycle and the patent phase of infection does not occur.^{28,72}

It has been recognised for a long time that eosinophilia is evident 2–6 weeks after the ingestion of L3 larvae of *A abstrusus* and that immune-mediated reactions of types I, III and IV are associated with alveolar, interstitial, peribronchial and vascular lesions and may lead to the death of parasites several months later.^{1,73} A more recent experimental study provides

more detailed information on the clinical signs, haematology, biochemistry, coagulation analysis, computed tomography, coprology and post-mortem findings in young adult cats.^{28,70} Infected cats had moderate, non-specific clinical signs (fever, lethargy, weight loss, lymph node enlargement) and respiratory signs (dyspnoea, respiratory sounds, cough). Leucocytosis, massive and persistent eosinophilia and, in some cases, severe lymphocytosis were the most frequently observed abnormalities but no changes were

detected on serum biochemistry. Various coagulation abnormalities were found, with a

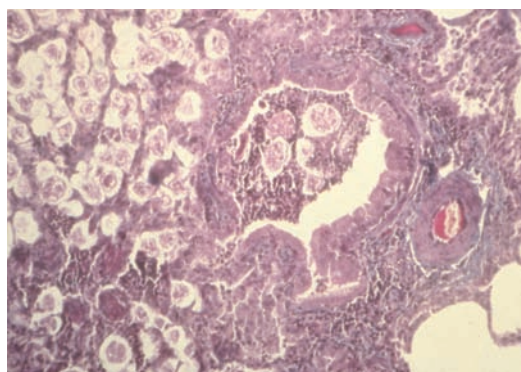


Figure 2 Alveolitis with larval accumulation, bronchiolitis and bronchiectasis in the lung of a cat with aelurostrongylosis (haematoxylin and eosin stain). Courtesy of Maria Grazia Pennisi, Department of Veterinary Sciences, University of Messina, Italy

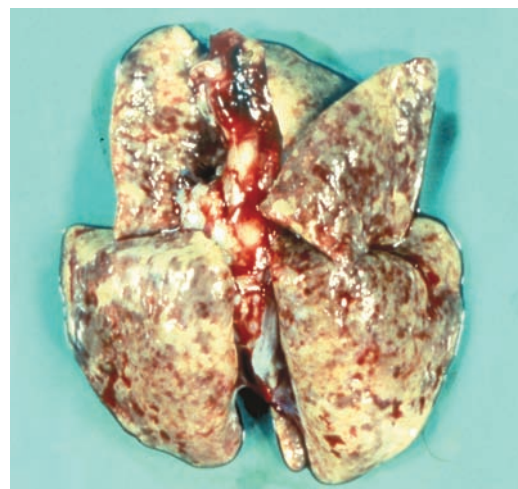


Figure 3 Multifocal subpleural nodules and haemorrhages in a severe case of aelurostrongylosis. Courtesy of Maria Grazia Pennisi, Department of Veterinary Sciences, University of Messina, Italy

Table 1 Prevalence rate (%) and documented cases of *A abstrusus*, *C aerophila*, *O rostratus* and *Troglostrongylus* species infection in various European countries. Case reports of *A abstrusus* respiratory disease exist also from the UK, Ireland, France, Switzerland, Belgium, Denmark, Poland and Greece^{2,6}

Country	References	<i>A abstrusus</i>	<i>O rostratus</i>	<i>Troglostrongylus</i> species	<i>C aerophila</i>
Italy	Brianti et al (2008) ⁴⁷ Traversa et al (2008) ⁴² Iorio and Traversa (2008) ⁴³ Mugnaini et al (2012) ⁵⁶ Riggio et al (2013) ⁵⁷ Spada et al (2013) ⁵⁸ Brianti et al (2014) ¹⁰ Tamponi et al (2014) ¹⁴ Giannelli et al (2014) ¹⁵ Varcasia et al (2015) ²⁰	1.2–25.2% (CR)	(CR)	6.5% (CR)	1.2–14.3% (CR)
Spain	Miró et al (2004) ⁴⁶ Jefferies et al (2010) ⁹	1% (CR)	24% (CR)	(CR)	1.3%
Greece	Diakou et al (2014) ²⁹	–	–	(CR)	–
Portugal	Payo-Puente et al (2008) ⁵⁹	17.4%	–	–	0.3–0.6%
Netherlands	Robben et al (2004) ⁶⁰	2.6% (CR)	–	–	–
Germany	Taubert et al (2009) ⁶¹ Becker et al (2012) ⁶² Barutzki and Schaper (2013) ⁴⁴	0.7–6.5% (CR)	–	–	0.2%
Croatia	Grabarević et al (1999) ⁶³	22%	–	–	–
Albania	Knaus et al (2011) ⁴⁵	50%	–	–	–
Romania	Mircean et al (2010) ⁴⁸	5.6%	–	–	3.1%
Hungary	András and Péter (2002) ⁶⁴ Capari et al (2013) ⁶⁵	14.5% (CR)	–	–	3.8%
Bulgaria	Stoichev et al (1982) ⁶⁶	33.3%	–	–	–

CR = case report

frequent occurrence of low fibrinogen values suggesting an increased consumption of coagulation factors. Imaging changes in the thorax were related to the dose and consisted of pulmonary nodules, bronchial pattern and lymphadenomegaly and were found even in a cat that did not develop a patent infection.⁷⁰

A abstrusus eggs accumulate in alveoli and bronchioles, inducing an inflammatory reaction in the lung (Figure 2). Multiple subpleural nodules (Figure 3) are caused by the granulomatous reaction surrounding clusters of eggs and adult worms, and emphysema is due to parasitic accumulation in the alveolar spaces. Bronchitis is severe and diffuse, usually manifested by bronchial and peribronchial lymphoid hyperplasia, hypertrophy of the smooth muscle layer and mucosal hyperplasia with increased mucous cell secretion in the bronchi. Vascular and perivascular changes are also seen, with hypertrophy and hyperplasia of pulmonary arteriolar smooth muscle, subendothelial fibrosis associated with eosinophilic infiltrates, endothelial and perivascular hyperplasia. Pulmonary hypertension may be the consequence of lung dis-

Kittens appear to develop more severe lungworm disease.



ease and arteriolar and bronchial changes may persist after the parasite dies, mimicking the changes found in feline asthma.^{27,73–75} Bacterial complication is frequent and can be associated with pleural effusion.²⁶ *Salmonella typhimurium*, *Pseudomonas* species and *Escherichia coli* have been isolated in some cases and infection with enteric bacteria probably results from larvae migrating from the intestine.^{54,76}

In a kitten with severe pulmonary aelurostrongylosis, enteritis and mild diarrhoea were associated with the presence of a high number of L1 larvae invading the small intestinal mucosa.⁴⁰

Lethal *T brevior* infection was associated in three kittens with catarrhal bronchitis occluding the lumen together with the adult worms, and multifocal pulmonary haemorrhages, consolidation and emphysematous foci.^{12,15}

O rostratus does not seem to be associated with severe pathological changes in domestic cats, as few adult worms are found embedded in bronchial or peribronchial tissues inside pseudocysts.^{7,10} *C aerophila* usually induces chronic bronchitis.^{16,77}

The penetration of *Paragonimus* species in the lung is associated with haemorrhagic foci, usually in the diaphragmatic lobe. Fluke cysts enter the bronchi and may evolve into bullae, with a consequent risk of pneumothorax.

Clinical signs

Although the majority of the publications in the literature concern *A abstrusus*, it has been suggested that many cases of infection or co-infection by other metastrongylids may have been erroneously attributed to the better-known *A abstrusus* because of difficulties with the morphometric differentiation of L1 larvae.^{3,4,9} Genetic characterisation of larvae now offers new insights and is likely to permit more accurate diagnosis.

Lungworm infections may be asymptomatic, or cause mild to severe respiratory signs due to bronchopneumonia, sometimes complicated by pleural effusion or pneumothorax.^{26,67,78,79} A productive cough is, therefore, the main clinical sign, together with mucopurulent nasal discharge, tachypnoea, dyspnoea with laboured, abdominal breathing and end-inspiratory crackles upon auscultation. In more severe cases, respiratory failure causes cyanotic mucosae and respiratory acidosis.^{9,18,27,42,80}

Diagnostic imaging (eg, thoracic radiography or computed tomography) reveals bronchial thickening and poorly defined, small nodules during the patent phase. These findings may persist after clearing the infection and should be differentiated from other chronic bronchial disease such as asthma.^{59,81} Imaging changes may be evident even before the patent phase of disease.^{28,70}

Mixed lungworm infections are increasingly reported but they do not necessarily have a more severe clinical picture or poorer outcome.



Right-sided cardiomegaly associated with eccentric hypertrophy and secondary to pulmonary hypertension has been described in two kittens affected by a severe bronchopneumonia caused by *A abstrusus*.²⁷ Both kittens presented with heart murmurs with maximum intensity on the right hemithorax due to tricuspid and pulmonary regurgitation. One of the kittens died but, in the surviving kitten, the heart murmur disappeared several months after parasitological and clinical cure. Echo-Doppler examination confirmed the resolution of pulmonary hypertension.²⁷ It is, therefore, advisable to investigate for the presence of lungworm infection in cases of right heart disease associated with signs of pulmonary hypertension in outdoor cats. In a study of 54 cats that died during anaesthesia in spay-neutering programs in the USA, 9% of post-mortem investigations revealed the presence of *A abstrusus*.⁸² Stray outdoor cats, such as those included in trap-neuter-release programs, are at higher risk of lungworm infection.

Eosinophilia is a frequent abnormality but is not found consistently in cell blood counts or in bronchoalveolar lavage (BAL) cytology.^{18,67,76,83}

Troglostrongylus species was considered the cause of death of parasitised kittens presenting with a cough and severe respiratory failure at diagnosis, but cases of asymptomatic infection have also been reported.^{12,13,15,19,84}

Capillaria infection may induce coughing (mostly dry cough), sneezing and wheezing in cats but asymptomatic carriers have also been reported.^{16,85}

Mixed infections are increasingly reported but they do not necessarily have a more severe clinical picture or poorer outcome.^{19,84,85}

Baermann method

The Baermann method separates live larvae from a faecal sample as they are attracted by humidity (hydrotropism). It can be performed using an in-house system (Figure 4).

- ❖ Fill a large (60 ml) syringe with tap water
- ❖ Connect the cone of the syringe to a rubber tube, which is clamped at the end
- ❖ Orientate the syringe vertically
- ❖ Fill a cheesecloth pouch with approximately 5–10 g of faeces
- ❖ Clamp the pouch and dip it in the water-filled syringe
- ❖ After 24 h any live larvae will have passed into the water and sedimented at the bottom of the system
- ❖ Collect a few millilitres of the water in a tube and centrifuge (400 g x 2 mins). Discharge the supernatant and put one drop of the sediment fluid on a microscope slide. Cover with a coverslip and examine under a microscope at x 100 magnification

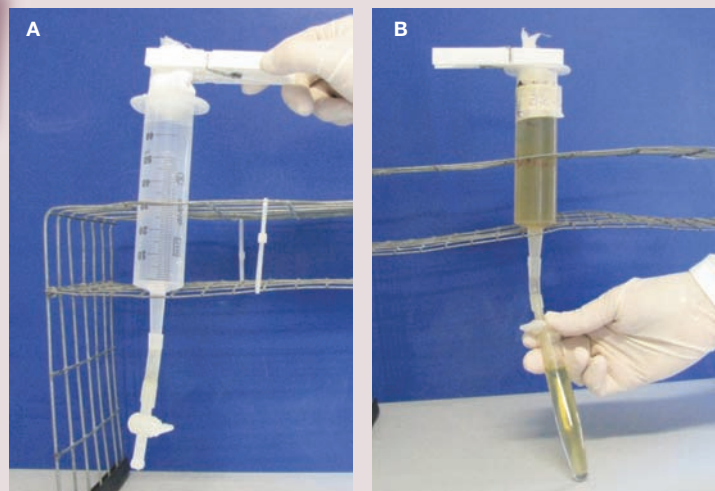


Figure 4 (A,B) Baermann apparatus. Courtesy of Emanuele Brianti, Department of Veterinary Sciences, University of Messina, Italy

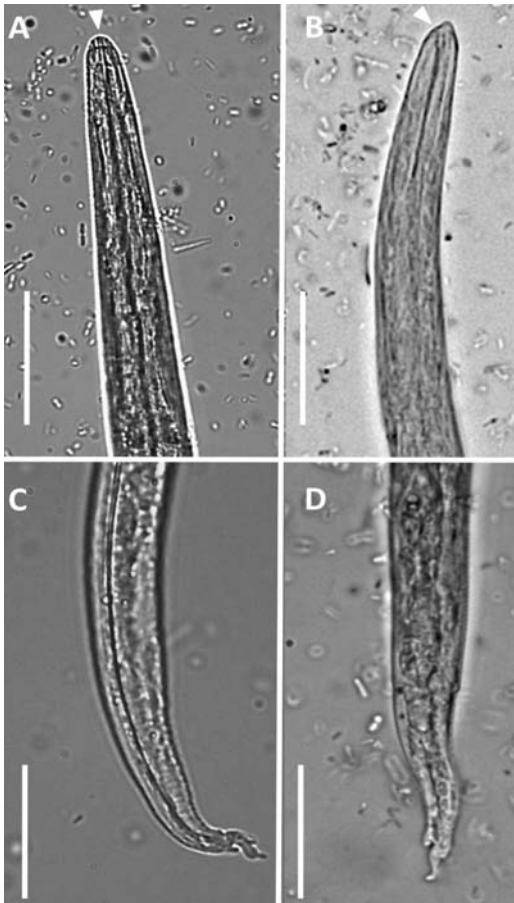


Figure 5 First-stage (L1) larvae of *Aelurostrongylus abstrusus* (A and C) and *Troglostrostrongylus brevior* (B and D) viewed by light microscopy (scale bars = 25 μ m). (A) Anterior extremity of *A. abstrusus*, lateral view. Note the terminal oral opening (arrowhead). (B) Anterior extremity of *T. brevior*, lateral view. Note the pointed head and the subterminal oral opening (arrowhead). Morphology of the tail of *A. abstrusus* (C) and *T. brevior* (D) showing a dorsal spine at the end of the tail. Courtesy of Emanuele Brianti, Department of Veterinary Sciences, University of Messina, Italy

Diagnosis

L1 larvae are very active in the faeces and are readily detected in fresh faecal samples. Care should be taken to prevent soil contamination of samples, as the presence of free-living nematodes may lead to misdiagnosis. L1 larvae can be observed in direct faecal smears or by the flotation technique. Note that, in the latter method, high specific gravity concentrated salt or sugar solutions may induce osmotic damage to the larvae, making identification difficult.¹ The Baermann migration method is considered the enrichment technique of choice for metastrongyloid lungworms, and is based on the positive hydrotropism observed in live nematode larvae (see box and Figure 4, page 630).^{41,42,86} It can provide quantitative information on the number of larvae found in each gram of faeces, which correlates well with the severity of disease.^{47,68} Unfortunately, 24 h are necessary to obtain the result

and the test should be repeated three times in the event of negative results, for optimum sensitivity.

A newer parasitological device for multi-valent quantitative estimation of eggs, larvae and oocysts, named FLOTAC, was evaluated for suitability in the diagnosis of *A. abstrusus* infection. The authors reported that it was more sensitive than the Baermann method.⁸⁷ However, the major limitation of copromicroscopy in general is the impossibility of making a diagnosis in the prepatent period, which lasts about 1–2 months, or when egg shedding has stopped but parasites persist and clinical signs are manifest. A well-trained observer is required to distinguish between the different strongyloid L1 forms on the basis of their morphometric and morphological characteristics (Figures 5 and 6).^{3,12}

Lungworm larvae can be found in tracheal swabs or wash and BAL cytology but with less sensitivity than in faeces, so there is no benefit in using these more invasive procedures that risk severe respiratory disease.⁴¹ Antibodies to *A. abstrusus* can be detected as early as 3 weeks postinfection using an immunofluorescence antibody test, but past and currently active infections cannot be differentiated by serology.⁸⁸

Significant progress has been made diagnostically with the advent of molecular methods. A nested-PCR assay specific for *A. abstrusus* has been validated on different

biological samples (faeces, flotation supernatant, Baermann sediment and pharyngeal swabs) collected from cats with natural infections. A specificity of 100% and a sensitivity of up to 96.6% were recorded and the best results were obtained using pharyngeal swabs.⁵¹ This method allows early diagnosis in the prepatent phase, with a potential positive impact on prognosis. Molecular techniques are expected to significantly improve the understanding of lungworm infections. A new multiplex PCR has also been developed for the simultaneous detection of *A. abstrusus* and *T. brevior*.⁵⁰

Capillariosis is diagnosed by standard faecal flotation but molecular techniques are also available for screening and for human cases.^{2,52}

Paragonimiasis is diagnosed using a formalin-ether sedimentation technique.⁵³ Molecular methods are available for epidemiological purposes in cats and are used for human cases.^{89,90}

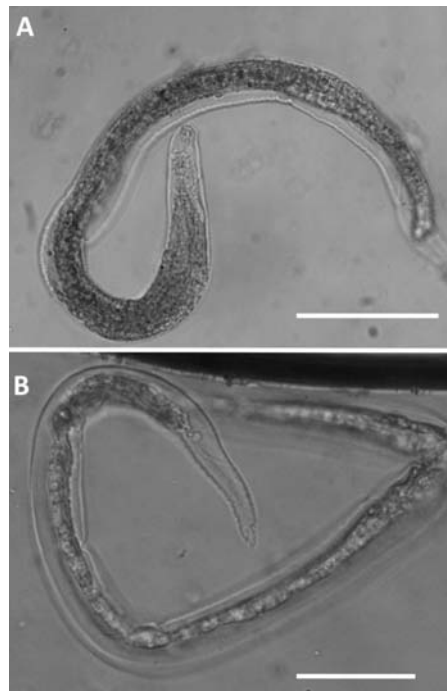


Figure 6 First-stage (L1) larvae of *Oslerus rostratus* viewed by light microscopy (scale bars = 100 μ m). Note the morphology of the cephalic (A) and caudal (B) regions. Courtesy of Emanuele Brianti, Department of Veterinary Sciences, University of Messina, Italy

EBM grades

The ranking system for grading the level of evidence of various statements within the treatment and prevention sections of this article is described on page 574 of this Special Issue.

Table 2 Drugs used for the treatment of pulmonary nematode infections in cats

Drug	Formulation	Dosage	Efficacy
Fenbendazole	Oral paste	50 mg/kg q24h for 3 days	<i>A abstrusus</i> (CS)
Imidacloprid 10% + moxidectin 1%	Spot on	Licensed dosage 1 administration for <i>C aerophila</i> and <i>A abstrusus</i> (CS) 1–3 administrations for <i>A abstrusus</i> (CR)	<i>A abstrusus</i> (CS, CR) <i>C aerophila</i> (CS)
Emodepside 2.1% + praziquantel 8.6%	Spot on	Licensed dosage Repeated after 15 days (CR)	<i>A abstrusus</i> (CS, CR) <i>T brevior</i> (CR) <i>C aerophila</i> (CR)
Fipronil 8.3% + (S)-methoprene 10% + eprinomectin 0.4% + praziquantel 8.3%	Spot on	Licensed dosage	<i>A abstrusus</i> (EI, CR) <i>T brevior</i> (CR)
Milbemycin oxime (4 mg) + praziquantel (10 mg)	Tablet	1 tablet/2 kg every 15 days for three doses	<i>A abstrusus</i> (CR)
Selamectin	Spot on	Licensed dosage for two to three doses	<i>A abstrusus</i> (CR)

CS = controlled study, CR = case report, EI = experimental infection

Treatment

Information on the efficacy of various drugs in the treatment of feline lungworm infection is available from controlled studies and clinical case reports (Table 2). Oral administration of fenbendazole has been suggested, with different doses and durations of therapy (from 20 mg/kg for 5 days to 50 mg/kg for 15 days), but an oral paste is licensed in the UK for treating aelurostrongylosis in cats at 50 mg/kg q24h for 3 days [EBM grade III].²

Off-label use of ivermectin has been reported, with inconclusive results, and should not be considered because of the risk of toxicity, principally in kittens [EBM grade III].⁶⁷

Two spot-on formulations administered at the recommended dosage were compared with a 3 day course of fenbendazole therapy and were found to be effective and safe in the treatment of 12 naturally infected cats each: one formulation contained imidacloprid 10% and moxidectin 1% (Advocate; Bayer), the other emodepside 2.1% and praziquantel 8.6% (Profender; Bayer) [EBM grade I].^{91,92} The moxidectin formulation proved the most efficacious of the three protocols, with 100% efficacy after 30 days [EBM grade I].⁹² In an additional controlled study, the imidacloprid 10% and moxidectin 1% spot-on formulation was significantly effective also against *C aerophila* infection [EBM grade I].⁸⁵ A new spot-on combination of fipronil 8.3%, (S)-methoprene 10%, eprinomectin 0.4% and praziquantel 8.3% (Broadline; Merial) was evaluated under experimental conditions and found to be highly effective for both the prevention and treatment of *A abstrusus* infection

Bacterial secondary infections may contribute to the severity of lungworm disease and require broad-spectrum antibiotic and corticosteroid therapy.



[EBM grade II].⁹³ Very recently the same product was found effective for treating cats with natural disease caused by *A abstrusus* (18 cats), as well as *T brevior* (three cats) or both lungworms (two cats) [EBM grade III].⁹⁴

In a case series study, cats with natural infection treated with the combination of imidacloprid 10% and moxidectin 1% were rechecked at day 14, and those still found positive (4/7) were retreated and checked 1 week later. At that stage, one cat remained positive and was treated for a third time. At the end of the study (day 50), two negative faecal tests had been obtained for all treated cats, confirming the efficacy of the treatment with this combination [EBM grade III].⁴⁷

A combination of milbemycin oxime (4 mg) and praziquantel (10 mg) (Milbemax; Novartis) was administered as a single oral dose (half a tablet per kg) three times, 15 days apart, to a kitten with *A abstrusus* bronchopneumonia and pulmonary hypertension, achieving parasitological and clinical cure [EBM grade IV].²⁷ Efficacy of standard topical administration of a selamectin spot-on formulation (6 mg/kg) (Stronghold; Zoetis) was reported in a case report and in two case series.^{67,83,95} In one case series, selamectin was effective in one of four cats at day 30 and in two of the three cats retreated and followed up at day 60 [EBM grade III].⁶⁷ In the second case series, treatment was effective in nine of 10 cats [EBM grade III].⁹⁵ Capillariasis was successfully treated in a cat with two injections of abamectin (14 days apart) at a dose of 0.3 mg/kg [EBM grade IV].⁹⁶

Information on the treatment of *Troglostrongylus*, as well as on mixed infections, is

derived from case reports only. Cases of severe respiratory disease associated with *Troglostrongylus* infection were not cured by imidacloprid 10% and moxidectin 1% or febendazole treatment [EBM grade IV].¹² A combination of milbemycin oxime (4 mg) and praziquantel (10 mg) was administered as a single oral dose (half a tablet per kg) in two kittens with mixed infections caused by *A abstrusus* and *T brevior*. The asymptomatic kitten was cured but the sibling with severe respiratory disease died 2 days later [EBM grade IV].¹⁹ Mixed *T brevior*/*A abstrusus* and *T brevior*/*C aerophila* infections were cured in two kittens using the emodepside 2.1% and praziquantel 8.6% spot-on combination; in one case, two administrations were required to clear *Troglostrongylus* larval shedding [EBM grade IV].⁸⁴

Bacterial secondary infections may contribute to the severity of lungworm disease and broad-spectrum antibiotics should always be given together with corticosteroids at anti-inflammatory doses in cases with signs of bronchopneumonia. Pleural effusion and pneumothorax require immediate resolution by thoracocentesis, and medical care in an intensive care unit (oxygen administration) is required for all cats with respiratory failure.

Molecular techniques are expected to significantly improve the understanding of feline lungworm infections.



Prognosis

In cases of *A abstrusus* infection, a delay in diagnosis and treatment may lead to fatal cardiopulmonary lesions, while early diagnosis and treatment greatly improves the prognosis. The level of larval burden determined by the Baermann test is usually related to the severity of the disease but the prognosis should be based mainly on physical examination (severity of dyspnoea and occurrence of cyanosis) and radiographic findings (severity of diffuse bronchial, alveolar and interstitial disease).

Prevention

Stray and free-roaming cats have a higher risk of becoming infected with lungworms in endemic areas.⁴³ Avoiding predation is at present the only preventive measure for metastrongyloid or trematode pulmonary

KEY POINTS

- ❖ *Aelurostrongylus abstrusus* (*Strongylida*, *Angiostrongylidae*) is the most well known feline lungworm and is regarded as the most prevalent worldwide in domestic cats.
- ❖ Other lungworms in the cat include *Oslerus rostratus*, *Troglostrongylus* species, *Capillaria aerophila* and *Paragonimus* species.
- ❖ *A abstrusus*, *O rostratus* and *Troglostrongylus* species may cause mixed infections as they share the same intermediate and paratenic hosts.
- ❖ Lungworm infections may be asymptomatic, or cause mild to severe respiratory signs due to bronchopneumonia, sometimes complicated by pleural effusion or pneumothorax (nasal discharge, tachypnoea, dyspnoea, coughing). The disease can be fatal.
- ❖ Kittens may be vertically infected and develop a more severe disease at an early stage, due to the smaller diameter of the respiratory tract and their immature immune system.
- ❖ It is advisable to investigate for the presence of lungworm infection in outdoor cats with right-sided heart disease associated with signs of pulmonary hypertension.
- ❖ Stray outdoor cats are at higher risk of lungworm infection.
- ❖ The Baermann migration method is considered the enrichment technique of choice, but takes 24 h to produce results and false negatives may occur.
- ❖ The major limitation of copromicroscopy is that it is not diagnostic in the prepatent period, which lasts about 1–2 months.
- ❖ A nested-PCR assay specific for *A abstrusus* has been validated.
- ❖ Treatment options include fenbendazole paste, milbemycin oxime/praziquantel and various spot-on formulations (imidacloprid 10%/moxidectin 1%; emodepside 2.1%/praziquantel 8.6%; fipronil 8.3%/(S)-methoprene 10%/eprinomectin 0.4%/praziquantel 8.3%; or selamectin).
- ❖ In severe cases, broad-spectrum antibiotics should be given, together with corticosteroids.
- ❖ *C aerophila* has zoonotic potential and sporadic cases of human capillariasis, manifesting with a productive cough, haemoptysis and lung lesions, have been described.



worms with indirect life cycles. The prophylactic activity of some molecules used to treat nematode respiratory infections – as for *A vasorum* infection in dogs – is currently unknown; but the spot-on combination of fipronil 8.3%, (S)-methoprene 10%, eprinomectin 0.4% and praziquantel 8.3% (Broadline) was found effective as a preventative treatment for aelurostrongylosis in an experimental setting [EBM grade II].⁹³

Zoonotic risk

C aerophila has zoonotic potential and sporadic cases of human capillariasis have been described worldwide. The disease manifests as bronchitis with a productive cough, but the presence of haemoptysis and nodular infiltrative lesions in the lung means that pulmonary neoplasia needs to be considered as a differential diagnosis.¹⁷

Paragonimiasis is a food-borne zoonosis acquired by people eating raw crustaceans. Infected cats do not present a risk to people.^{55,97}

Funding

The authors received no specific grant from any funding agency in the public, commercial or not-for-profit sectors for the preparation of this article. The ABCD is supported by Merial, but is a scientifically independent body and its members receive no stipends from Merial.

Conflict of interest

The authors do not have any potential conflicts of interest to declare.

References

- Conboy G. Helminth parasites of the canine and feline respiratory tract. *Vet Clin North Am Small Anim Pract* 2009; 39: 1109–1126.
- Traversa D, Di Cesare A and Conboy G. Canine and feline cardiopulmonary parasitic nematodes in Europe: emerging and underestimated. *Parasit Vectors* 2010; 3: 62.
- Traversa D and Di Cesare A. Feline lungworms: what a dilemma. *Trends Parasitol* 2013; 29: 423–430.
- Brianti E, Giannetto S, Dantas-Torres F, et al. Lungworms of the genus *Troglostrongylus* (Strongylida: Crenosomatidae): neglected parasites of domestic cats. *Vet Parasitol* 2014; 202: 104–112.
- Bowman DD. Respiratory system parasites of the dog and cat (part ii): trachea and bronchi, and pulmonary vessels. In: Bowman DD (ed). Companion and exotic animal parasitology. International Veterinary Information Service IVIS, 2000; www.ivis.org.
- Pennisi MG, Niutta PP and Giannetto S. Longwormziekte bij katten veroorzaakt door *Aelurostrongylus abstrusus*. *Tijdschr Diergeneesk* 1995; 120: 262–266.
- Juste RA, Garcia AL and Mencía L. Mixed infestation of a domestic cat by *Aelurostrongylus abstrusus* and *Oslerus rostratus*. *Angew Parasitol* 1992; 33: 56–60.
- Millan J and Casanova JC. High prevalence of helminth parasite in feral cats in Majorca Island (Spain). *Parasitol Res* 2009; 106: 183–188.
- Jefferies R, Vrhovec MG, Wallner N, et al. *Aelurostrongylus abstrusus* and *Troglostrongylus* sp. (Nematoda: Metastrongyloidea) infections in cats inhabiting Ibiza, Spain. *Vet Parasitol* 2010; 173: 344–348.
- Brianti E, Gaglio G, Napoli E, et al. Feline lungworm *Oslerus rostratus* (Strongylida: Filaridae) in Italy: first case report and histopathological findings. *Parasitol Res* 2014; 113: 3853–3857.
- Fitzsimmons WM. *Bronchostrongylus subcrenatus* (Raillet & Henry, 1913) a new parasite recorded from the domestic cat. *Vet Rec* 1961; 73: 101–102.
- Brianti E, Gaglio G, Giannetto S, et al. *Troglostrongylus brevior* and *Troglostrongylus subcrenatus* (Strongylida: Crenosomatidae) as agents of broncho-pulmonary infestation in domestic cats. *Parasit Vectors* 2012; 5: 178.
- Brianti E, Gaglio G, Napoli E, et al. Evidence for direct transmission of the cat lungworm *Troglostrongylus brevior* (Strongylida: Crenosomatidae). *Parasitology* 2013; 140: 821–824.
- Tamponi C, Varcasia A, Brianti E, et al. New insights on metastrongyloid lungworms infecting cats of Sardinia, Italy. *Vet Parasitol* 2014; 16: 203: 222–226.
- Giannelli A, Passantino G, Nascimento Ramos RA, et al. Pathological and histological findings associated with the feline lungworm *Troglostrongylus brevior*. *Vet Parasitol* 2014; 204: 416–419.
- Traversa D, Di Cesare A, Milillo P, et al. Infection by *Eucoleus aerophilus* in dogs and cats: is another extra-intestinal parasitic nematode of pets emerging in Italy? *Res Vet Sci* 2009; 87: 270–272.
- Lalosević D, Lalosević V, Klem I, et al. Pulmonary capillariasis miming bronchial carcinoma. *Am J Trop Med Hyg* 2008; 78: 14–16.
- Risitano AL, Brianti E, Pennisi MG, et al. Aspetti clinici e anatomopatologici di aelurostrongilosi in un gattino. Proceedings of the LXII annual meeting of Società Italiana di Scienze Veterinarie (SISVet), 2008; 62: 169–170.
- Di Cesare A, Frangipane di Regalbono A, Tessarin C, et al. Mixed infection by *Aelurostrongylus abstrusus* and *Troglostrongylus brevior* in kittens from the same litter in Italy. *Parasitol Res* 2014; 113: 613–618.
- Varcasia A, Brianti E, Tamponi C, et al. Simultaneous infection by four feline lungworm species and implications for the diagnosis. *Parasitol Res* 2015; 114: 317–321.
- López C, Panadero R, Paz A, et al. Larval development of *Aelurostrongylus abstrusus* (Nematoda, Angiostrongylidae) in experimentally infected *Cerutuella (Cerutuella) virgata* (Mollusca, Helicidae). *Parasitol Res* 2005; 95: 13–16.
- Jezewski W, Buńkowska-Gawlik K, Hildebrand J, et al. Intermediate and paratenic hosts in the life cycle of *Aelurostrongylus abstrusus* in natural environment. *Vet Parasitol* 2013; 198: 401–405.
- Di Cesare A, Crisi PE, Di Giulio E, et al. Larval development of the feline lungworm *Aelurostrongylus abstrusus* in *Helix aspersa*. *Parasitol Res* 2013; 112: 3101–3108.
- Giannelli A, Ramos RA, Annoscia G, et al. Development of the feline lungworms *Aelurostrongylus abstrusus* and *Troglostrongylus brevior* in *Helix aspersa* snails. *Parasitol* 2014; 141: 563–569.
- Hamilton JM. Studies on re-infestation of the cat with *Aelurostrongylus abstrusus*. *J Comp Pathol* 1968; 78: 69–72.

- 26 Barrs VR, Swinney GR, Martin P, et al. **Concurrent *Aelurostrongylus abstrusus* infection and salmonellosis in a kitten.** *Aust Vet J* 1999; 77: 229–232.
- 27 Dirven M, Szatmári V, van den Ingh T, et al. **Reversible pulmonary hypertension associated with lungworm infection in a young cat.** *J Vet Cardiol* 2012; 14: 465–474.
- 28 Schnyder M, Di Cesare A, Basso W, et al. **Clinical, laboratory and pathological findings in cats experimentally infected with *Aelurostrongylus abstrusus*.** *Parasitol Res* 2014; 113: 1425–1433.
- 29 Diakou A, Di Cesare A, Aeriniotaki T, et al. **First report of *Troglostrongylus brevior* in a kitten in Greece.** *Parasitol Res* 2014; 113: 3895–3898.
- 30 Giannelli A, Colella V, Abramo F, et al. **Release of lungworm larvae from snails in the environment: potential for alternative transmission pathways.** *PLoS Negl Trop Dis* 2015; 9(4): e0003722.
- 31 Anderson RC. *Nematode parasites of vertebrates. Their development and transmission.* 2nd ed. CABI Publishing, Guildford, UK, 2000.
- 32 Gregory GG and Munday BL. **Internal parasites of feral cats from the Tasmanian Midlands and King Island.** *Aust Vet J* 1976; 52: 317–320.
- 33 Coman BJ, Jones EH and Driesen MA. **Helminth parasites and arthropods of feral cats.** *Aust Vet J* 1981; 57: 324–327.
- 34 Mundim TCD, Oliveira Jr SD, Rodrigues DC, et al. **Freqüência de helmintos em gatos de Uberlândia, Minas Gerais.** *Arq Bras Med Vet Zoo* 2004; 56: 562–563.
- 35 Abu-Madi MA, Al-Ahbab DA, Al-Mashhadani MM, et al. **Patterns of parasitic infections in faecal samples from stray cat populations in Qatar.** *J Helminthol* 2007; 81: 281–286.
- 36 Di Cesare A, Castagna C, Meloni S, et al. **Canine and feline infections by cardiopulmonary nematodes in Central and Southern Italy.** *Parasitol Res* 2011; 109: S87–S96.
- 37 Lucio-Forster A and Bowman DD. **Prevalence of fecal-borne parasites detected by centrifugal flotation in feline samples from two shelters in upstate New York.** *J Feline Med Surg* 2011; 13: 300–303.
- 38 Echeverry DM, Giraldo MI and Castaño JC. **Prevalencia de helmintos intestinales en gatos domésticos del departamento del Quindío, Colombia.** *Biomedica* 2012; 32: 430–436.
- 39 Kohart NA, Boes KM, Sponenberg DP, et al. **What is your diagnosis? Lung impression smear from a stray kitten.** *Vet Clin Pathol* 2014; 43: 113–114.
- 40 Philbey AW, Krause S and Jefferies R. **Vermineous pneumonia and enteritis due to hyperinfection with *Aelurostrongylus abstrusus* in a kitten.** *J Comp Pathol* 2014; 150: 357–360.
- 41 Lacorcía L, Gasser RB, Anderson GA, et al. **Comparison of bronchoalveolar lavage fluid examination and other diagnostic techniques with the Baermann technique for detection of naturally occurring *Aelurostrongylus abstrusus* infection in cats.** *J Am Vet Med Assoc* 2009; 35: 43–49.
- 42 Traversa D, Lia RP, Iorio R, et al. **Diagnosis and risk factors of *Aelurostrongylus abstrusus* (Nematoda, Strongylida) infection in cats from Italy.** *Vet Parasitol* 2008; 153: 182–186.
- 43 Iorio R and Traversa D. **New epidemiological and molecular insights into feline lungworm infection.** *Ann NY Acad Sci* 2008; 1149: 174–176.
- 44 Barutzki D and Schaper R. **Occurrence and regional distribution of *Aelurostrongylus abstrusus* in cats in Germany.** *Parasitol Res* 2013; 112: 855–861.
- 45 Knaus M, Kusi I, Rapti D, et al. **Endoparasites of cats from the Tirana area and the first report on *Aelurostrongylus abstrusus* (Railliet, 1898) in Albania.** *Wien Klin Wochenschr* 2011; 123 Suppl 1: 31–35.
- 46 Miró G, Montoya A, Jiménez S, et al. **Prevalence of antibodies to *Toxoplasma gondii* and intestinal parasites in stray, farm and household cats in Spain.** *Vet Parasitol* 2004; 126: 249–255.
- 47 Brianti E, Pennisi MG, Risitano AL, et al. ***Aelurostrongylosis felina*: epidemiologia e valutazione di un protocollo terapeutico alternativo.** Proceedings of the 59th SCIVAC International Congress, Rimini (Italy); 2008, May 30 – June 1.
- 48 Mircean V, Titilincu A and Vasile C. **Prevalence of endoparasites in household cat (*Felis catus*) populations from Transylvania (Romania) and association with risk factors.** *Vet Parasitol* 2010; 171: 163–166.
- 49 Barutzky D and Schaper R. **Results of parasitological examinations of faecal samples from cats and dogs in Germany between 2003 and 2010.** *Parasitol Res* 2011; 109: S45–S60.
- 50 Annoscia G, Latrofa MS, Campbell BE, et al. **Simultaneous detection of the feline lungworms *Troglostrongylus brevior* and *Aelurostrongylus abstrusus* by a newly developed duplex-PCR.** *Vet Parasitol* 2014; 199: 172–178.
- 51 Traversa D, Iorio R and Otranto D. **Diagnostic and clinical implications of a nested PCR specific for ribosomal DNA of the feline lungworm *Aelurostrongylus abstrusus* (Nematoda, Strongylida).** *J Clin Microbiol* 2008; 46: 1811–1817.
- 52 Di Cesare A, Castagna C, Otranto D, et al. **Molecular detection of *Capillaria aerophila*, an agent of canine and feline pulmonary capillariasis.** *J Clin Microbiol* 2012; 50: 1958–1963.
- 53 Sohn WM and Chai JY. **Infection status with helminthes in feral cats purchased from a market in Busan, Republic of Korea.** *Korean J Parasitol* 2005; 43: 93–100.
- 54 Foster S and Martin P. **Lower respiratory tract infections in cats. Reaching beyond empirical therapy.** *J Feline Med Surg* 2011; 13: 313–332.
- 55 Liu Q, Wei F, Liu W, et al. **Paragonimiasis: an important food-borne zoonosis in China.** *Trends Parasitol* 2008; 24: 318–323.
- 56 Mugnaini L, Papini R, Gorini G, et al. **Pattern and predictive factors of endoparasitism in cats in central Italy.** *Rev Med Vet* 2012; 163: 85–88.
- 57 Riggio F, Mannella R, Ariti G, et al. **Intestinal and lung parasites in owned dogs and cats from central Italy.** *Vet Parasitol* 2013; 193: 78–84.
- 58 Spada E, Proverbio D, Della Pepa A, et al. **Prevalence of faecal-borne parasites in colony stray cats in northern Italy.** *J Feline Med Surg* 2013; 15: 672–677.
- 59 Payo-Puente P, Botelho-Dinis M, Carvaja Urueña AM, et al. **Prevalence study of the lungworm *Aelurostrongylus abstrusus* in stray cats of Portugal.** *J Feline Med Surg* 2008; 10: 242–246.
- 60 Robben SR, le Nobel WE, Döpfer D, et al. **Infections with helminths and/or protozoa in cats in animal shelters in the Netherlands [Infecties met helminthen en/of protozoën bij katten in asielen in Nederland].** *Tijdschr Diergeneeskd* 2004; 129: 2–6.
- 61 Taubert A, Pantchev N, Globokar Vrhovec M, et al. **Lungworm infections (*Angiostrongylus vasorum*, *Crenosoma vulpis*, *Aelurostrongylus abstrusus*) in dogs and cats in Germany and Denmark in 2003–2007.** *Vet Parasitol* 2009; 159: 175–180.
- 62 Becker AC, Rohen M, Epe C, et al. **Prevalence of endoparasites in stray and fostered dogs and cats in Northern Germany.** *Parasitol Res* 2012; 111: 849–857.

- 63 Grabarević Ž, Čurić S, Tustonja A, et al. **Incidence and regional distribution of the lungworm *Aelurostrongylus abstrusus* in cats in Croatia.** *Veterinarski Arhiv* 1999; 69: 279–287.
- 64 András T and Péter T. **Data on worm infestation of domestic cats (*Felis catus*) in Hungarian hunting areas [Adatok a magyarországi vadászterületeken élő házimacska (*Felis catus domesticus*) féregfertőzöttségéről].** *Magyar Allatorvosok Lapja* 2002; 124: 26–30.
- 65 Capari B, Hamel D, Visser M, et al. **Parasitic infections of domestic cats, *Felis catus*, in western Hungary.** *Vet Parasitol* 2013; 192: 33–42.
- 66 Stoichev I, Sherkov S and Halachev M. **Pathology of cats from a region of Bulgaria with human endemic nephropathy.** *J Comp Pathol* 1982; 92: 99–107.
- 67 Grandi G, Calvi LE, Venco L, et al. ***Aelurostrongylus abstrusus* (cat lungworm) infection in five cats from Italy.** *Vet Parasitol* 2005; 134: 177–182.
- 68 Genchi M, Ferrari N, Fonti P, et al. **Relation between *Aelurostrongylus abstrusus* larvae excretion, respiratory and radiographic signs in naturally infected cats.** *Vet Parasitol* 2014; 206: 182–187.
- 69 Hamilton JM. **The number of *Aelurostrongylus abstrusus* larvae required to produce pulmonary disease in the cat.** *J Comp Pathol* 1967; 77: 343–346.
- 70 Dennler M, Bass DA, Gutierrez-Crespo B, et al. **Thoracic computed tomography, angiographic computed tomography, and pathology findings in six cats experimentally infected with *Aelurostrongylus abstrusus*.** *Vet Radiol Ultrasound* 2013; 54: 459–469.
- 71 Hamilton JM. **Production of immunity in the cat against lungworm disease by administration of third-stage larvae.** *J Comp Pathol* 1969; 79: 161–165.
- 72 Hamilton JM. **Passive immunization in lungworm infection of the cat.** *J Comp Pathol* 1968; 78: 331–333.
- 73 Hamilton JM. **Experimental lungworm disease of the cat. Association of the condition with lesions of the pulmonary arteries.** *J Comp Pathol* 1966; 76: 147–157.
- 74 Jonas AM, Swerczek TW and Downing SE. **Vaso-occlusive pulmonary artery disease in the cat: a preliminary report.** *Acta Radiol Suppl* 1972; 319: 237–244.
- 75 Naylor JR, Hamilton JM and Weatherley AJ. **Changes in the ultrastructure of feline pulmonary arteries following infection with the lungworm *Aelurostrongylus abstrusus*.** *Br Vet J* 1984; 140: 181–190.
- 76 Foster SF, Martin P, Braddock JA, et al. **A retrospective analysis of feline bronchoalveolar lavage cytology and microbiology (1995–2000).** *J Feline Med Surg* 2004; 6: 189–198.
- 77 Holmes PR and Kelly JD. ***Capillaria aerophila* in the domestic cat in Australia.** *Aust Vet J* 1973; 49: 472–473.
- 78 Miller BH, Roudebush P and Ward HG. **Pleural effusion as a sequela to aelurostrongylosis in a cat.** *J Am Vet Med Assoc* 1984; 185: 556–557.
- 79 Mooney ET, Rozanski EA, King RG, et al. **Spontaneous pneumothorax in 35 cats (2001–2010).** *J Feline Med Surg* 2012; 14: 385–392.
- 80 Yıldız K, Duru SY and Gokpinar S. **Alteration in blood gases in cats naturally infected with *Aelurostrongylus abstrusus*.** *J Small Anim Pract* 2011; 52: 376–379.
- 81 Losonsky JM, Thrall DE and Prestwood AK. **Radiographic evaluation of pulmonary abnormalities after *Aelurostrongylus abstrusus* inoculation in cats.** *Am J Vet Res* 1983; 44: 478–482.
- 82 Gerdin JA, Slater MR, Makolinski KV, et al. **Post-mortem findings in 54 cases of anesthetic associated death in cats from two spay-neuter programs in New York State.** *J Feline Med Surg* 2011; 13: 959–966.
- 83 Reinhardt S, Ottenjann M, Schunack B, et al. **Lungworm disease (*Aelurostrongylus abstrusus*) in a cat [Lungenwurmbefall (*Aelurostrongylus abstrusus*) bei einer Katze].** *Kleintierpraxis* 2004; 49: 239–246.
- 84 Di Cesare A, Iorio R, Crisi P, et al. **Treatment of *Troglostrongylus brevior* (Metastrongyloidea, Crenosomatidae) in mixed lungworm infections using spot-on emodepside.** *J Feline Med Surg* 2015; 17: 181–185.
- 85 Traversa D, Di Cesare A, Di Giulio E, et al. **Efficacy and safety of imidacloprid 10%/moxidectin 1% spot-on formulation in the treatment of feline infection by *Capillaria aerophila*.** *Parasitol Res* 2012; 111: 1793–1798.
- 86 Willard MD, Roberts RE, Allison N, et al. **Diagnosis of *Aelurostrongylus abstrusus* and *Dirofilaria immitis* infections in cats from a human shelter.** *J Am Vet Med Assoc* 1988; 192: 913–916.
- 87 Gaglio G, Cringoli G, Rinaldi L, et al. **Use of the FLOTAC technique for the diagnosis of *Aelurostrongylus abstrusus* in the cat.** *Parasitol Res* 2008; 103: 1055–1057.
- 88 Hamilton JM and Roberts RJ. **Immunofluorescence as a diagnostic procedure in lungworm disease of the cat.** *Vet Rec* 1968; 83: 401–403.
- 89 Intapan PM, Wongkham C, Imtawil KJ, et al. **Detection of *Paragonimus heterotremus* eggs in experimentally infected cats by a polymerase chain reaction-based method.** *J Parasitol* 2005; 91: 195–198.
- 90 Tantrawatpan C, Intapan PM, Janwan P, et al. **Molecular identification of *Paragonimus* species by DNA pyrosequencing technology.** *Parasitol Int* 2013; 341–345.
- 91 Traversa D, Di Cesare A, Milillo P, et al. **Efficacy and safety of imidacloprid 10%/moxidectin 1% spot-on formulation in the treatment of feline aelurostrongylosis.** *Parasitol Res* 2009; 105: S55–S62.
- 92 Traversa D, Milillo P, Di Cesare A, et al. **Efficacy and safety of emodepside 2.1%/praziquantel 8.6% spot-on formulation in the treatment of feline aelurostrongylosis.** *Parasitol Res* 2009; 105: S83–S89.
- 93 Knaus M, Chesterb ST, Rosentelb J, et al. **Efficacy of a novel topical combination of fipronil, (S)-methoprene, eprinomectin and praziquantel against larval and adult stages of the cat lungworm, *Aelurostrongylus abstrusus*.** *Vet Parasitol* 2014; 202: 64–68.
- 94 Giannelli A, Brianti E, Varcasia A, et al. **Efficacy of Broadline® spot on against *Aelurostrongylus abstrusus* and *Troglostrongylus brevior* lungworms in naturally infected cats from Italy.** *Vet Parasitol* 2015; 209: 273–277.
- 95 Iannino F, Iannetti L, Paganico D, et al. **Evaluation of the efficacy of selamectin spot-on in cats infested with *Aelurostrongylus abstrusus* (Strongylida, Filarioididae) in a Central Italy cat shelter.** *Vet Parasitol* 2013; 197: 258–262.
- 96 Barrs VR, Martin P, Nicoll RG, et al. **Pulmonary cryptococcosis and *Capillaria aerophila* infection in an FIV-positive cat.** *Aust Vet J* 2000; 78: 154–158.
- 97 Macpherson CNL. **Human behavior and the epidemiology of parasitic zoonoses.** *Int J Parasitol* 2005; 35: 1319–1331.

Available online at jfms.com