

## 2015 Advances in Hepatocellular Carcinoma

**Diagnostic and therapeutic management of hepatocellular carcinoma**

Francesco Bellissimo, Marilia Rita Pinzone, Bruno Cacopardo, Giuseppe Nunnari

Francesco Bellissimo, Marilia Rita Pinzone, Bruno Cacopardo, Giuseppe Nunnari, Department of Clinical and Experimental Medicine, Division of Infectious Diseases, University of Catania, 95100 Catania, Italy

**Author contributions:** Bellissimo F searched the literature; Bellissimo F and Pinzone MR wrote the paper; Cacopardo B and Nunnari G revised the manuscript; all the authors approved the final version of the manuscript to be published.

**Conflict-of-interest statement:** No conflict of interest.

**Open-Access:** This article is an open-access article which was selected by an in-house editor and fully peer-reviewed by external reviewers. It is distributed in accordance with the Creative Commons Attribution Non Commercial (CC BY-NC 4.0) license, which permits others to distribute, remix, adapt, build upon this work non-commercially, and license their derivative works on different terms, provided the original work is properly cited and the use is non-commercial. See: <http://creativecommons.org/licenses/by-nc/4.0/>

**Correspondence to:** Giuseppe Nunnari, MD, PhD, MPH, Department of Clinical and Experimental Medicine, Division of Infectious Diseases, University of Catania, Via Palermo 636, 95100 Catania, Italy. [g.nunnari@hotmail.com](mailto:g.nunnari@hotmail.com)  
Telephone: +39-95-7598443  
Fax: +39-95-7598666

Received: June 30, 2015

Peer-review started: July 4, 2015

First decision: July 20, 2015

Revised: August 3, 2015

Accepted: September 30, 2015

Article in press: September 30, 2015

Published online: November 14, 2015

**Abstract**

Hepatocellular carcinoma (HCC) is an increasing health problem, representing the second cause of cancer-related mortality worldwide. The major risk factor

for HCC is cirrhosis. In developing countries, viral hepatitis represent the major risk factor, whereas in developed countries, the epidemic of obesity, diabetes and nonalcoholic steatohepatitis contribute to the observed increase in HCC incidence. Cirrhotic patients are recommended to undergo HCC surveillance by abdominal ultrasounds at 6-mo intervals. The current diagnostic algorithms for HCC rely on typical radiological hallmarks in dynamic contrast-enhanced imaging, while the use of  $\alpha$ -fetoprotein as an independent tool for HCC surveillance is not recommended by current guidelines due to its low sensitivity and specificity. Early diagnosis is crucial for curative treatments. Surgical resection, radiofrequency ablation and liver transplantation are considered the cornerstones of curative therapy, while for patients with more advanced HCC recommended options include sorafenib and trans-arterial chemo-embolization. A multidisciplinary team, consisting of hepatologists, surgeons, radiologists, oncologists and pathologists, is fundamental for a correct management. In this paper, we review the diagnostic and therapeutic management of HCC, with a focus on the most recent evidences and recommendations from guidelines.

**Key words:** Cancer; Chronic hepatitis; Cirrhosis; Hepatitis B virus; Hepatocellular carcinoma; Hepatitis C virus; Liver

© **The Author(s) 2015.** Published by Baishideng Publishing Group Inc. All rights reserved.

**Core tip:** Hepatocellular carcinoma is an increasing health problem, representing the second cause of cancer-related mortality worldwide. The major risk factor for hepatocellular carcinoma (HCC) is cirrhosis. Early diagnosis is crucial for curative treatments. As a consequence, patients at risk of developing HCC should undergo surveillance programs in order to detect HCC in the initial stage. Surgical resection, radiofrequency ablation and liver transplantation are considered the

cornerstones of curative therapy, while for patients with more advanced HCC recommended options include sorafenib and trans-arterial chemo-embolization.

Bellissimo F, Pinzone MR, Cacopardo B, Nunnari G. Diagnostic and therapeutic management of hepatocellular carcinoma. *World J Gastroenterol* 2015; 21(42): 12003-12021 Available from: URL: <http://www.wjgnet.com/1007-9327/full/v21/i42/12003.htm> DOI: <http://dx.doi.org/10.3748/wjg.v21.i42.12003>

## INTRODUCTION

Hepatocellular carcinoma (HCC) is one of the leading causes of cancer-related deaths worldwide. More than 700000 new cases are diagnosed every year throughout the world and high incidence to mortality ratio (1.07) makes HCC the second most common cause of cancer-related deaths worldwide<sup>[1]</sup>.

Although the majority of cases occur in Asia and Africa, the incidence has increased even in the developed world. The geographical variation in the incidence of HCC is mostly related with the different prevalence of major risk factors for HCC, such as hepatitis C virus (HCV) and hepatitis B virus (HBV) infection<sup>[2]</sup>. In developed countries, the epidemic of obesity, diabetes and nonalcoholic steatohepatitis (NASH) is also believed to contribute to the observed increase in HCC incidence<sup>[3]</sup>. However, the overriding risk factor for HCC, which is responsible for HCC in 80%-90% of cases regardless of etiology, is the presence of cirrhosis<sup>[4,5]</sup>.

By recognizing the risk factors for HCC, high-risk groups can be identified and followed up with screening strategies. In fact, the management of high-risk patients with screening and surveillance has the real potential to detect HCC early and improve patient outcomes. When HCC is detected earlier, patients are candidates to receive curative treatments.

In this paper, we review the diagnostic and therapeutic management of HCC, with a focus on the most recent evidences and recommendations from guidelines.

## DIAGNOSIS

Hepatic nodules can be detected on Ultrasounds (US), including contrast-enhanced US (CEUS), or on other noninvasive techniques, such as contrast-enhanced computerized tomography (CT), magnetic resonance imaging (MRI) and positron emission tomography (PET)-CT. The typical vascular profile of HCC on dynamic imaging is characterized by early arterial phase enhancement followed by loss of enhancement in the portal venous phase and delayed phase in comparison to the surrounding liver<sup>[6]</sup>.

Moreover, molecular biomarkers could potentially

be used for diagnosis, as well as prognostic evaluation and may help defining the individualized therapeutic approach to HCC. Figure 1 illustrates the diagnostic algorithms endorsed by the American Association for the Study of Liver Diseases (AASLD)<sup>[7]</sup>.

## US

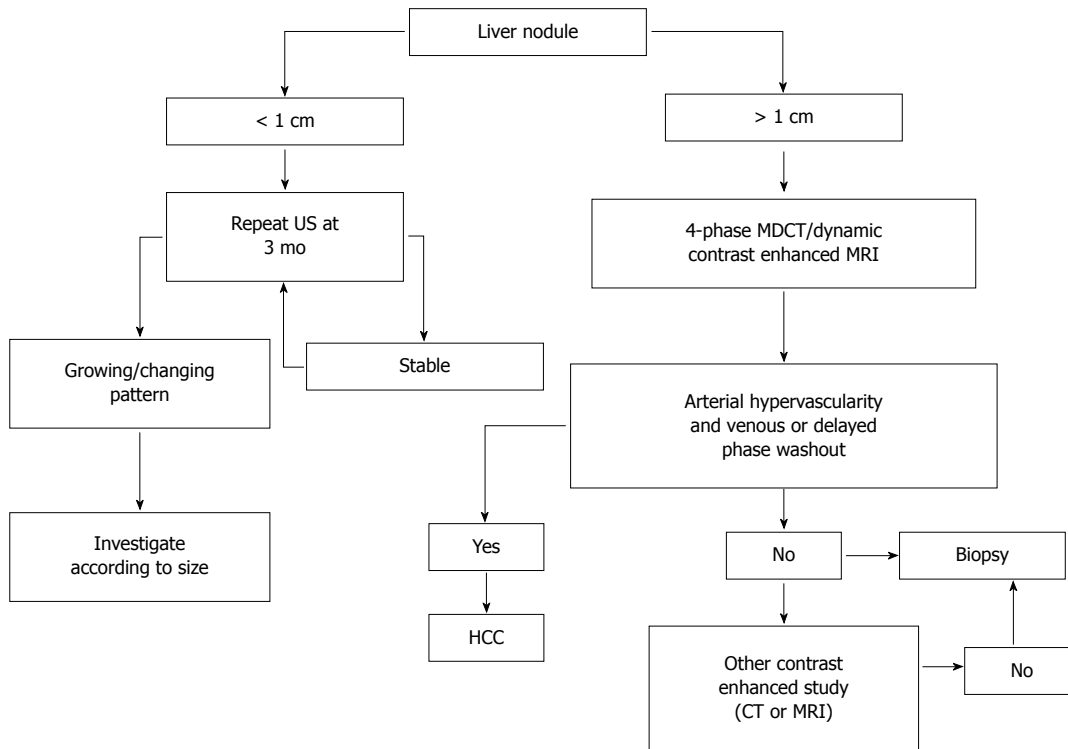
Early diagnosis of HCC is important because, as expected, treatment is more effective when the tumor is small<sup>[8-10]</sup>. Dysplastic nodules (DNs) may develop into carcinoma<sup>[11]</sup>. Early detection of DN with small areas of HCC is fundamental for effective treatment.

Cirrhotic patients are recommended to undergo HCC surveillance by abdominal US at 6-month intervals. However, the diagnosis of small HCC nodules may be challenging, as it is often difficult to differentiate benign from malignant lesions in the context of nodular cirrhosis; moreover, US depends on the operator and has limited sensitivity in obese patients. On the other hand, US is less expensive than other techniques and is radiation-free.

For HCC, a stepwise process of carcinogenesis has been proposed, involving a progression from regenerative nodules (RNs) to low-grade DN or high-grade DN to DN with a focus of HCC and finally to HCC. This progression has been suggested to correlate with changes in the blood supply and perfusion of the nodules, which may be used to differentiate focal liver lesions<sup>[8,12-14]</sup>. Recently, SonoVue, a blood-pool marker used in CEUS, has been reported to help distinguishing RNs from small HCC based on the different enhancement pattern<sup>[15-18]</sup>. RN has an intranodular blood supply that is similar to the surrounding parenchyma. On the other hand, HCC usually exhibits an enhancement pattern in the arterial phase and wash-out in the late phase<sup>[19-26]</sup>. DN-HCC nodules have a mixed enhancement behavior, as they are composed of two different cells, high-grade HCC and atypical hepatic cells and their enhancement features are partially similar to HCC and partially similar to RNs<sup>[27]</sup>. Of interest, CEUS has been suggested to promote the diagnostic accuracy of biopsy, decreasing the false-negative rate for malignant lesions. In fact, CEUS may be used to identify the areas of viable tumor<sup>[27]</sup>. A biopsy of DN-HCC without CEUS guidance is more likely to give false-negative results, significantly affecting the possibility to early detect and treat HCC.

## CT

CT is largely used in most centers to make the radiological diagnosis of HCC after a liver nodule is detected on US. Most centers use a four-phase multidetector CT (MDCT) scan, which consists of a non-enhanced phase, an arterial phase (which occurs 20-30 s after contrast injection), a portal venous phase (6580 s after contrast injection) and a delayed phase. On the four-phase CT, HCC classically appears as a hyper-attenuated lesion in the arterial phase, with loss



**Figure 1** American Association for the Study of Liver Diseases diagnostic algorithm for suspected hepatocellular carcinoma (adapted from<sup>[7]</sup>). CT: Computed tomography; MDCT: Multidetector CT; MRI: Magnetic resonance imaging; US: Ultrasound; HCC: Hepatocellular carcinoma.

of enhancement termed rapid washout in the portal venous and/or delayed phase. CT has high specificity but variable sensitivity for detecting HCC. In a systematic review, traditional spiral CT was reported to have a specificity of 93% but a sensitivity of only 68% in diagnosing HCC. A more recent review assessing the diagnostic accuracy of the 64-slice MDCT technology vs spiral CT found improved sensitivity (65%-79% compared to 37%-54%), with similar specificity (above 90%)<sup>[28]</sup>. However, sensitivity dropped to 33.45% for nodules smaller than 1 cm.

### MRI

MRI is an appealing imaging technique, since it does not use ionizing radiation. MRI allows the differentiation between tumoral and normal liver parenchyma using magnetic fields, even without a contrast media<sup>[29]</sup>. Traditional dynamic contrast-enhanced MRI of the liver is performed using gadolinium chelates. In gadolinium-enhanced MRI, the typical HCC lesion is hyper-intense on T1-weighted images during the arterial phase and exhibits rapid washout during portal venous and delayed phases<sup>[12,30,31]</sup>. The sensitivity of standard gadolinium-enhanced MRI is around 90%, with a specificity of at least 95% for the detection of HCC greater than 2 cm in diameter<sup>[32]</sup>. Dynamic MRI appears superior to CT for the detection of HCC nodules<sup>[33,34]</sup>, but its sensitivity is highly affected by the lesion size, being as low as 30% in the case of lesions smaller than 2 cm<sup>[35,36]</sup>.

Specific contrast agents have been developed to

improve the sensitivity of MRI for HCC, including the "dual contrast" agents (gadolinium-ethoxybenzyl-diethylenetriaminepentaacetic acid and gadobenate dimeglumine), which work both as markers of hepatobiliary excretion and vascularization. HCC nodules imaged with these contrast agents do not exhibit uptake, unlike benign nodules on the delayed phase<sup>[37]</sup>. While it appears performing similarly to MDCT for lesions larger than 2 cm, enhanced MRI might be more sensitive for lesions smaller than 1 cm<sup>[38]</sup>.

### Nuclear imaging

Both <sup>18</sup>F-FDG and <sup>11</sup>C-acetate PET imaging have been used for HCC detection and staging<sup>[39-41]</sup>. However, up to 40%-50% of HCC are not sensitive to <sup>18</sup>F-FDG PET, because of their high expression of the glucose-6-phosphatase enzyme, which prevents intracellular accumulation of <sup>18</sup>F-FDG<sup>[39]</sup>. On the other hand, <sup>11</sup>C-acetate, which is believed to mainly participate in fatty acid synthesis in the liver, has been suggested to have increased sensitivity and specificity in comparison to <sup>18</sup>F-FDG<sup>[39,41,42]</sup>. However, several studies have reported that <sup>11</sup>C-acetate PET does not properly differentiate HCC from benign lesions<sup>[41,43-45]</sup>, because the latter also accumulate <sup>11</sup>C-acetate. Some recent studies<sup>[41,44-47]</sup> have suggested dynamic PET with kinetic modeling to be a promising tool to differentiate benign hepatic tumors from HCC.

### Biomarkers

A-fetoprotein (AFP) is the most widely used and

broadly known biomarker for HCC, but its use as an independent tool for HCC surveillance is not recommended by current guidelines due to its low sensitivity and specificity. In the past, a significant concentration of AFP in the serum of a patient with liver cirrhosis and a suspicious mass in the liver larger than 2 cm was sufficient to diagnose HCC<sup>[48]</sup>. However, the current diagnostic algorithms endorsed by the AASLD and the European Association for the Study of the Liver strictly rely on typical radiological hallmarks in dynamic contrast-enhanced imaging apart from biomarkers<sup>[7,48,49]</sup>.

Three serum biomarkers have been suggested as tools to determine the risk of liver cancer in high-risk populations worldwide: AFP, the ratio of lecithin-bound AFP to total AFP (AFP-L3), and des-gamma-carboxyprothrombin (DCP). However, most studies on the performance of biomarkers in HCC detection have not been performed in a surveillance setting but compared levels of predefined biomarkers in patients with HCC with a control group, in most cases represented by patients with chronic liver diseases. A randomized controlled study performed in a high-risk population in China showed that screening by AFP measurement led to earlier diagnosis of HCC but had no impact on mortality<sup>[50]</sup>. On the other hand, semiannual screening for HCC by AFP measurement in a population-based study in Alaska was effective in detecting HCC at early stages and significantly prolonged survival rates<sup>[51]</sup>.

A meta-analysis on the performance of AFP in diagnosing HCC included seven studies and revealed a pooled sensitivity of 66% with a specificity of 86% [area under curve (AUC) = 0.87]<sup>[52]</sup>. In a further meta-analysis including ten studies the pooled sensitivity of AFP for the diagnosis of HCC was 51.9%, with a specificity of 94% (AUC = 0.81)<sup>[53]</sup>. A major drawback of AFP as a surveillance tool is that serum levels are influenced by the activity of the underlying liver disease and therefore increased in patients with elevated alanine aminotransferase (ALT) levels, even in the absence of HCC, as shown in the HALT-C trial<sup>[54]</sup>. Furthermore, HCC biology is quite heterogeneous, with only a proportion of patients with HCC having elevated AFP serum levels, leading to low sensitivity of the marker. As a consequence, new complementary markers have been studied. The clinical utility of high-sensitivity AFP-L3 (hs-AFP-L3) in early prediction of HCC development in patients with chronic HBV or HCV infection was recently evaluated in a large Japanese study. Even in subjects with low AFP levels and without suspicious ultrasound findings, an elevation of hs-AFP-L3 was an early predictor of HCC development: in fact, hs-AFP-L3 increased in 34.3% of patients one year prior to diagnosis of HCC<sup>[55,56]</sup>. Numerous studies have investigated the performance of other markers, including  $\alpha$ -L-fucosidase<sup>[57]</sup>, glypican-3 (GPC-3), insulin-like growth factor<sup>[58]</sup>, vascular endothelial growth factor (VEGF), or Dickkopf-1<sup>[59]</sup>, Golgi protein 73 (GP73),

interleukin-6 (IL-6) and squamous cell carcinoma antigen (SCCA)<sup>[60]</sup>. In a study comparing 144 patients with HCC to 152 patients with cirrhosis and 56 healthy controls, GP73 had a sensitivity of 62% and a specificity of 88% at a cut-off of 10 relative units<sup>[61]</sup>. Another study, including 4217 subjects (789 with HCC), revealed a sensitivity of 74.6% and a specificity of 97.4% at a cut-off of 8.5 relative units<sup>[62]</sup>. Using different cut-off values, IL-6 sensitivity ranged from 46% to 73% with a specificity of 87% to 95%<sup>[60,63,64]</sup>; in a large study including 961 patients, SCCA had a sensitivity of 42% and specificity of 83% using a cut-off of 3.8 ng/mL<sup>[60,65]</sup>.

Serum IL-17 levels have been reported to be elevated in HCC patients<sup>[66]</sup>. In a retrospective study, Liu *et al*<sup>[67]</sup> found that plasma IL-17 concentration had a sensitivity of 74.3% and specificity of 75.6% (AUC = 0.86) at the cut-off value of 4.23 ng/L; however, the diagnostic accuracy of IL-17 was lower than AFP, which had a sensitivity and specificity of 100% and 66% respectively, at the cut-off value of 10.25 mg/L (AUC = 0.96).

Osteopontin, an integrin-binding glycol-phosphoprotein, was investigated in seven studies summarized in a meta-analysis<sup>[52]</sup>. The pooled sensitivity of osteopontin for HCC was 86% with a specificity of 86%, showing a diagnostic accuracy similar to that of AFP; however, further validation studies are needed before recommending the use of this biomarker in clinical practice.

Some studies have investigated the combined diagnostic performance of the three more validated non-invasive biomarkers used in HCC, namely AFP, AFP-L3 and DCP. By comparing 164 European patients with HCC to 422 subjects with chronic liver disease, a significant increase in AFP serum levels was shown in those with advanced HCC and viral hepatitis, while DCP was more frequently elevated in those with early-stage and NASH-associated HCC. Neither of the two parameters, if taken alone, could independently identify more than 30% of patients with HCC but combination of AFP (cut-off 10 ng/mL) and DCP (cut-off 5 ng/mL) showed a sensitivity of 55% for early stage HCC and 78% for all stages<sup>[68]</sup>. A further increase in sensitivity (up to 84%) was observed by adding AFP-L3<sup>[69]</sup>. The additional use of clinical variables, like age and gender, further improved the performance of the model<sup>[70,71]</sup>.

A number of signal transduction pathways have been recognized as critical players in the pathophysiology of hepatocarcinogenesis, including the Wnt/ $\beta$ -Catenin pathway, the p53 pathway, the tumor suppressor retinoblastoma protein pRb1 pathway, the mitogen-activated protein kinase pathway, the Ras pathway, JAK/STAT signaling, mechanisms of cellular stress response, like heat shock proteins, epidermal growth factor receptor and transforming growth factor- $\beta$  signaling<sup>[72,73]</sup>.

Gene expression profiling of peripheral blood mono-

nuclear cells using microarrays and bioinformatics-driven data analysis identified a blood-based signature of three genes, namely Chemokine (C-X-C motif) receptor 2 (CXCR2), C-C chemokine receptor type 2 (CCR2) and E1A Binding Protein P400 (EP400), able to predict HCC with a sensitivity of 93% and a specificity of 89%<sup>[74]</sup>. High-throughput metabolomics technology with the comprehensive analysis of small molecular metabolites may identify serum metabolic profiles to be used as biomarkers in HCC diagnosis. Molecular signatures may help to distinguish dysplastic nodules from well-differentiated HCC. In Asian and Western patients with HCV infection, specific gene signatures have been reported to accurately reflect the pathological progression of disease from cirrhosis to dysplasia to early and advanced HCC<sup>[75,76]</sup>. Moreover, a three-gene set including glypican3 (GPC3; 18-fold increase in HCC,  $P = 0.01$ ), LYVE1 (12-fold decrease in HCC,  $P = 0.0001$ ) and surviving (2.2-fold increase in HCC,  $P = 0.02$ ) had an accuracy of 94% to distinguish DNs from early HCC in HCV-related cirrhosis<sup>[77]</sup>. Heat shock protein 70 and cyclase-associated protein 2 are other tissue biomarkers potentially useful in the diagnosis of HCC<sup>[78,79]</sup>.

As for novel biomarkers, microRNA (miRNA) have received particular attention<sup>[80]</sup>. miRNAs are small non-coding and evolutionary conserved RNA molecules that serve as posttranscriptional regulators of mRNA expression and interfere with mRNA translation to protein<sup>[81]</sup>. miRNAs are able to conserve their function into the cell by regulating the expression of a target population of molecules; moreover, they can be released from the cell both in combination with other proteins or as a free molecule<sup>[82-88]</sup>.

Differences in miRNA expression patterns in several malignant conditions, including HCC, have been found<sup>[89-91]</sup>. In particular, three miRNAs, miR-122, miR-192 and miR-199a/b-3p, account for more than 70% of total miRNA released by normal liver tissue<sup>[91]</sup>. In HCC, a broad spectrum of changes in microRNAoma has been reported<sup>[91-94]</sup>, suggesting that miRNAs may potentially become valid biomarkers in HCC. To improve the diagnostic utility of miRNAs in HCC, Li *et al.*<sup>[95]</sup> performed deep sequencing in pooled samples from patients with chronic HBV patients, HCC and controls with and without cancer. They recognized a pattern of 6 miRNA differentially expressed in patients with HCC. The use of three miRNAs (miR-25, miR-375 and let7f) had a sensitivity of 97.9% and a specificity of 99.1% to discriminate between controls and HCC patients. Of interest, the use of two miRNAs (miR-10a and miR-125b) could adequately discriminate the cohort with chronic HBV and HBV-associated HCC with an AUC of 99.2% (sensitivity 98.5% and specificity 98.5%)<sup>[95]</sup>. In another study, a panel of 7 miRNAs (miR-122, miR-192, miR-21, miR-223, miR-26a, miR-27a and miR-801) provided a high diagnostic accuracy for the identification of HBV-related HCC<sup>[96]</sup>,

with a sensitivity of 81.8% and a specificity of 83.5%, independently of disease stage. However, the expression of selected miRNA was analyzed using RT-PCR, which may be critical for clinical translation of these findings<sup>[96]</sup>. miR-21, which is the most frequently deregulated miRNA in cancer, was found at higher level both in sera and plasma of HCC patients<sup>[97,98]</sup>, while other studies showed no significant differences<sup>[99,100]</sup>. Similarly, miR-122, the most abundant miRNA in the liver, was also found at high level in sera of HCC patients<sup>[98,99]</sup>. Other inflammatory conditions of the liver, such as acute and chronic hepatitis and NASH may strongly influence miR-122 levels<sup>[101,102]</sup>. In this setting, further studies are required to establish the capability of these biomarkers to discriminate between chronic liver diseases and HCC.

## STAGING

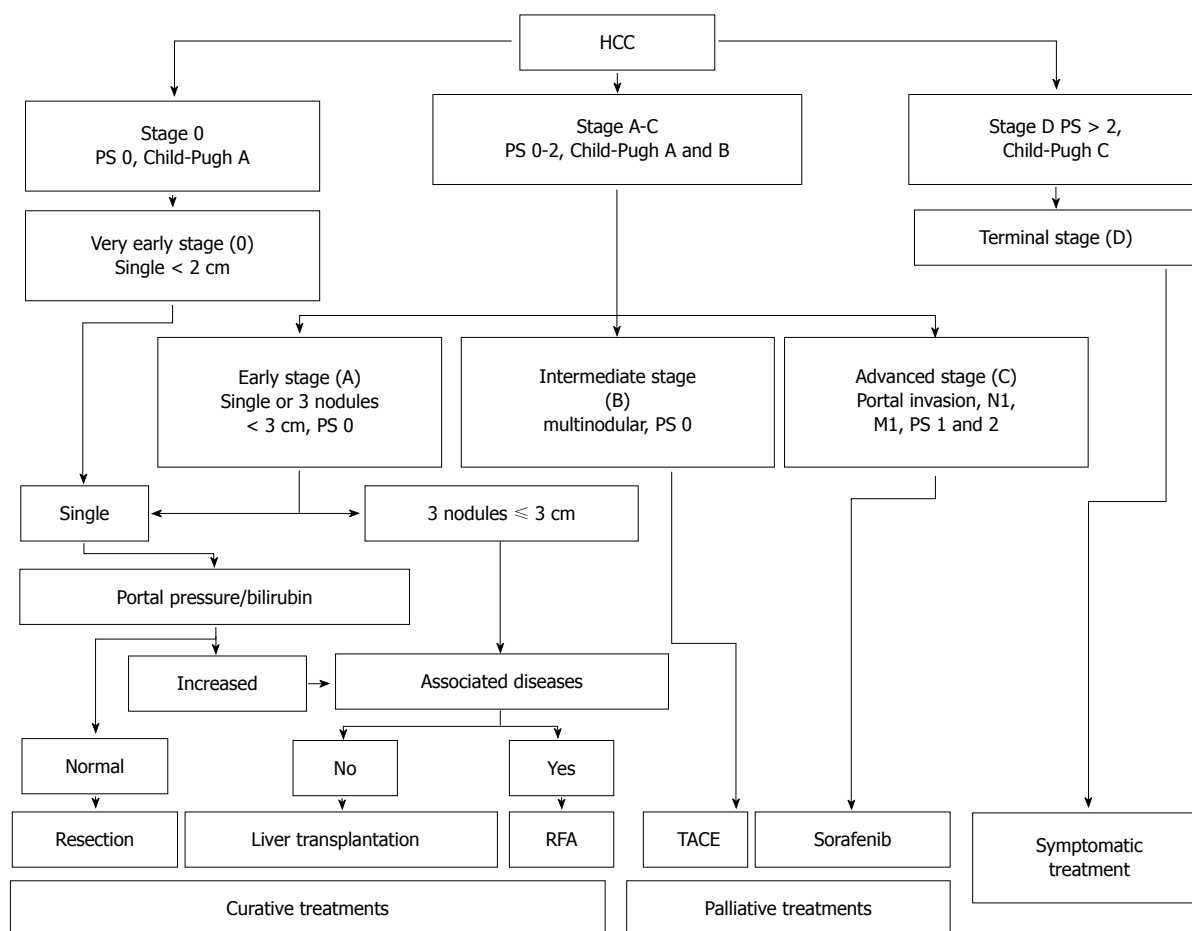
A number of staging systems have been used for HCC, even if the Barcelona Clinic Liver Cancer (BCLC) staging system is the most extensively used in clinical practice. BCLC staging system includes the evaluation of tumor stage, cirrhosis stage, functional performance status (PS) and it links staging with a treatment algorithm<sup>[103]</sup>. Moreover, the BCLC staging system was endorsed by both the American and European liver society and validated in European and American cohorts<sup>[104,105]</sup>.

Early stage HCC (stage 0) has the best prognosis and is characterized by the presence of one lesion smaller than 2 cm in diameter, with no evidence of vascular invasion, in patients with stable cirrhosis (Child-Pugh class A).

Patients with stage A HCC could present with either a solitary lesion or up to three lesions of less than 3 cm in diameter. These patients have relatively preserved liver function (Child-Pugh class A or B) and good functional status (PS 0-2). The 5-year survival rate is 50%-75%; as reported in Figure 2, treatment may be different based on the presence of portal hypertension, the degree of liver dysfunction and other comorbidities.

Patients with intermediate stage HCC (stage B) have Child-Pugh class A or B cirrhosis, good functional status (PS 0) and multinodular HCC, with no evidence of vascular invasion. Patients with evidence of vascular invasion or extra-hepatic spread have advanced stage HCC (stage C). These patients typically have worse functional status (PS 1 or 2).

Patients with terminal stage HCC (stage D) present with decompensated cirrhosis (Child-Pugh class C), poor functional status (PS > 2), and advanced tumor growth (vascular invasion and/or extra-hepatic spread). Unfortunately, these patients receive no benefit from the currently available therapies, and survival is usually around 3 mo. Figure 2 illustrate the BCLC staging system and treatment strategies for HCC.



**Figure 2** Barcelona Clinic Liver Cancer staging system and treatment strategy for hepatocellular carcinoma (adapted from Ref. [49]). M: Metastasis classification; N: Node classification; PS: Performance status; RFA: Radiofrequency ablation; TACE: Transarterial chemoembolization.

## TREATMENT

Several therapeutic options are available for HCC, depending on HCC stage, liver function, comorbidities, and local clinical expertise. A multidisciplinary team, consisting of hepatologists, surgeons, radiologists, oncologists and pathologists, is fundamental for a correct management.

### Surgery

The evaluation of liver functional reserve before hepatectomy is fundamental the maximum amount of liver mass that can be safely removed: on the one hand, liver functional overestimation may lead to hepatic failure; on the other hand, poor resection may significantly increase the risk of early recurrence of HCC.

The most important methods to assess liver function before surgery are the galactose tolerance test, <sup>99m</sup>Tc-galactosyl human serum albumin liver scintigraphy and the indocyanine green (ICG) test. Makuuchi's selection criteria for hepatectomy rely on three factors, ascites, serum bilirubin and ICG retention rate at 15 min (ICGR15)<sup>[106]</sup>. Patients are considered eligible for liver resection if they have no

ascites and if serum bilirubin is ≤ 2 mg/dL. Patients with total bilirubin of 1.1-1.9 mg/dL can undergo partial liver resection; for patients with serum bilirubin ≤ 1 mg/dL, the extent of resection is based on ICGR15: (1) resection of 2/3 of the total liver volume (TLV) (e.g., right lobectomy) in patients with normal ICGR15 of < 10%; (2) resection of 1/3 of the TLV (e.g., left lobectomy) in patients with ICGR15 of 10%-19%; (3) resection of 1/6 of the TLV in patients with ICGR15 of 20%-29%; and (4) limited resection or enucleation in patients with ICGR15 ≥ 30%.

A surgical mortality rate of 0% has been reported in 1056 consecutive hepatic resections performed in accordance with these criteria<sup>[107]</sup>.

In patients with portal venous invasion<sup>[108]</sup>, the area supplied by the portal vein branches should be systemically removed as much as possible within the acceptable range of liver function. In this context, systematic subsegmentectomy has been developed to overcome the potential incompatibility between the attempt to remove cancer and the need to preserve liver function<sup>[109]</sup>. Tumor stage, tumor size, number of tumors and capsule formation predict recurrence-free survival. Moreover, vascular invasion is a poor indicator of long-term survival<sup>[110]</sup>. In one study, risk

factors for early recurrence (within 2 years after surgery) were non-anatomical resection, microscopic vascular invasion, and AFP  $\geq$  32 ng/mL<sup>[111]</sup>. Another retrospective study confirmed the association between the type of surgical approach and the outcome, showing that the cumulative survival rate was significantly higher after anatomical resection compared to non-anatomical resection<sup>[112]</sup>.

As reported above, one crucial issue is the determination of the adequate liver remnant volume after hepatectomy. In normal livers, it is important to preserve the 20%-40% of the TLV or the standard liver volume (SLV)<sup>[113-120]</sup>. Anderson *et al* suggested that the smallest adequate liver remnant volume should be  $\geq$  20% of the SLV in patients with no underlying chronic liver disease<sup>[114,121]</sup>. However, HCC usually develops in patients with chronic hepatitis or cirrhosis, who are at risk of hepatic failure in case of insufficient liver remnant volume after hepatectomy. In this setting, portal vein embolization (PE) may prevent hepatic failure, because the portal vein branches are blocked to induce compensatory hypertrophy in the remnant liver area<sup>[122]</sup>. Three-dimensional CT scan allows an accurate determination of the position of major blood vessels and the tumor, as well as resection margins, and liver remnant volume<sup>[123]</sup>.

Perioperative complications include bile leakage, hemorrhage and intra-abdominal abscesses<sup>[124,125]</sup>. Intraperitoneal drainage is necessary for monitoring and treatment of these complications, even if the Center for Disease Control and Prevention guidelines do not recommend routine drainage in elective hepatectomy. If drainage is required, a closed suction drain should be used and placed through a separate incision distant from the operative one. Moreover, the drainage should be removed as soon as possible<sup>[126]</sup>. These recommendations have been validated in several studies<sup>[127-133]</sup>. Moreover, in a randomized clinical trial, subcutaneous drainage was not effective in preventing surgical site infections<sup>[134]</sup>. Hepatic failure and disseminated intravascular coagulation are other postoperative complications. In one study, the authors evaluated the efficacy of steroids to improve liver function after hepatectomy<sup>[135]</sup>. They found that serum bilirubin levels were significantly lower in the steroid group on post-operative day (POD) 2 compared with the non-steroid group. The postoperative time courses of bilirubin, IL-6 and the C-reactive protein level were significantly lower whereas the prothrombin level was significantly higher in the steroid arm. No differences in the proportion of patients with complications and the length of hospital stay were reported between the two groups. To unify the definition of post-hepatectomy liver failure (PHLF), the International Study Group of Liver Surgery proposed defining PHLF as an increased international normalized ratio and concomitant hyperbilirubinemia on or after POD 5<sup>[136]</sup>. PHLF seems to predict the incidence of complications and mortality

better than the 50-50 criteria [*i.e.* prothrombin time (PT) < 50% and serum bilirubin > 50 mmol/L]<sup>[137]</sup> and MELD score<sup>[138]</sup>.

### **Liver transplantation**

Liver transplantation has become a feasible alternative for many patients with HCC, given the advances in surgical techniques and immunosuppression.

In 1996, Mazzaferro *et al*<sup>[139]</sup> defined the so-called Milan criteria, which identified as eligible for transplantation patients with solitary lesions < 5 cm in diameter and those with up to 3 lesions, each one < 3 cm in diameter. Similar survival rates in patients with tumors < 3 cm have been reported by the Bismuth group<sup>[140]</sup>. The Milan criteria have been accepted worldwide to identify patients which can be safely transplanted. The limited number of available organs is the main limitation for this procedure. Yao *et al*<sup>[141,142]</sup> demonstrated that patients with a single lesions  $\leq$  6.5 cm, or up to three lesions each one  $\leq$  4 cm with a cumulative diameter  $\leq$  8 cm had surgical outcomes similar to those transplanted on the basis of Milan criteria. Tumor histology has an important impact on post-transplantation survival, with better outcome in patients with well-differentiated tumors<sup>[143,144]</sup>. The availability of transplantable grafts remains the critical issue for all patients awaiting liver transplantation, considering that time is a major determinant of overall survival<sup>[145-153]</sup>. Living donation can be a good choice for transplantation in patients with HCC because the transplant can be planned with an optimal timing to both assess the tumor aggressiveness and minimize the risk of recurrence<sup>[154-160]</sup>. Another factor that can affect the risk of recurrence after transplantation is the use of immunosuppressive agents. Sirolimus, a bacterial macrolide with immunosuppressive and antineoplastic properties, which inhibits IL-2-mediated lymphocyte proliferation, seems to decrease metastatic tumor growth and angiogenesis in the liver. It was demonstrated that the administration of post-transplant sirolimus, within a steroid-free protocol and a low tacrolimus target, was associated with decreased risk of tumor recurrence and no significant increase in the risk of infection and hepatic artery thrombosis<sup>[161-165]</sup>.

### **Non-surgical management**

Among non-surgical approaches, percutaneous ethanol injection (PEI), microwave ablation (MWA) and percutaneous radiofrequency ablation (RFA) represent the three most widely used techniques for the treatment of HCC less than 5 cm in diameter and/or with less than 3 tumoral lesions.

In RFA, electrical current is applied *via* an electrode resulting in resistive heating and tissue hyperthermia<sup>[166]</sup>. Tissues adjacent to the electrode are the most effectively heated<sup>[167-169]</sup>. The mechanism of cytotoxicity in RFA depends on tissue impedance,

with power deposition hindered in regions of high tissue impedance, such as the surrounding lung or tissue adjacent to the electrode, that has undergone water vaporization due to rapid heating<sup>[166,169]</sup>. Multiple engineering designs have been developed to overcome the limitations caused by tissue impedance, including multi-tined electrodes to expand the contact surface area, saline injection, and internal cooling. Moreover, RFA requires the placement of grounding pads on the patient to close the electrical circuit, and skin burns related to the pads have been reported<sup>[170,171]</sup>. However, in clinical practice skin burns are rare, considering that larger grounding pads are usually used to improve the dispersion of thermal energy<sup>[172]</sup>. RFA efficacy may be limited by the "heat sink" effect, consisting in heat dissipation resulting from blood flow. This effect is more marked for lesions close to the liver hilum<sup>[173]</sup>. There are several reports on RFA use in both primary and metastatic liver tumors. In a Cochrane database analysis, including 11 randomized clinical trials, Weis *et al.*<sup>[174]</sup> analyzed a total of 1819 participants with HCC with the primary outcome of overall survival, comparing RFA to hepatic resection<sup>[175-177]</sup>, PEI<sup>[178-183]</sup>, MWA<sup>[184]</sup>, and percutaneous laser ablation (PLA)<sup>[185]</sup>. The authors concluded that hepatic resection was superior to RFA in terms of survival, even if RFA might be associated with fewer complications and shorter hospital stay. Moreover, RFA was associated with better survival than PEI, whereas there was no evidence of significant differences between RFA and MWA or PLA.

In the study by Lee *et al.*<sup>[186]</sup>, patients undergoing surgical resection were younger and had better liver function reserve and PS than those receiving RFA. When accounting for these differences using propensity score analysis, RFA was superior to surgery for patients with small HCC and Child-Pugh Turcotte score of 5.

MWA relies on the direct application of an electromagnetic field, which causes dielectric hysteresis, leading to local tissue hyperthermia<sup>[187]</sup>. MWA is able to penetrate through several tissues, including those with high impedance<sup>[166,187]</sup>. High tissue temperatures can be achieved with MWA, with increased efficacy as compared to RFA<sup>[188]</sup>. Given the efficacy profile and the shorter time required to achieve ablation, the use of MWA has gradually increased for the treatment of both primary and metastatic tumors of the liver. Ding *et al.*<sup>[189,190]</sup> studied 198 patients with HCC, all in BCLC Stage A meeting Milan criteria and did not find any difference between RFA and MWA in terms of disease-free survival, cumulative survival, and complication rates. Similar results have been reported in other cohorts<sup>[184,191]</sup>.

PEI involves the direct instillation of ethanol into tumors, which results in coagulative necrosis. The technique is relatively simple and inexpensive. However, in clinical practice PEI is limited by poor and irregular distribution of ethanol within the tumor and diffusion into the adjacent normal tissues. Even

if some studies with PEI reported favorable outcomes after a long-term follow up (greater than 15 years), most evidences suggest that RFA is associated with better overall survival than PEI<sup>[192-194]</sup>.

The use of external beam radiation therapy (SBRT) in treatment of liver tumors has been traditionally limited by the overall low tolerance of liver tissue to radiation<sup>[195]</sup>. In fact, radiation produces tumoral killing by transferring energy within atoms, determining the generation of reactive oxygen species with subsequent direct and indirect DNA and cellular damage. The final step is the generation of double-strand DNA breaks, leading to tumor cell death. Radiation can achieve excellent tumor control when delivered to ablative doses<sup>[196]</sup>. Maximum dose is limited by the radiation tolerance of the surrounding normal liver tissue and adjacent organs. Particularly, radiation-induced liver disease is a complication typically manifesting with the triad of anicteric hepatomegaly, ascites, and elevation of alkaline phosphatase. Imaging techniques, breathing motion control and advances in radiation machines technology permit accurate localization of hepatic tumors and help directing radiation to the tumor while minimizing exposure of surrounding normal liver<sup>[197,198]</sup>. The size and number of lesions that can be targeted, as well as the radiation dose that can be delivered, depends on normal liver reserve and estimated risk of liver complications. As expected, patients with reduced liver function require dose reduction<sup>[199]</sup>. Similarly, patients with Child Pugh class B cirrhosis may require dose reduction, while those with Child Pugh class C cirrhosis are not usually eligible for this type of treatment.

Another radiation-based technique is high-dose rate (HDR) CT-guided interstitial brachytherapy<sup>[200-202]</sup>. Radiation is delivered using an iridium-192 source as a single fraction. The advantage of this technique is a greater protection of the surrounding healthy liver compared to external radiation techniques. A prospective phase II trial<sup>[203]</sup> showed encouraging results for patients with large tumors near the hilum, using average dose of 17 Gy. Mearini *et al.*<sup>[204]</sup> reported favorable outcomes of 35 patients with HCC (tumor size 5-12 cm), treated with HDR brachytherapy. At 12 mo, local control was 93% and no major toxicity was reported.

High-intensity focused ultrasound (HIFU) incorporates multiple ultrasound beams produced by piezoelectric or piezoceramic transducers directed into a three-dimensional focal point<sup>[205]</sup>. Ultrasound beams are both thermally ablative and cause cavitations to the underlying tissues. Coupling of the ultrasound source and the patient is achieved through a degassed water bath in order to have minimal reflection or absorption of the soundwaves prior to reaching the focal point. The patient is required to minimize movements during the procedure and the focal zone is shifted step by step to cover the area of interest for ablation. The safety and efficacy of HIFU was evaluated in several



studies<sup>[206-212]</sup>. Ng *et al.*<sup>[208]</sup> reported on a series of 49 patients with HCC (median tumor size 2.2 cm, range, 0.9-8 cm) and concluded that HIFU was effective for those who were not surgical candidates. He reported 1- and 3-year overall survival rates of 87.7% and 62.4%, respectively<sup>[209]</sup>. Similar data were published by Wu *et al.*<sup>[210]</sup>, with overall survival rates of 86.1%, 61.5%, and 35.3% at 6, 12, and 18 mo, respectively. Cheung *et al.*<sup>[205]</sup> reported on the outcomes of HIFU for the treatment of HCC before liver transplantation in 10 patients as compared to 29 patients who received transarterial chemoembolization and found that HIFU was effective (90% had complete response, 10% partial response), with none of the patients on the liver transplant list ( $n = 5$ ) dropping out<sup>[206]</sup>.

Irreversible electroporation (IRE) is an apparently non-thermal technique in which the direct placement of electrodes creates a pulsed direct current, inducing cytotoxicity in tumor cells by altering transmembrane potentials, which irreversibly disrupt cell membrane integrity<sup>[213]</sup>. IRE requires the position of at least two applicators in parallel to create ablation zones in the range of 1.5-2 cm per electrode pair<sup>[214]</sup>. The zone of ablation created by IRE is dependent on multiple factors<sup>[213,215]</sup>, such as electrode spacing and relative position, active tip length, pulse number and duration, and applied voltage. Because of these factors, IRE results more technically challenging than other locally ablative techniques. Moreover, the current generated by IRE causes whole-body muscle contractions and general anesthesia, requiring the use of neuromuscular blockage. In addition, IRE can induce cardiac arrhythmias, though this complication can be avoided with the use of cardiac synchronization of the administered pulses to the complete refractory period of the cardiac cycle<sup>[216]</sup>. IRE has a theoretical safety advantage as compared to other locally ablative techniques in the treatment of tumors close to structures susceptible to thermal injury, such as major bile ducts. In addition, because of the reduction in the "heat-sink" effect, IRE is potentially more effective for tumors next to major vessels, especially for smaller lesions, and showed excellent local tumor control at 3-6 mo, but high recurrence rates after 12-18 mo<sup>[215,217-220]</sup>.

Cryoablation involves the direct application of a cryoprobe into the tumor. The thermal contact with the tumor results in ice-crystal development and osmotic shock. One recognized advantage of cryoablation is that the zone of ablation is readily visible ("iceball") using CT scan, US, or MRI monitoring, allowing for precise targeting of the ablation area<sup>[221]</sup>. Moreover, multiple probes can be used simultaneously to create larger ablation zones and shorten procedural times. Despite the technical advantages of cryoablation, its use has been limited by the safety profile. Cryoshock is an uncommon but potentially life-threatening complication, characterized by thrombocytopenia, acute renal failure, adult respiratory distress syndrome and disseminated intravascular coagulopathy<sup>[221]</sup>. In

a meta-analysis comparing cryoablation to RFA in the treatment of unresectable HCC<sup>[222]</sup>, RFA was superior, particularly in terms of complication rates and local tumor recurrence.

Percutaneous laser ablation (PLA) involves the direct deposition of laser light *via* fiber-optic applicators to induce tissue hyperthermia in tumors. The thin flexible fiber-optic delivery fibers allow for safer and technically easier approaches to tumors<sup>[223]</sup>. Moreover, feedback and dose-planning systems allow a good control of ablative zones and consequently low complication rates. However, it has been suggested that PLA has some limitations in achieving complete tumor ablation as compared to other locally ablative therapies<sup>[185,224,225]</sup>.

HCC is preferentially supplied by the hepatic arterial inflow, while the normal parenchyma is largely supplied by the portal vein. The trans-arterial chemo-embolization (TACE) procedure is based on these blood supply dynamics. TACE consists in the placement of an intra-arterial catheter in the vessels supplying the tumor, to deliver high concentrations of a chemotherapeutic agent (*e.g.*, doxorubicin, cisplatin or mitomycin) along with an embolic agent, such as lipiodol gelatin sponge or polyvinyl alcohol particles, in order to achieve both targeted chemotherapy and reduction in arterial supply to the tumor.

Drug eluting beads TACE (DEB-TACE), are becoming largely popular because of the favorable safety profile. DEB-TACE delivers small beads, which have been saturated for several hours with chemotherapeutic drugs. The beads occlude the feeding vessels of HCC, while doxorubicin is progressively released, increasing chemotherapeutic concentrations locally and creating tumor necrosis. The choice of bead size, from 75 to 700  $\mu\text{m}$ , depends on tumor size and the preferred level of concentration within the treated volume. The best results are achieved when chemoembolization is performed selectively to segmental or subsegmental arteries feeding the tumor<sup>[226]</sup>. TACE is considered the standard of care for intermediate stage HCC without vascular invasion or metastases. In several randomized controlled trials, TACE was associated with partial response in 15%-62% of patients, and improved survival<sup>[227-233]</sup>. Some studies have suggested that complete tumor ischemia may stimulate angiogenesis, resulting in an increased susceptibility to tumor growth rather than suppression. It has been therefore suggested to maintain arterial patency both to prevent this pro-angiogenic effect and to permit repeated treatments<sup>[234-237]</sup>. Side effects associated with both DEB-TACE and TACE include nausea, vomiting and right upper quadrant pain (post-embolization syndrome), doxorubicin-related cardiac toxicity, bone marrow aplasia, hepatic abscesses, cholecystitis<sup>[229,231,238]</sup>. Two randomized controlled trials demonstrated improved side effect profiles<sup>[239,240]</sup> with equivalent survival rates<sup>[235,239]</sup> and longer time to progression for DEB-TACE in comparison with conventional TACE<sup>[240]</sup>. A

meta-analysis showed comparable tumor response rates<sup>[241]</sup>.

Radioembolization is a modestly invasive, fluoroscopically guided and microcatheter-based technique, using either yttrium-90 (Y-90) embedded non-biodegradable glass microspheres (25 ± 10 μm) or Y-90 embedded non-biodegradable glass resin-based microspheres (29-35 μm). Radioembolization exploits the preferential arterial blood supply of HCC by delivering radiotherapy directly to the tumor and preserving the normal liver parenchyma. In the target lesion, Y-90 delivers tumoricidal doses of a pure high-energy beta emitter. Because of the short tissue penetration and half-life, Y-90 is an ideal radioisotope for intra-arterial radiotherapy. Patients who have intermediate/advanced BCLC stage HCC and who are not candidates for TACE due to portal vein invasion are ideally candidate to radioembolization with Y-90<sup>[242-244]</sup>. Radioembolization represents a suitable alternative to chemotherapy for patients with advanced HCC<sup>[245]</sup>. Moreover, Y-90 radioembolization can be proposed as a bridge to liver transplantation<sup>[139,246,247]</sup>.

As for combinations therapies, one of the most studied approaches is represented by the association of RFA plus TACE. In fact, the decreased blood flow due to TACE reduces heat loss and improves the RFA margins. On the other hand, TACE enhances nearby control of satellite lesions<sup>[248]</sup>. Several meta-analyses have found that the combination of RFA and TACE is associated with improved survival in comparison with RFA alone, particularly for tumors larger than 3 cm in diameter<sup>[249-252]</sup>. Hyperthermia is able to potentiate the cytotoxic effect of radiation<sup>[253,254]</sup>. Additionally, in animal studies, the combined use of radiation and RFA resulted in improved tumor growth control compared with RFA alone<sup>[255,256]</sup>. The combination of thermal ablation with SBRT represents another encouraging option, even if more research is required to establish the most appropriate dosing and timing regimen<sup>[257]</sup>.

Sorafenib is a small-molecule multikinase inhibitor, which blocks Raf kinase, VEGF receptor and platelet derived growth factor receptor (PDGFR). In two randomized, double-blinded, controlled, phase III clinical trials, the SHARP (Sorafenib HCC Assessment Randomized Protocol trial) and the Asia-Pacific (conducted in the Asia-Pacific region), sorafenib was associated with improved progression-free and overall survival in patients with advanced unresectable HCC<sup>[258]</sup> and currently represents a therapeutic option for patients who are not candidates for curative treatment or TACE.

## CONCLUSION

HCC is a major global public health problem due to the rising incidence and high mortality in both developing and developed countries. An important point to be addressed is the promotion of preventive strategies, such as hepatitis B vaccination, and chronic hepatitis

B and C treatment, in order to cut down the number of patients who may develop cirrhosis and potentially progress to HCC. Early diagnosis is crucial for curative treatments. As a consequence, patients at risk of developing HCC should be regularly followed up to diagnose HCC in the initial stage. Surgical resection, RFA and liver transplantation are considered the cornerstones of curative therapy, while for patients with more advanced HCC recommended options include sorafenib and TACE.

Unfortunately, most evidence comes from case series and retrospective studies. There is a need for larger, multicenter, randomized studies in order to define the most appropriate, evidence-based therapeutic approach to patients with HCC.

## REFERENCES

- 1 **National Cancer Institute.** Surveillance Research Program, National Cancer Institute. Fast stats: an interactive tool for access to SEER cancer statistics. Available from: URL: <http://surveillance.cancer.gov/>
- 2 **Jemal A, Bray F, Center MM, Ferlay J, Ward E, Forman D.** Global cancer statistics. *CA Cancer J Clin* 2011; **61**: 69-90 [PMID: 21296855 DOI: 10.3322/caac.20107]
- 3 **El-Serag HB, Mason AC.** Risk factors for the rising rates of primary liver cancer in the United States. *Arch Intern Med* 2000; **160**: 3227-3230 [PMID: 11088082 DOI: 10.1001/archinte.160.21.3227]
- 4 **Tsukuma H, Hiyama T, Tanaka S, Nakao M, Yabuuchi T, Kitamura T, Nakanishi K, Fujimoto I, Inoue A, Yamazaki H.** Risk factors for hepatocellular carcinoma among patients with chronic liver disease. *N Engl J Med* 1993; **328**: 1797-1801 [PMID: 7684822 DOI: 10.1056/NEJM199306243282501]
- 5 **El-Serag HB, Davila JA, Petersen NJ, McGlynn KA.** The continuing increase in the incidence of hepatocellular carcinoma in the United States: an update. *Ann Intern Med* 2003; **139**: 817-823 [PMID: 14623619 DOI: 10.7326/0003-4819-139-10-200311180-0009]
- 6 **Marrero JA, Hussain HK, Nghiem HV, Umar R, Fontana RJ, Lok AS.** Improving the prediction of hepatocellular carcinoma in cirrhotic patients with an arterially-enhancing liver mass. *Liver Transpl* 2005; **11**: 281-289 [PMID: 15719410 DOI: 10.1002/lt.20357]
- 7 **Bruix J, Sherman M.** Management of hepatocellular carcinoma: an update. *Hepatology* 2011; **53**: 1020-1022 [PMID: 21374666 DOI: 10.1002/hep.24199]
- 8 **Choi BI.** Hepatocarcinogenesis in liver cirrhosis: imaging diagnosis. *J Korean Med Sci* 1998; **13**: 103-116 [PMID: 9610609 DOI: 10.3346/jkms.1998.13.2.103]
- 9 **Eskesen AN, Bjoro K, Aandahl EM, Line PD, Melum E.** Low use of surveillance and early diagnosis of hepatocellular carcinoma in Norway--a population-based cohort study. *Cancer Epidemiol* 2014; **38**: 741-747 [PMID: 25454262 DOI: 10.1016/j.canep.2014.10.005]
- 10 **Chen MH, Yan K, Yang W, Gao W, Dai Y, Huo L, Zhang H, Huang XF.** [Long term (5 years) outcome of radiofrequency ablation for hepatocellular carcinoma in 256 cases]. *Beijing Daxue Xuebao* 2005; **37**: 671-672 [PMID: 16378128]
- 11 **Matsui O, Kobayashi S, Sanada J, Kouda W, Ryu Y, Kozaka K, Kitao A, Nakamura K, Gabata T.** Hepatocellular nodules in liver cirrhosis: hemodynamic evaluation (angiography-assisted CT) with special reference to multi-step hepatocarcinogenesis. *Abdom Imaging* 2011; **36**: 264-272 [PMID: 21267562 DOI: 10.1007/s00261-011-9685-1]
- 12 **Matsui O, Kadoya M, Kameyama T, Yoshikawa J, Takashima T, Nakanuma Y, Unoura M, Kobayashi K, Izumi R, Ida M.** Benign and malignant nodules in cirrhotic livers: distinction based on blood supply. *Radiology* 1991; **178**: 493-497 [PMID: 1846240]

- DOI: 10.1148/radiology.178.2.1846240]
- 13 **Matsui O**, Ueda K, Kobayashi S, Sanada J, Terayama N, Gabata T, Minami M, Kawamori Y, Nakanuma Y. Intra- and perinodular hemodynamics of hepatocellular carcinoma: CT observation during intra-arterial contrast injection. *Abdom Imaging* 2002; **27**: 147-156 [PMID: 11847574]
  - 14 **Hayashi M**, Matsui O, Ueda K, Kawamori Y, Gabata T, Kadoya M. Progression to hypervascular hepatocellular carcinoma: correlation with intranodular blood supply evaluated with CT during intraarterial injection of contrast material. *Radiology* 2002; **225**: 143-149 [PMID: 12354998 DOI: 10.1148/radiol.2251011298]
  - 15 **Wu W**, Chen MH, Sun M, Yan K, Yang W, Li JY. Contrast-enhanced ultrasound of hepatocarcinogenesis in liver cirrhosis. *Chin Med J (Engl)* 2012; **125**: 3104-3109 [PMID: 22932189 DOI: 10.3978/j.issn.1000-9604.2015.02.06]
  - 16 **Kim TK**, Jang HJ. Contrast-enhanced ultrasound in the diagnosis of nodules in liver cirrhosis. *World J Gastroenterol* 2014; **20**: 3590-3596 [PMID: 24707142 DOI: 10.3748/wjg.v20.i13.3590]
  - 17 **Isozaki T**, Numata K, Kiba T, Hara K, Morimoto M, Sakaguchi T, Sekihara H, Kubota T, Shimada H, Morizane T, Tanaka K. Differential diagnosis of hepatic tumors by using contrast enhancement patterns at US. *Radiology* 2003; **229**: 798-805 [PMID: 14563903 DOI: 10.1148/radiol.2293020858]
  - 18 **Numata K**, Luo W, Morimoto M, Kondo M, Kunishi Y, Sasaki T, Nozaki A, Tanaka K. Contrast enhanced ultrasound of hepatocellular carcinoma. *World J Radiol* 2010; **2**: 68-82 [PMID: 21160920 DOI: 10.4329/wjr.v2.i2.68]
  - 19 **International Working Party**. Terminology of nodular hepatocellular lesions. *Hepatology* 1995; **22**: 983-993 [PMID: 7657307 DOI: 10.1002/hep.1840220341]
  - 20 **Quaia E**, Calliada F, Bertolotto M, Rossi S, Garioni L, Rosa L, Pozzi-Mucelli R. Characterization of focal liver lesions with contrast-specific US modes and a sulfur hexafluoride-filled microbubble contrast agent: diagnostic performance and confidence. *Radiology* 2004; **232**: 420-430 [PMID: 15286314 DOI: 10.1148/radiol.2322031401]
  - 21 **Wen YL**, Kudo M, Zheng RQ, Ding H, Zhou P, Minami Y, Chung H, Kitano M, Kawasaki T, Maekawa K. Characterization of hepatic tumors: value of contrast-enhanced coded phase-inversion harmonic angio. *AJR Am J Roentgenol* 2004; **182**: 1019-1026 [PMID: 15039180 DOI: 10.2214/ajr.182.4.1821019]
  - 22 **Loria F**, Loria G, Basile S, Crea G, Frosina L, Di Carlo I. Contrast-enhanced ultrasound appearances of enhancement patterns of intrahepatic cholangiocarcinoma: correlation with pathological findings. *Updates Surg* 2014; **66**: 135-143 [PMID: 24802031 DOI: 10.1007/s13304-014-0251-6]
  - 23 **Kim TK**, Choi BI, Han JK, Hong HS, Park SH, Moon SG. Hepatic tumors: contrast agent-enhancement patterns with pulse-inversion harmonic US. *Radiology* 2000; **216**: 411-417 [PMID: 10924562 DOI: 10.1148/radiology.216.2.r00j121411]
  - 24 **Wilson SR**, Burns PN, Muradali D, Wilson JA, Lai X. Harmonic hepatic US with microbubble contrast agent: initial experience showing improved characterization of hemangioma, hepatocellular carcinoma, and metastasis. *Radiology* 2000; **215**: 153-161 [PMID: 10751481 DOI: 10.1148/radiology.215.1.r00ap08153]
  - 25 **Quaia E**, Degobbi F, Tona G, Mosconi E, Bertolotto M, Pozzi Mucelli R. [Differential patterns of contrast enhancement in different focal liver lesions after injection of the microbubble US contrast agent SonoVue]. *Radiol Med* 2004; **107**: 155-165 [PMID: 15031681]
  - 26 **Catalano O**, Lobianco R, Cusati B, Siani A. Hepatocellular carcinoma: spectrum of contrast-enhanced gray-scale harmonic sonography findings. *Abdom Imaging* 2004; **29**: 341-347 [PMID: 15354343 DOI: 10.1007/s00261-003-0107-x]
  - 27 **Wu W**, Chen M, Yan K, Dai Y, Yin S, Yang W, Fan Z. Evaluation of contrast-enhanced ultrasound for diagnosis of dysplastic nodules with a focus of hepatocellular carcinoma in liver cirrhosis patients. *Chin J Cancer Res* 2015; **27**: 83-89 [PMID: 25717230]
  - 28 **Kim SH**, Choi BI, Lee JY, Kim SJ, So YH, Eun HW, Lee JM, Han JK. Diagnostic accuracy of multi-/single-detector row CT and contrast-enhanced MRI in the detection of hepatocellular carcinomas meeting the milan criteria before liver transplantation. *Intervirology* 2008; **51** Suppl 1: 52-60 [PMID: 18544949 DOI: 10.1159/000122598]
  - 29 **Ariff B**, Lloyd CR, Khan S, Shariff M, Thillainayagam AV, Bansi DS, Khan SA, Taylor-Robinson SD, Lim AK. Imaging of liver cancer. *World J Gastroenterol* 2009; **15**: 1289-1300 [PMID: 19294758]
  - 30 **Ito K**. Hepatocellular carcinoma: conventional MRI findings including gadolinium-enhanced dynamic imaging. *Eur J Radiol* 2006; **58**: 186-199 [PMID: 16413154 DOI: 10.1016/j.ejrad.2005.11.039]
  - 31 **Chanyaputhipong J**, Low SC, Chow PK. Gadoxetate Acid-Enhanced MR Imaging for HCC: A Review for Clinicians. *Int J Hepatol* 2011; **2011**: 489342 [PMID: 21994860 DOI: 10.4061/2011/489342]
  - 32 **Willatt JM**, Hussain HK, Adusumilli S, Marrero JA. MR Imaging of hepatocellular carcinoma in the cirrhotic liver: challenges and controversies. *Radiology* 2008; **247**: 311-330 [PMID: 18430871 DOI: 10.1148/radiol.2472061331]
  - 33 **Burrell M**, Llovet JM, Ayuso C, Iglesias C, Sala M, Miquel R, Caralt T, Ayuso JR, Solé M, Sanchez M, Brú C, Bruix J; Barcelona Clinic Liver Cancer Group. MRI angiography is superior to helical CT for detection of HCC prior to liver transplantation: an explant correlation. *Hepatology* 2003; **38**: 1034-1042 [PMID: 14512891 DOI: 10.1053/jhep.2003.50409]
  - 34 **Kim YK**, Kim CS, Chung GH, Han YM, Lee SY, Chon SB, Lee JM. Comparison of gadobenate dimeglumine-enhanced dynamic MRI and 16-MDCT for the detection of hepatocellular carcinoma. *AJR Am J Roentgenol* 2006; **186**: 149-157 [PMID: 16357395 DOI: 10.2214/ajr.186.4\_supplement.a149]
  - 35 **Ebara M**, Ohto M, Watanabe Y, Kimura K, Saisho H, Tsuchiya Y, Okuda K, Arimizu N, Kondo F, Ikehira H. Diagnosis of small hepatocellular carcinoma: correlation of MR imaging and tumor histologic studies. *Radiology* 1986; **159**: 371-377 [PMID: 3008213 DOI: 10.1148/radiology.159.2.3008213]
  - 36 **Krinsky GA**, Lee VS, Theise ND, Weinreb JC, Morgan GR, Diflo T, John D, Teperman LW, Goldenberg AS. Transplantation for hepatocellular carcinoma and cirrhosis: sensitivity of magnetic resonance imaging. *Liver Transpl* 2002; **8**: 1156-1164 [PMID: 12474156 DOI: 10.1053/jlts.2002.35670]
  - 37 **Kim JI**, Lee JM, Choi JY, Kim YK, Kim SH, Lee JY, Han JK, Choi BI. The value of gadobenate dimeglumine-enhanced delayed phase MR imaging for characterization of hepatocellular nodules in the cirrhotic liver. *Invest Radiol* 2008; **43**: 202-210 [PMID: 18301317 DOI: 10.1097/RLI.0b013e31815d6929]
  - 38 **Kim SH**, Kim SH, Lee J, Kim MJ, Jeon YH, Park Y, Choi D, Lee WJ, Lim HK. Gadoteric acid-enhanced MRI versus triple-phase MDCT for the preoperative detection of hepatocellular carcinoma. *AJR Am J Roentgenol* 2009; **192**: 1675-1681 [PMID: 19457834 DOI: 10.2214/AJR.08.1262]
  - 39 **Ho CL**, Yu SC, Yeung DW. 11C-acetate PET imaging in hepatocellular carcinoma and other liver masses. *J Nucl Med* 2003; **44**: 213-221 [PMID: 12571212]
  - 40 **Delbeke D**, Pinson CW. 11C-acetate: a new tracer for the evaluation of hepatocellular carcinoma. *J Nucl Med* 2003; **44**: 222-223 [PMID: 12571213]
  - 41 **Park JW**, Kim JH, Kim SK, Kang KW, Park KW, Choi JI, Lee WJ, Kim CM, Nam BH. A prospective evaluation of 18F-FDG and 11C-acetate PET/CT for detection of primary and metastatic hepatocellular carcinoma. *J Nucl Med* 2008; **49**: 1912-1921 [PMID: 18997056 DOI: 10.2967/jnumed.108.055087]
  - 42 **Sacks A**, Peller PJ, Surasi DS, Chatburn L, Mercier G, Subramaniam RM. Value of PET/CT in the management of primary hepatobiliary tumors, part 2. *AJR Am J Roentgenol* 2011; **197**: W260-W265 [PMID: 21785051 DOI: 10.2214/AJR.11.6995]
  - 43 **Karhunen PJ**. Benign hepatic tumours and tumour like conditions in men. *J Clin Pathol* 1986; **39**: 183-188 [PMID: 3950039 DOI: 10.1136/jcp.39.2.183]
  - 44 **Delbeke D**, Martin WH, Sandler MP, Chapman WC, Wright JK, Pinson

- CW. Evaluation of benign vs malignant hepatic lesions with positron emission tomography. *Arch Surg* 1998; **133**: 510-515; discussion 515-516 [PMID: 9605913 DOI: 10.1001/archsurg.133.5.510]
- 45 **Gibbs JF**, Litwin AM, Kahlenberg MS. Contemporary management of benign liver tumors. *Surg Clin North Am* 2004; **84**: 463-480 [PMID: 15062656 DOI: 10.1016/j.suc.2003.11.003]
- 46 **Chen S**, Ho C, Feng D, Chi Z. Tracer kinetic modeling of 11C-acetate applied in the liver with positron emission tomography. *IEEE Trans Med Imaging* 2004; **23**: 426-432 [PMID: 15084068 DOI: 10.1109/TMI.2004.824229]
- 47 **Huo L**, Guo J, Dang Y, Lv J, Zheng Y, Li F, Xie Q, Chen X. Kinetic analysis of dynamic (11)C-acetate PET/CT imaging as a potential method for differentiation of hepatocellular carcinoma and benign liver lesions. *Theranostics* 2015; **5**: 371-377 [PMID: 25699097 DOI: 10.7150/thno.10760]
- 48 **Bruix J**, Sherman M. Management of hepatocellular carcinoma. *Hepatology* 2005; **42**: 1208-1236 [PMID: 16250051 DOI: 10.1002/hep.20933]
- 49 **European Association For The Study Of The Liver**; European Organisation For Research And Treatment Of Cancer. EASL-EORTC clinical practice guidelines: management of hepatocellular carcinoma. *J Hepatol* 2012; **56**: 908-943 [PMID: 22424438 DOI: 10.1016/j.jhep.2011.12.001]
- 50 **Chen JG**, Parkin DM, Chen QG, Lu JH, Shen QJ, Zhang BC, Zhu YR. Screening for liver cancer: results of a randomised controlled trial in Qidong, China. *J Med Screen* 2003; **10**: 204-209 [PMID: 14738659 DOI: 10.1258/096914103771773320]
- 51 **McMahon BJ**, Bulkow L, Harpster A, Snowball M, Lanier A, Sacco F, Dunaway E, Williams J. Screening for hepatocellular carcinoma in Alaska natives infected with chronic hepatitis B: a 16-year population-based study. *Hepatology* 2000; **32**: 842-846 [PMID: 11003632 DOI: 10.1053/jhep.2000.17914]
- 52 **Wan HG**, Xu H, Gu YM, Wang H, Xu W, Zu MH. Comparison osteopontin vs AFP for the diagnosis of HCC: a meta-analysis. *Clin Res Hepatol Gastroenterol* 2014; **38**: 706-714 [PMID: 25034355 DOI: 10.1016/j.clinre.2014.06.008]
- 53 **Xu C**, Yan Z, Zhou L, Wang Y. A comparison of glypican-3 with alpha-fetoprotein as a serum marker for hepatocellular carcinoma: a meta-analysis. *J Cancer Res Clin Oncol* 2013; **139**: 1417-1424 [PMID: 23743582 DOI: 10.1007/s00432-013-1458-5]
- 54 **Richardson P**, Duan Z, Kramer J, Davila JA, Tyson GL, El-Serag HB. Determinants of serum alpha-fetoprotein levels in hepatitis C-infected patients. *Clin Gastroenterol Hepatol* 2012; **10**: 428-433 [PMID: 22155556 DOI: 10.1016/j.cgh.2011.11.025]
- 55 **Mossad NA**, Mahmoud EH, Osman EA, Mahmoud SH, Shousha HI. Evaluation of squamous cell carcinoma antigen-immunoglobulin M complex (SCCA-IGM) and alpha-L-fucosidase (AFU) as novel diagnostic biomarkers for hepatocellular carcinoma. *Tumour Biol* 2014; **35**: 11559-11564 [PMID: 25129443 DOI: 10.1007/s13277-014-2467-y]
- 56 **Bertino G**, Ardiri A, Malaguarnera M, Malaguarnera G, Bertino N, Calvagno GS. Hepatocellular carcinoma serum markers. *Semin Oncol* 2012; **39**: 410-433 [PMID: 22846859 DOI: 10.1053/j.seminoncol.2012.05.001]
- 57 **Zhang J**, Zhao Y, Yang Q. Sensitivity and specificity of Dickkopf-1 protein in serum for diagnosing hepatocellular carcinoma: a meta-analysis. *Int J Biol Markers* 2014; **29**: e403-e410 [PMID: 24980448 DOI: 10.5301/ijbm.5000101]
- 58 **Kumada T**, Toyoda H, Tada T, Kiriya S, Tanikawa M, Hisanaga Y, Kanamori A, Tanaka J, Kagebayashi C, Satomura S. High-sensitivity Lens culinaris agglutinin-reactive alpha-fetoprotein assay predicts early detection of hepatocellular carcinoma. *J Gastroenterol* 2014; **49**: 555-563 [PMID: 24057163 DOI: 10.1007/s00535-013-0883-1]
- 59 **Toyoda H**, Kumada T, Tada T, Kaneoka Y, Maeda A, Kanke F, Satomura S. Clinical utility of highly sensitive Lens culinaris agglutinin-reactive alpha-fetoprotein in hepatocellular carcinoma patients with alpha-fetoprotein <math>\leq 20\text{ ng/mL}</math>. *Cancer Sci* 2011; **102**: 1025-1031 [PMID: 21244578 DOI: 10.1111/j.1349-7006.2011.01875.x]
- 60 **Witjes CD**, van Aalten SM, Steyerberg EW, Borsboom GJ, de Man RA, Verhoef C, Ijzermans JN. Recently introduced biomarkers for screening of hepatocellular carcinoma: a systematic review and meta-analysis. *Hepatol Int* 2013; **7**: 59-64 [PMID: 23519638 DOI: 10.1007/s12072-012-9374-3]
- 61 **Marrero JA**, Romano PR, Nikolaeva O, Steel L, Mehta A, Fimmel CJ, Comunale MA, D'Amelio A, Lok AS, Block TM. GP73, a resident Golgi glycoprotein, is a novel serum marker for hepatocellular carcinoma. *J Hepatol* 2005; **43**: 1007-1012 [PMID: 16137783 DOI: 10.1016/j.jhep.2005.05.028]
- 62 **Mao Y**, Yang H, Xu H, Lu X, Sang X, Du S, Zhao H, Chen W, Xu Y, Chi T, Yang Z, Cai J, Li H, Chen J, Zhong S, Mohanti SR, Lopez-Soler R, Millis JM, Huang J, Zhang H. Golgi protein 73 (GOLPH2) is a valuable serum marker for hepatocellular carcinoma. *Gut* 2010; **59**: 1687-1693 [PMID: 20876776 DOI: 10.1136/gut.2010.214916]
- 63 **Porta C**, De Amici M, Quaglini S, Paglino C, Tagliani F, Boncimino A, Moratti R, Corazza GR. Circulating interleukin-6 as a tumor marker for hepatocellular carcinoma. *Ann Oncol* 2008; **19**: 353-358 [PMID: 17962206 DOI: 10.1093/annonc/mdm448]
- 64 **Hsia CY**, Huo TL, Chiang SY, Lu MF, Sun CL, Wu JC, Lee PC, Chi CW, Lui WY, Lee SD. Evaluation of interleukin-6, interleukin-10 and human hepatocyte growth factor as tumor markers for hepatocellular carcinoma. *Eur J Surg Oncol* 2007; **33**: 208-212 [PMID: 17140760 DOI: 10.1016/j.ejso.2006.10.036]
- 65 **Giannelli G**, Fransvea E, Trerotoli P, Beaugrand M, Marinosci F, Lupo L, Nkontchou G, Dentico P, Antonaci S. Clinical validation of combined serological biomarkers for improved hepatocellular carcinoma diagnosis in 961 patients. *Clin Chim Acta* 2007; **383**: 147-152 [PMID: 17582392 DOI: 10.1016/j.cca.2007.05.014]
- 66 **Sha Sha F**, Ai min LI, Rong LI, Feng sheng C, Jun yi Z, Rong cheng L. IL 17 expression increased as a diagnostic marker in the serum of hepatocellular carcinoma patients. *J Nat Sci Human Norm Univ* 2014; **37**: 19-23
- 67 **Liu J**, Zhou G, Lu W. Plasma interleukin 17 in the diagnosis of hepatocellular carcinoma: a retrospective study of 39 cases. *J Cancer Res Ther* 2014; **10** Suppl: 304-306 [PMID: 25693940 DOI: 10.4103/0973-1482.151537]
- 68 **Ertle JM**, Heider D, Wichert M, Keller B, Kueper R, Hilgard P, Gerken G, Schlaak JF. A combination of  $\alpha$ -fetoprotein and des- $\gamma$ -carboxy prothrombin is superior in detection of hepatocellular carcinoma. *Digestion* 2013; **87**: 121-131 [PMID: 23406785 DOI: 10.1159/000346080]
- 69 **Hadziyannis E**, Sialevris K, Georgiou A, Koskinas J. Analysis of serum  $\alpha$ -fetoprotein-L3% and des- $\gamma$  carboxyprothrombin markers in cases with misleading hepatocellular carcinoma total  $\alpha$ -fetoprotein levels. *Oncol Rep* 2013; **29**: 835-839 [PMID: 23174906 DOI: 10.3892/or.2012.2147]
- 70 **Wang M**, Mehta A, Block TM, Marrero J, Di Bisceglie AM, Devarajan K. A comparison of statistical methods for the detection of hepatocellular carcinoma based on serum biomarkers and clinical variables. *BMC Med Genomics* 2013; **6** Suppl 3: S9 [PMID: 24564861 DOI: 10.1186/1755-8794-6-S3-S9]
- 71 **Johnson PJ**, Pirrie SJ, Cox TF, Berhane S, Teng M, Palmer D, Morse J, Hull D, Patman G, Kagebayashi C, Hussain S, Graham J, Reeves H, Satomura S. The detection of hepatocellular carcinoma using a prospectively developed and validated model based on serological biomarkers. *Cancer Epidemiol Biomarkers Prev* 2014; **23**: 144-153 [PMID: 24220911 DOI: 10.1158/1055-9965.EPI-13-0870]
- 72 **Aravalli RN**, Steer CJ, Cressman EN. Molecular mechanisms of hepatocellular carcinoma. *Hepatology* 2008; **48**: 2047-2063 [PMID: 19003900 DOI: 10.1002/hep.22580]
- 73 **Liu CC**, Wang YH, Chuang EY, Tsai MH, Chuang YH, Lin CL, Liu CJ, Hsiao BY, Lin SM, Liu LY, Yu MW. Identification of a liver cirrhosis signature in plasma for predicting hepatocellular carcinoma risk in a population-based cohort of hepatitis B carriers. *Mol Carcinog* 2014; **53**: 58-66 [PMID: 22911910 DOI: 10.1002/mc.21952]
- 74 **Shi M**, Chen MS, Sekar K, Tan CK, Ooi LL, Hui KM. A blood-based three-gene signature for the non-invasive detection of early

- human hepatocellular carcinoma. *Eur J Cancer* 2014; **50**: 928-936 [PMID: 24332572 DOI: 10.1016/j.ejca.2013.11.026]
- 75 **Wurmbach E**, Chen YB, Khitrov G, Zhang W, Roayaie S, Schwartz M, Fiel I, Thung S, Mazzaferro V, Bruix J, Bottinger E, Friedman S, Waxman S, Llovet JM. Genome-wide molecular profiles of HCV-induced dysplasia and hepatocellular carcinoma. *Hepatology* 2007; **45**: 938-947 [PMID: 17393520 DOI: 10.1002/hep.21622]
- 76 **Nam SW**, Park JY, Ramasamy A, Shevade S, Islam A, Long PM, Park CK, Park SE, Kim SY, Lee SH, Park WS, Yoo NJ, Liu ET, Miller LD, Lee JY. Molecular changes from dysplastic nodule to hepatocellular carcinoma through gene expression profiling. *Hepatology* 2005; **42**: 809-818 [PMID: 16175600 DOI: 10.1002/hep.20878]
- 77 **Llovet JM**, Chen Y, Wurmbach E, Roayaie S, Fiel MI, Schwartz M, Thung SN, Khitrov G, Zhang W, Villanueva A, Battiston C, Mazzaferro V, Bruix J, Waxman S, Friedman SL. A molecular signature to discriminate dysplastic nodules from early hepatocellular carcinoma in HCV cirrhosis. *Gastroenterology* 2006; **131**: 1758-1767 [PMID: 17087938 DOI: 10.1053/j.gastro.2006.09.014]
- 78 **Sakamoto M**, Mori T, Masugi Y, Effendi K, Rie I, Du W. Candidate molecular markers for histological diagnosis of early hepatocellular carcinoma. *Intervirology* 2008; **51** Suppl 1: 42-45 [PMID: 18544947 DOI: 10.1159/000122603]
- 79 **Minguez B**, Lachenmayer A. Diagnostic and prognostic molecular markers in hepatocellular carcinoma. *Dis Markers* 2011; **31**: 181-190 [PMID: 22045404 DOI: 10.3233/DMA-2011-0841]
- 80 **Berindan-Neagoe I**, Monroig Pdel C, Pasculli B, Calin GA. MicroRNAome genome: a treasure for cancer diagnosis and therapy. *CA Cancer J Clin* 2014; **64**: 311-336 [PMID: 25104502 DOI: 10.3322/caac.21244]
- 81 **Link A**, Kupcinskis J, Wex T, Malfertheiner P. Macro-role of microRNA in gastric cancer. *Dig Dis* 2012; **30**: 255-267 [PMID: 22722550 DOI: 10.1159/000336919]
- 82 **Arroyo JD**, Chevillet JR, Kroh EM, Ruf IK, Pritchard CC, Gibson DF, Mitchell PS, Bennett CF, Pogosova-Agadjanyan EL, Stirewalt DL, Tait JF, Tewari M. Argonaute2 complexes carry a population of circulating microRNAs independent of vesicles in human plasma. *Proc Natl Acad Sci USA* 2011; **108**: 5003-5008 [PMID: 21383194 DOI: 10.1073/pnas.1019055108]
- 83 **Link A**, Goel A. MicroRNA in gastrointestinal cancer: a step closer to reality. *Adv Clin Chem* 2013; **62**: 221-268 [PMID: 24772669 DOI: 10.1016/B978-0-12-800096-0.00006-8]
- 84 **Redis RS**, Calin S, Yang Y, You MJ, Calin GA. Cell-to-cell miRNA transfer: from body homeostasis to therapy. *Pharmacol Ther* 2012; **136**: 169-174 [PMID: 22903157 DOI: 10.1016/j.pharmthera.2012.08.003]
- 85 **Mitchell PS**, Parkin RK, Kroh EM, Fritz BR, Wyman SK, Pogosova-Agadjanyan EL, Peterson A, Noteboom J, O'Briant KC, Allen A, Lin DW, Urban N, Drescher CW, Knudsen BS, Stirewalt DL, Gentleman R, Vessella RL, Nelson PS, Martin DB, Tewari M. Circulating microRNAs as stable blood-based markers for cancer detection. *Proc Natl Acad Sci USA* 2008; **105**: 10513-10518 [PMID: 18663219 DOI: 10.1073/pnas.0804549105]
- 86 **Chen X**, Ba Y, Ma L, Cai X, Yin Y, Wang K, Guo J, Zhang Y, Chen J, Guo X, Li Q, Li X, Wang W, Zhang Y, Wang J, Jiang X, Xiang Y, Xu C, Zheng P, Zhang J, Li R, Zhang H, Shang X, Gong T, Ning G, Wang J, Zen K, Zhang J, Zhang CY. Characterization of microRNAs in serum: a novel class of biomarkers for diagnosis of cancer and other diseases. *Cell Res* 2008; **18**: 997-1006 [PMID: 18766170 DOI: 10.1038/cr.2008.282]
- 87 **Weber JA**, Baxter DH, Zhang S, Huang DY, Huang KH, Lee MJ, Galas DJ, Wang K. The microRNA spectrum in 12 body fluids. *Clin Chem* 2010; **56**: 1733-1741 [PMID: 20847327 DOI: 10.1373/clinchem.2010.147405]
- 88 **Link A**, Balaguer F, Shen Y, Nagasaka T, Lozano JJ, Boland CR, Goel A. Fecal MicroRNAs as novel biomarkers for colon cancer screening. *Cancer Epidemiol Biomarkers Prev* 2010; **19**: 1766-1774 [PMID: 20551304 DOI: 10.1158/1055-9965.EPI-10-0027]
- 89 **Lu J**, Getz G, Miska EA, Alvarez-Saavedra E, Lamb J, Peck D, Sweet-Cordero A, Ebert BL, Mak RH, Ferrando AA, Downing JR, Jacks T, Horvitz HR, Golub TR. MicroRNA expression profiles classify human cancers. *Nature* 2005; **435**: 834-838 [PMID: 15944708 DOI: 10.1038/nature03702]
- 90 **Volinia S**, Calin GA, Liu CG, Ambs S, Cimmino A, Petrocca F, Visone R, Iorio M, Roldo C, Ferracin M, Prueitt RL, Yanaihara N, Lanza G, Scarpa A, Vecchione A, Negrini M, Harris CC, Croce CM. A microRNA expression signature of human solid tumors defines cancer gene targets. *Proc Natl Acad Sci USA* 2006; **103**: 2257-2261 [PMID: 16461460 DOI: 10.1073/pnas.0510565103]
- 91 **Hou J**, Lin L, Zhou W, Wang Z, Ding G, Dong Q, Qin L, Wu X, Zheng Y, Yang Y, Tian W, Zhang Q, Wang C, Zhang Q, Zhuang SM, Zheng L, Liang A, Tao W, Cao X. Identification of miRNomes in human liver and hepatocellular carcinoma reveals miR-199a/b-3p as therapeutic target for hepatocellular carcinoma. *Cancer Cell* 2011; **19**: 232-243 [PMID: 21316602 DOI: 10.1016/j.ccr.2011.01.001]
- 92 **Murakami Y**, Yasuda T, Saigo K, Urashima T, Toyoda H, Okanoue T, Shimotohno K. Comprehensive analysis of microRNA expression patterns in hepatocellular carcinoma and non-tumorous tissues. *Oncogene* 2006; **25**: 2537-2545 [PMID: 16331254 DOI: 10.1038/sj.onc.1209283]
- 93 **Toffanin S**, Hoshida Y, Lachenmayer A, Villanueva A, Cabellos L, Minguez B, Savic R, Ward SC, Thung S, Chiang DY, Alsinet C, Tovar V, Roayaie S, Schwartz M, Bruix J, Waxman S, Friedman SL, Golub T, Mazzaferro V, Llovet JM. MicroRNA-based classification of hepatocellular carcinoma and oncogenic role of miR-517a. *Gastroenterology* 2011; **140**: 1618-1628.e16 [PMID: 21324318 DOI: 10.1053/j.gastro.2011.02.009]
- 94 **Giordano S**, Columbano A. MicroRNAs: new tools for diagnosis, prognosis, and therapy in hepatocellular carcinoma? *Hepatology* 2013; **57**: 840-847 [PMID: 23081718 DOI: 10.1002/hep.26095]
- 95 **Li LM**, Hu ZB, Zhou ZX, Chen X, Liu FY, Zhang JF, Shen HB, Zhang CY, Zen K. Serum microRNA profiles serve as novel biomarkers for HBV infection and diagnosis of HBV-positive hepatocarcinoma. *Cancer Res* 2010; **70**: 9798-9807 [PMID: 21098710 DOI: 10.1158/0008-5472.CAN-10-1001]
- 96 **Zhou J**, Yu L, Gao X, Hu J, Wang J, Dai Z, Wang JF, Zhang Z, Lu S, Huang X, Wang Z, Qiu S, Wang X, Yang G, Sun H, Tang Z, Wu Y, Zhu H, Fan J. Plasma microRNA panel to diagnose hepatitis B virus-related hepatocellular carcinoma. *J Clin Oncol* 2011; **29**: 4781-4788 [PMID: 22105822 DOI: 10.1200/JCO.2011.38.2697]
- 97 **Tomimaru Y**, Eguchi H, Nagano H, Wada H, Kobayashi S, Marubashi S, Tanemura M, Tomokuni A, Takemasa I, Umeshita K, Kanto T, Doki Y, Mori M. Circulating microRNA-21 as a novel biomarker for hepatocellular carcinoma. *J Hepatol* 2012; **56**: 167-175 [PMID: 21749846 DOI: 10.1016/j.jhep.2011.04.026]
- 98 **Xu J**, Wu C, Che X, Wang L, Yu D, Zhang T, Huang L, Li H, Tan W, Wang C, Lin D. Circulating microRNAs, miR-21, miR-122, and miR-223, in patients with hepatocellular carcinoma or chronic hepatitis. *Mol Carcinog* 2011; **50**: 136-142 [PMID: 21229610 DOI: 10.1002/mc.20712]
- 99 **Qi P**, Cheng SQ, Wang H, Li N, Chen YF, Gao CF. Serum microRNAs as biomarkers for hepatocellular carcinoma in Chinese patients with chronic hepatitis B virus infection. *PLoS One* 2011; **6**: e28486 [PMID: 22174818 DOI: 10.1371/journal.pone.0028486]
- 100 **Bührer V**, Waidmann O, Friedrich-Rust M, Forestier N, Susser S, Haupenthal J, Welker M, Shi Y, Peveling-Oberhag J, Polta A, von Wagner M, Radeke HH, Sarrazin C, Trojan J, Zeuzem S, Kronenberger B, Piiper A. Serum microRNA-21 as marker for necroinflammation in hepatitis C patients with and without hepatocellular carcinoma. *PLoS One* 2011; **6**: e26971 [PMID: 22066022 DOI: 10.1371/journal.pone.0026971]
- 101 **Tan Y**, Ge G, Pan T, Wen D, Gan J. A pilot study of serum microRNAs panel as potential biomarkers for diagnosis of nonalcoholic fatty liver disease. *PLoS One* 2014; **9**: e105192 [PMID: 25141008 DOI: 10.1371/journal.pone.0105192]
- 102 **Schütte K**, Schulz C, Link A, Malfertheiner P. Current biomarkers for hepatocellular carcinoma: Surveillance, diagnosis and

- prediction of prognosis. *World J Hepatol* 2015; **7**: 139-149 [PMID: 25729470 DOI: 10.4254/wjh.v7.i2.139]
- 103 **Llovet JM**, Brú C, Bruix J. Prognosis of hepatocellular carcinoma: the BCLC staging classification. *Semin Liver Dis* 1999; **19**: 329-338 [PMID: 10518312 DOI: 10.1055/s-2007-1007122]
- 104 **Grieco A**, Pompili M, Caminiti G, Miele L, Covino M, Alfei B, Rapaccini GL, Gasbarrini G. Prognostic factors for survival in patients with early-intermediate hepatocellular carcinoma undergoing non-surgical therapy: comparison of Okuda, CLIP, and BCLC staging systems in a single Italian centre. *Gut* 2005; **54**: 411-418 [PMID: 15710992 DOI: 10.1136/gut.2004.048124]
- 105 **Marrero JA**, Fontana RJ, Barrat A, Askari F, Conjeevaram HS, Su GL, Lok AS. Prognosis of hepatocellular carcinoma: comparison of 7 staging systems in an American cohort. *Hepatology* 2005; **41**: 707-716 [PMID: 15795889 DOI: 10.1002/hep.20636]
- 106 **Makuuchi M**, Kosuge T, Takayama T, Yamazaki S, Kakazu T, Miyagawa S, Kawasaki S. Surgery for small liver cancers. *Semin Surg Oncol* 1993; **9**: 298-304 [PMID: 8210909]
- 107 **Imamura H**, Seyama Y, Kokudo N, Maema A, Sugawara Y, Sano K, Takayama T, Makuuchi M. One thousand fifty-six hepatectomies without mortality in 8 years. *Arch Surg* 2003; **138**: 1198-1206; discussion 1206 [PMID: 14609867 DOI: 10.1001/archsurg.138.11.1198]
- 108 **Nakayama H**, Takayama T, Okubo T, Higaki T, Midorikawa Y, Moriguchi M, Itoh A. Proposal of objective morphological classification system for hepatocellular carcinoma using preoperative multiphase computed tomography. *J Gastroenterol* 2014; **49**: 1430-1437 [PMID: 24240709 DOI: 10.1007/s00535-013-0908-9]
- 109 **Makuuchi M**, Hasegawa H, Yamazaki S. Ultrasonically guided subsegmentectomy. *Surg Gynecol Obstet* 1985; **161**: 346-350 [PMID: 2996162]
- 110 **Arii S**, Tanaka J, Yamazoe Y, Minematsu S, Morino T, Fujita K, Maetani S, Tobe T. Predictive factors for intrahepatic recurrence of hepatocellular carcinoma after partial hepatectomy. *Cancer* 1992; **69**: 913-919 [PMID: 1310434]
- 111 **Imamura H**, Matsuyama Y, Tanaka E, Ohkubo T, Hasegawa K, Miyagawa S, Sugawara Y, Minagawa M, Takayama T, Kawasaki S, Makuuchi M. Risk factors contributing to early and late phase intrahepatic recurrence of hepatocellular carcinoma after hepatectomy. *J Hepatol* 2003; **38**: 200-207 [PMID: 12547409 DOI: 10.1016/S0168-8278(02)00360-4]
- 112 **Hasegawa K**, Kokudo N, Imamura H, Matsuyama Y, Aoki T, Minagawa M, Sano K, Sugawara Y, Takayama T, Makuuchi M. Prognostic impact of anatomic resection for hepatocellular carcinoma. *Ann Surg* 2005; **242**: 252-259 [PMID: 16041216 DOI: 10.1097/01.sla.0000171307.37401.db]
- 113 **Kubota K**, Makuuchi M, Kusaka K, Kobayashi T, Miki K, Hasegawa K, Harihara Y, Takayama T. Measurement of liver volume and hepatic functional reserve as a guide to decision-making in resectional surgery for hepatic tumors. *Hepatology* 1997; **26**: 1176-1181 [PMID: 9362359 DOI: 10.1053/jhep.1997.v26.pm0009362359]
- 114 **Abdalla EK**, Barnett CC, Doherty D, Curley SA, Vauthey JN. Extended hepatectomy in patients with hepatobiliary malignancies with and without preoperative portal vein embolization. *Arch Surg* 2002; **137**: 675-680; discussion 680-681 [PMID: 12049538 DOI: 10.1001/archsurg.137.6.675]
- 115 **Schindl MJ**, Redhead DN, Fearon KC, Garden OJ, Wigmore SJ. The value of residual liver volume as a predictor of hepatic dysfunction and infection after major liver resection. *Gut* 2005; **54**: 289-296 [PMID: 15647196 DOI: 10.1136/gut.2004.046524]
- 116 **Nagino M**, Kamiya J, Nishio H, Ebata T, Arai T, Nimura Y. Two hundred forty consecutive portal vein embolizations before extended hepatectomy for biliary cancer: surgical outcome and long-term follow-up. *Ann Surg* 2006; **243**: 364-372 [PMID: 16495702 DOI: 10.1097/01.sla.0000201482.11876.14]
- 117 **Sano T**, Shimada K, Sakamoto Y, Yamamoto J, Yamasaki S, Kosuge T. One hundred two consecutive hepatobiliary resections for perihilar cholangiocarcinoma with zero mortality. *Ann Surg* 2006; **244**: 240-247 [PMID: 16858186 DOI: 10.1097/01.sla.0000217605.66519.38]
- 118 **Ferrero A**, Viganò L, Polastri R, Muratore A, Eminefendic H, Regge D, Capussotti L. Postoperative liver dysfunction and future remnant liver: where is the limit? Results of a prospective study. *World J Surg* 2007; **31**: 1643-1651 [PMID: 17551779 DOI: 10.1007/s00268-007-9123-2]
- 119 **Giraud G**, Greget M, Oussoultzoglou E, Rosso E, Bachellier P, Jaeck D. Preoperative contralateral portal vein embolization before major hepatic resection is a safe and efficient procedure: a large single institution experience. *Surgery* 2008; **143**: 476-482 [PMID: 18374044 DOI: 10.1016/j.surg.2007.12.006]
- 120 **Shimada K**, Nara S, Esaki M, Sakamoto Y, Kosuge T, Hiraoka N. Extended right hemihepatectomy for gallbladder carcinoma involving the hepatic hilum. *Br J Surg* 2011; **98**: 117-123 [PMID: 21136566 DOI: 10.1002/bjs.7262]
- 121 **Kishi Y**, Abdalla EK, Chun YS, Zorzi D, Madoff DC, Wallace MJ, Curley SA, Vauthey JN. Three hundred and one consecutive extended right hepatectomies: evaluation of outcome based on systematic liver volumetry. *Ann Surg* 2009; **250**: 540-548 [PMID: 19730239 DOI: 10.1097/SLA.0b013e3181b674df]
- 122 **Makuuchi M**, Thai BL, Takayasu K, Takayama T, Kosuge T, Gunvén P, Yamazaki S, Hasegawa H, Ozaki H. Preoperative portal embolization to increase safety of major hepatectomy for hilar bile duct carcinoma: a preliminary report. *Surgery* 1990; **107**: 521-527 [PMID: 2333592]
- 123 **Saito S**, Yamanaka J, Miura K, Nakao N, Nagao T, Sugimoto T, Hirano T, Kuroda N, Iimuro Y, Fujimoto J. A novel 3D hepatectomy simulation based on liver circulation: application to liver resection and transplantation. *Hepatology* 2005; **41**: 1297-1304 [PMID: 15846773 DOI: 10.1002/hep.20684]
- 124 **Ijichi M**, Takayama T, Toyoda H, Sano K, Kubota K, Makuuchi M. Randomized trial of the usefulness of a bile leakage test during hepatic resection. *Arch Surg* 2000; **135**: 1395-1400 [PMID: 11115338 DOI: 10.1001/archsurg.135.12.1395]
- 125 **Liu Z**, Jin H, Li Y, Gu Y, Zhai C. Randomized controlled trial of the intraoperative bile leakage test in preventing bile leakage after hepatic resection. *Dig Surg* 2012; **29**: 510-515 [PMID: 23392477 DOI: 10.1159/000346480]
- 126 **Mangram AJ**, Horan TC, Pearson ML, Silver LC, Jarvis WR. Guideline for prevention of surgical site infection, 1999. Hospital Infection Control Practices Advisory Committee. *Infect Control Hosp Epidemiol* 1999; **20**: 250-278; quiz 279-280 [PMID: 10219875 DOI: 10.1086/501620]
- 127 **Liu CL**, Fan ST, Lo CM, Wong Y, Ng IO, Lam CM, Poon RT, Wong J. Abdominal drainage after hepatic resection is contraindicated in patients with chronic liver diseases. *Ann Surg* 2004; **239**: 194-201 [PMID: 14745327 DOI: 10.1097/01.sla.0000109153.71725.8c]
- 128 **Sun HC**, Qin LX, Lu L, Wang L, Ye QH, Ren N, Fan J, Tang ZY. Randomized clinical trial of the effects of abdominal drainage after elective hepatectomy using the crushing clamp method. *Br J Surg* 2006; **93**: 422-426 [PMID: 16491462 DOI: 10.1002/bjs.5260]
- 129 **Belghiti J**, Kabbej M, Sauvanet A, Vilgrain V, Panis Y, Fekete F. Drainage after elective hepatic resection. A randomized trial. *Ann Surg* 1993; **218**: 748-753 [PMID: 8257225]
- 130 **Franco D**, Karaa A, Meakins JL, Borgonovo G, Smadja C, Grange D. Hepatectomy without abdominal drainage. Results of a prospective study in 61 patients. *Ann Surg* 1989; **210**: 748-750 [PMID: 2556083]
- 131 **Burt BM**, Brown K, Jarnagin W, DeMatteo R, Blumgart LH, Fong Y. An audit of results of a no-drainage practice policy after hepatectomy. *Am J Surg* 2002; **184**: 441-445 [PMID: 12433610 DOI: 10.1016/S0002-9610(02)00998-4]
- 132 **Lu L**, Sun HC, Qin LX, Wang L, Ye QH, Ren N, Fan J, Tang ZY. Abdominal drainage was unnecessary after hepatectomy using the conventional clamp crushing technique. *J Gastrointest Surg* 2006; **10**: 302-308 [PMID: 16455466 DOI: 10.1016/j.gassur.2005.06.002]
- 133 **Yamazaki S**, Takayama T, Moriguchi M, Mitsuka Y, Okada S, Midorikawa Y, Nakayama H, Higaki T. Criteria for drain removal following liver resection. *Br J Surg* 2012; **99**: 1584-1590 [PMID: 23027077 DOI: 10.1002/bjs.8916]

- 134 **Nakayama H**, Takayama T, Okubo T, Higaki T, Midorikawa Y, Moriguchi M, Aramaki O, Yamazaki S. Subcutaneous drainage to prevent wound infection in liver resection: a randomized controlled trial. *J Hepatobiliary Pancreat Sci* 2014; **21**: 509-517 [PMID: 24519844 DOI: 10.1002/jhpb.93]
- 135 **Hayashi Y**, Takayama T, Yamazaki S, Moriguchi M, Ohkubo T, Nakayama H, Higaki T. Validation of perioperative steroids administration in liver resection: a randomized controlled trial. *Ann Surg* 2011; **253**: 50-55 [PMID: 21233606 DOI: 10.1097/SLA.0b013e31820466bb]
- 136 **Rahbari NN**, Garden OJ, Padbury R, Brooke-Smith M, Crawford M, Adam R, Koch M, Makuuchi M, Dematteo RP, Christophi C, Banting S, Usatoff V, Nagino M, Maddern G, Hugh TJ, Vauthey JN, Greig P, Rees M, Yokoyama Y, Fan ST, Nimura Y, Figueras J, Capussotti L, Büchler MW, Weitz J. Posthepatectomy liver failure: a definition and grading by the International Study Group of Liver Surgery (ISGLS). *Surgery* 2011; **149**: 713-724 [PMID: 21236455 DOI: 10.1016/j.surg.2010.10.001]
- 137 **Balzan S**, Belghiti J, Farges O, Ogata S, Sauvanet A, Delefosse D, Durand F. The "50-50 criteria" on postoperative day 5: an accurate predictor of liver failure and death after hepatectomy. *Ann Surg* 2005; **242**: 824-828, discussion 828-829 [PMID: 16327492 DOI: 10.1097/01.sla.0000189131.90876.9e]
- 138 **Rahbari NN**, Reissfelder C, Koch M, Elbers H, Striebel F, Büchler MW, Weitz J. The predictive value of postoperative clinical risk scores for outcome after hepatic resection: a validation analysis in 807 patients. *Ann Surg Oncol* 2011; **18**: 3640-3649 [PMID: 21674269 DOI: 10.1245/s10434-011-1829-6]
- 139 **Mazzaferro V**, Regalia E, Doci R, Andreola S, Pulvirenti A, Bozzetti F, Montalto F, Ammatuna M, Morabito A, Gennari L. Liver transplantation for the treatment of small hepatocellular carcinomas in patients with cirrhosis. *N Engl J Med* 1996; **334**: 693-699 [PMID: 8594428 DOI: 10.1056/NEJM199603143341104]
- 140 **Bismuth H**, Majno PE, Adam R. Liver transplantation for hepatocellular carcinoma. *Semin Liver Dis* 1999; **19**: 311-322 [PMID: 10518310 DOI: 10.1055/s-2007-1007120]
- 141 **Yao FY**, Ferrell L, Bass NM, Bacchetti P, Ascher NL, Roberts JP. Liver transplantation for hepatocellular carcinoma: comparison of the proposed UCSF criteria with the Milan criteria and the Pittsburgh modified TNM criteria. *Liver Transpl* 2002; **8**: 765-774 [PMID: 12200775 DOI: 10.1053/jlts.2002.34892]
- 142 **Yao FY**, Ferrell L, Bass NM, Watson JJ, Bacchetti P, Venook A, Ascher NL, Roberts JP. Liver transplantation for hepatocellular carcinoma: expansion of the tumor size limits does not adversely impact survival. *Hepatology* 2001; **33**: 1394-1403 [PMID: 11391528 DOI: 10.1053/jhep.2001.24563]
- 143 **Cillo U**, Vitale A, Bassanello M, Boccagni P, Brolese A, Zanus G, Burra P, Fagioli S, Farinati F, Rugge M, D'Amico DF. Liver transplantation for the treatment of moderately or well-differentiated hepatocellular carcinoma. *Ann Surg* 2004; **239**: 150-159 [PMID: 14745321 DOI: 10.1097/01.sla.0000109146.72827.7e]
- 144 **DuBay D**, Sandroussi C, Sandhu L, Cleary S, Guba M, Cattral MS, McGilvray I, Ghanekar A, Selzner M, Greig PD, Grant DR. Liver transplantation for advanced hepatocellular carcinoma using poor tumor differentiation on biopsy as an exclusion criterion. *Ann Surg* 2011; **253**: 166-172 [PMID: 21294289 DOI: 10.1097/SLA.0b013e31820508f1]
- 145 **Avolio AW**, Siciliano M, Barone M, Lai Q, Caracciolo GL, Barbarino R, Nicolotti N, Lirosi MC, Gasbarrini A, Agnes S. Model for end-stage liver disease dynamic stratification of survival benefit. *Transplant Proc* 2012; **44**: 1851-1856 [PMID: 22974854 DOI: 10.1016/j.transproceed.2012.06.056]
- 146 **Lai JC**, Feng S, Roberts JP. An examination of liver offers to candidates on the liver transplant wait-list. *Gastroenterology* 2012; **143**: 1261-1265 [PMID: 22841780 DOI: 10.1053/j.gastro.2012.07.105]
- 147 **Maggs JR**, Suddle AR, Aluvihare V, Heneghan MA. Systematic review: the role of liver transplantation in the management of hepatocellular carcinoma. *Aliment Pharmacol Ther* 2012; **35**: 1113-1134 [PMID: 22432733 DOI: 10.1111/j.1365-2036.2012.05072.x]
- 148 **Washburn K**, Pomfret E, Roberts J. Liver allocation and distribution: possible next steps. *Liver Transpl* 2011; **17**: 1005-1012 [PMID: 21634007 DOI: 10.1002/lt.22349]
- 149 **Gordon Burroughs S**, Busuttil RW. Optimal utilization of extended hepatic grafts. *Surg Today* 2009; **39**: 746-751 [PMID: 19779769 DOI: 10.1007/s00595-008-4022-1]
- 150 **Yaprak O**, Akyildiz M, Dayangac M, Demirbas BT, Guler N, Dogusoy GB, Yuzeer Y, Tokat Y. AFP level and histologic differentiation predict the survival of patients with liver transplantation for hepatocellular carcinoma. *Hepatobiliary Pancreat Dis Int* 2012; **11**: 256-261 [PMID: 22672818 DOI: 10.1016/S1499-3872(12)60157-X]
- 151 **Singal AG**, Chan V, Getachew Y, Guerrero R, Reisch JS, Cuthbert JA. Predictors of liver transplant eligibility for patients with hepatocellular carcinoma in a safety net hospital. *Dig Dis Sci* 2012; **57**: 580-586 [PMID: 21953138 DOI: 10.1007/s10620-011-1904-7]
- 152 **Zarrinpar A**, Kaldas F, Busuttil RW. Liver transplantation for hepatocellular carcinoma: an update. *Hepatobiliary Pancreat Dis Int* 2011; **10**: 234-242 [PMID: 21669564]
- 153 **Vivarelli M**, Risaliti A. Liver transplantation for hepatocellular carcinoma on cirrhosis: strategies to avoid tumor recurrence. *World J Gastroenterol* 2011; **17**: 4741-4746 [PMID: 22147974 DOI: 10.3748/wjg.v17.i43.4741]
- 154 **Chok KS**, Chan SC, Cheung TT, Chan AC, Fan ST, Lo CM. Late recurrence of hepatocellular carcinoma after liver transplantation. *World J Surg* 2011; **35**: 2058-2062 [PMID: 21597889 DOI: 10.1007/s00268-011-1146-z]
- 155 **Kulik LM**, Fisher RA, Rodrigo DR, Brown RS, Freise CE, Shaked A, Everhart JE, Everson GT, Hong JC, Hayashi PH, Berg CL, Lok AS; A2ALL Study Group. Outcomes of living and deceased donor liver transplant recipients with hepatocellular carcinoma: results of the A2ALL cohort. *Am J Transplant* 2012; **12**: 2997-3007 [PMID: 22994906 DOI: 10.1111/j.1600-6143.2012.04272.x]
- 156 **Liang W**, Wu L, Ling X, Schroder PM, Ju W, Wang D, Shang Y, Kong Y, Guo Z, He X. Living donor liver transplantation versus deceased donor liver transplantation for hepatocellular carcinoma: a meta-analysis. *Liver Transpl* 2012; **18**: 1226-1236 [PMID: 22685095 DOI: 10.1002/lt.23490]
- 157 **Moon JI**, Kwon CH, Joh JW, Choi GS, Jung GO, Kim JM, Shin M, Choi SJ, Kim SJ, Lee SK. Primary versus salvage living donor liver transplantation for patients with hepatocellular carcinoma: impact of microvascular invasion on survival. *Transplant Proc* 2012; **44**: 487-493 [PMID: 22410053 DOI: 10.1016/j.transproceed.2011.11.009]
- 158 **Sandhu L**, Sandroussi C, Guba M, Selzner M, Ghanekar A, Cattral MS, McGilvray ID, Levy G, Greig PD, Renner EL, Grant DR. Living donor liver transplantation versus deceased donor liver transplantation for hepatocellular carcinoma: comparable survival and recurrence. *Liver Transpl* 2012; **18**: 315-322 [PMID: 22140013 DOI: 10.1002/lt.22477]
- 159 **Earl TM**, Chapman WC. Transplantation for hepatocellular carcinoma: the North American experience. *Recent Results Cancer Res* 2013; **190**: 145-164 [PMID: 22941019 DOI: 10.1007/978-3-642-16037-0\_10]
- 160 **Lee SG**, Moon DB. Living donor liver transplantation for hepatocellular carcinoma. *Recent Results Cancer Res* 2013; **190**: 165-179 [PMID: 22941020 DOI: 10.1007/978-3-642-16037-0\_11]
- 161 **Kneteman NM**, Oberholzer J, Al Saghier M, Meeberg GA, Blitz M, Ma MM, Wong WW, Gutfreund K, Mason AL, Jewell LD, Shapiro AM, Bain VG, Bigam DL. Sirolimus-based immunosuppression for liver transplantation in the presence of extended criteria for hepatocellular carcinoma. *Liver Transpl* 2004; **10**: 1301-1311 [PMID: 15376305 DOI: 10.1002/lt.20237]
- 162 **Kawahara T**, Asthana S, Kneteman NM. m-TOR inhibitors: what role in liver transplantation? *J Hepatol* 2011; **55**: 1441-1451 [PMID: 21781947 DOI: 10.1016/j.jhep.2011.06.015]
- 163 **Schnitzbauer AA**, Zuelke C, Graeb C, Rochon J, Bilbao I, Burra P, de Jong KP, Duvoux C, Kneteman NM, Adam R, Bechstein WO, Becker T, Beckebaum S, Chazouillères O, Cillo U, Colledan M, Fändrich F, Gugenheim J, Hauss JP, Heise M, Hidalgo E, Jamieson N, Königsrainer A, Lamby PE, Lerut JP, Mäkitalo H,

- Margreiter R, Mazzaferro V, Mutzbauer I, Otto G, Pageaux GP, Pinna AD, Pirenne J, Rizell M, Rossi G, Rostaing L, Roy A, Turrión VS, Schmidt J, Troisi RI, van Hoek B, Valente U, Wolf P, Wolters H, Mirza DF, Scholz T, Steininger R, Soderdahl G, Strasser SI, Jauch KW, Neuhaus P, Schlitt HJ, Geissler EK. A prospective randomised, open-labeled, trial comparing sirolimus-containing versus mTOR-inhibitor-free immunosuppression in patients undergoing liver transplantation for hepatocellular carcinoma. *BMC Cancer* 2010; **10**: 190 [PMID: 20459775 DOI: 10.1186/1471-2407-10-190]
- 164 **Toso C**, Merani S, Bigam DL, Shapiro AM, Kneteman NM. Sirolimus-based immunosuppression is associated with increased survival after liver transplantation for hepatocellular carcinoma. *Hepatology* 2010; **51**: 1237-1243 [PMID: 20187107 DOI: 10.1002/hep.23437]
- 165 **Toso C**, Meeberg GA, Bigam DL, Oberholzer J, Shapiro AM, Gutfreund K, Ma MM, Mason AL, Wong WW, Bain VG, Kneteman NM. De novo sirolimus-based immunosuppression after liver transplantation for hepatocellular carcinoma: long-term outcomes and side effects. *Transplantation* 2007; **83**: 1162-1168 [PMID: 17496530 DOI: 10.1097/01.tp.0000262607.95372.e0]
- 166 **Ahmed M**, Brace CL, Lee FT, Goldberg SN. Principles of and advances in percutaneous ablation. *Radiology* 2011; **258**: 351-369 [PMID: 21273519 DOI: 10.1148/radiol.10081634]
- 167 **Haemmerich D**, Pilcher TA. Convective cooling affects cardiac catheter cryoablation and radiofrequency ablation in opposite directions. *Conf Proc IEEE Eng Med Biol Soc* 2007; **2007**: 1499-1502 [PMID: 18002251 DOI: 10.1109/IEMBS.2007.4352585]
- 168 **Dupuy DE**, Goldberg SN. Image-guided radiofrequency tumor ablation: challenges and opportunities--part II. *J Vasc Interv Radiol* 2001; **12**: 1135-1148 [PMID: 11585879]
- 169 **Goldberg SN**. Radiofrequency tumor ablation: principles and techniques. *Eur J Ultrasound* 2001; **13**: 129-147 [PMID: 11369525 DOI: 10.1016/S0929-8266(01)00126-4]
- 170 **Rhim H**, Dodd GD, Chintapalli KN, Wood BJ, Dupuy DE, Hvizda JL, Sewell PE, Goldberg SN. Radiofrequency thermal ablation of abdominal tumors: lessons learned from complications. *Radiographics* 2004; **24**: 41-52 [PMID: 14730035 DOI: 10.1148/rg.241025144]
- 171 **Huffman SD**, Huffman NP, Lewandowski RJ, Brown DB. Radiofrequency ablation complicated by skin burn. *Semin Intervent Radiol* 2011; **28**: 179-182 [PMID: 22654258 DOI: 10.1055/s-0031-1280660]
- 172 **Kim KR**, Thomas S. Complications of image-guided thermal ablation of liver and kidney neoplasms. *Semin Intervent Radiol* 2014; **31**: 138-148 [PMID: 25049443 DOI: 10.1055/s-0034-1373789]
- 173 **Lu DS**, Raman SS, Limanond P, Aziz D, Economou J, Busuttill R, Sayre J. Influence of large peritumoral vessels on outcome of radiofrequency ablation of liver tumors. *J Vasc Interv Radiol* 2003; **14**: 1267-1274 [PMID: 14551273]
- 174 **Weis S**, Franke A, Mössner J, Jakobsen JC, Schoppmeyer K. Radiofrequency (thermal) ablation versus no intervention or other interventions for hepatocellular carcinoma. *Cochrane Database Syst Rev* 2013; **12**: CD003046 [PMID: 24357457 DOI: 10.1002/14651858.CD003046.pub3]
- 175 **Huang J**, Yan L, Cheng Z, Wu H, Du L, Wang J, Xu Y, Zeng Y. A randomized trial comparing radiofrequency ablation and surgical resection for HCC conforming to the Milan criteria. *Ann Surg* 2010; **252**: 903-912 [PMID: 21107100 DOI: 10.1097/SLA.0b013e3181efc656]
- 176 **Chen MS**, Li JQ, Zheng Y, Guo RP, Liang HH, Zhang YQ, Lin XJ, Lau WY. A prospective randomized trial comparing percutaneous local ablative therapy and partial hepatectomy for small hepatocellular carcinoma. *Ann Surg* 2006; **243**: 321-328 [PMID: 16495695 DOI: 10.1097/01.sla.0000201480.65519.b8]
- 177 **Feng K**, Yan J, Li X, Xia F, Ma K, Wang S, Bie P, Dong J. A randomized controlled trial of radiofrequency ablation and surgical resection in the treatment of small hepatocellular carcinoma. *J Hepatol* 2012; **57**: 794-802 [PMID: 22634125 DOI: 10.1016/j.jhep.2012.05.007]
- 178 **Brunello F**, Veltri A, Carucci P, Pagano E, Ciccone G, Moretto P, Sacchetto P, Gandini G, Rizzetto M. Radiofrequency ablation versus ethanol injection for early hepatocellular carcinoma: A randomized controlled trial. *Scand J Gastroenterol* 2008; **43**: 727-735 [PMID: 18569991 DOI: 10.1080/00365520701885481]
- 179 **Giorgio A**, Di Sarno A, De Stefano G, Scognamiglio U, Farella N, Mariniello A, Esposito V, Coppola C, Giorgio V. Percutaneous radiofrequency ablation of hepatocellular carcinoma compared to percutaneous ethanol injection in treatment of cirrhotic patients: an Italian randomized controlled trial. *Anticancer Res* 2011; **31**: 2291-2295 [PMID: 21737654]
- 180 **Lencioni RA**, Allgaier HP, Cioni D, Olschewski M, Deibert P, Crocetti L, Frings H, Laubenberger J, Zuber I, Blum HE, Bartolozzi C. Small hepatocellular carcinoma in cirrhosis: randomized comparison of radio-frequency thermal ablation versus percutaneous ethanol injection. *Radiology* 2003; **228**: 235-240 [PMID: 12759473 DOI: 10.1148/radiol.2281020718]
- 181 **Lin SM**, Lin CJ, Lin CC, Hsu CW, Chen YC. Radiofrequency ablation improves prognosis compared with ethanol injection for hepatocellular carcinoma < or =4 cm. *Gastroenterology* 2004; **127**: 1714-1723 [PMID: 15578509 DOI: 10.1053/j.gastro.2004.09.003]
- 182 **Lin SM**, Lin CJ, Lin CC, Hsu CW, Chen YC. Randomised controlled trial comparing percutaneous radiofrequency thermal ablation, percutaneous ethanol injection, and percutaneous acetic acid injection to treat hepatocellular carcinoma of 3 cm or less. *Gut* 2005; **54**: 1151-1156 [PMID: 16009687 DOI: 10.1136/gut.2004.045203]
- 183 **Shiina S**, Teratani T, Obi S, Sato S, Tateishi R, Fujishima T, Ishikawa T, Koike Y, Yoshida H, Kawabe T, Omata M. A randomized controlled trial of radiofrequency ablation with ethanol injection for small hepatocellular carcinoma. *Gastroenterology* 2005; **129**: 122-130 [PMID: 16012942 DOI: 10.1053/j.gastro.2005.04.009]
- 184 **Shibata T**, Iimuro Y, Yamamoto Y, Maetani Y, Ametani F, Itoh K, Konishi J. Small hepatocellular carcinoma: comparison of radiofrequency ablation and percutaneous microwave coagulation therapy. *Radiology* 2002; **223**: 331-337 [PMID: 11997534 DOI: 10.1148/radiol.2232010775]
- 185 **Ferrari FS**, Megliola A, Scorzelli A, Stella A, Vigni F, Drudi FM, Venezia D. Treatment of small HCC through radiofrequency ablation and laser ablation. Comparison of techniques and long-term results. *Radiol Med* 2007; **112**: 377-393 [PMID: 17447018 DOI: 10.1007/s11547-007-0148-2]
- 186 **Lee YH**, Hsu CY, Chu CW, Liu PH, Hsia CY, Huang YH, Su CW, Chiou YY, Lin HC, Huo TI. Radiofrequency ablation is better than surgical resection in patients with hepatocellular carcinoma within the Milan criteria and preserved liver function: a retrospective study using propensity score analyses. *J Clin Gastroenterol* 2015; **49**: 242-249 [PMID: 24714185 DOI: 10.1097/MCG.0000000000000133]
- 187 **Knave EM**, Brace CL. Tumor ablation: common modalities and general practices. *Tech Vasc Interv Radiol* 2013; **16**: 192-200 [PMID: 24238374 DOI: 10.1053/j.tvir.2013.08.002]
- 188 **Schramm W**, Yang D, Wood BJ, Rattay F, Haemmerich D. Contribution of direct heating, thermal conduction and perfusion during radiofrequency and microwave ablation. *Open Biomed Eng J* 2007; **1**: 47-52 [PMID: 19662127 DOI: 10.2174/1874120700701010047]
- 189 **Ding J**, Jing X, Liu J, Wang Y, Wang F, Wang Y, Du Z. Comparison of two different thermal techniques for the treatment of hepatocellular carcinoma. *Eur J Radiol* 2013; **82**: 1379-1384 [PMID: 23726122 DOI: 10.1016/j.ejrad.2013.04.025]
- 190 **Ding J**, Jing X, Liu J, Wang Y, Wang F, Wang Y, Du Z. Complications of thermal ablation of hepatic tumours: comparison of radiofrequency and microwave ablative techniques. *Clin Radiol* 2013; **68**: 608-615 [PMID: 23399463 DOI: 10.1016/j.crad.2012.12.008]
- 191 **Zhang L**, Wang N, Shen Q, Cheng W, Qian GJ. Therapeutic efficacy of percutaneous radiofrequency ablation versus microwave ablation for hepatocellular carcinoma. *PLoS One* 2013; **8**: e76119 [PMID: 24146824 DOI: 10.1371/journal.pone.0076119]
- 192 **McCarley JR**, Soulen MC. Percutaneous ablation of hepatic tumors.



- Semin Intervent Radiol* 2010; **27**: 255-260 [PMID: 22550364 DOI: 10.1055/s-0030-1261783]
- 193 **Ebara M**, Okabe S, Kita K, Sugiura N, Fukuda H, Yoshikawa M, Kondo F, Saisho H. Percutaneous ethanol injection for small hepatocellular carcinoma: therapeutic efficacy based on 20-year observation. *J Hepatol* 2005; **43**: 458-464 [PMID: 16005538 DOI: 10.1016/j.jhep.2005.03.033]
- 194 **Taniguchi M**, Kim SR, Imoto S, Ikawa H, Ando K, Mita K, Fuki S, Sasase N, Matsuoka T, Kudo M, Hayashi Y. Long-term outcome of percutaneous ethanol injection therapy for minimum-sized hepatocellular carcinoma. *World J Gastroenterol* 2008; **14**: 1997-2002 [PMID: 18395898 DOI: 10.3748/wjg.14.1997]
- 195 **Marks LB**, Yorke ED, Jackson A, Ten Haken RK, Constine LS, Eisbruch A, Bentzen SM, Nam J, Deasy JO. Use of normal tissue complication probability models in the clinic. *Int J Radiat Oncol Biol Phys* 2010; **76**: S10-S19 [PMID: 20171502 DOI: 10.1016/j.ijrobp.2009.07.1754]
- 196 **Rusthoven KE**, Kavanagh BD, Cardenes H, Stieber VW, Burri SH, Feigenberg SJ, Chidel MA, Pugh TJ, Franklin W, Kane M, Gaspar LE, Schefter TE. Multi-institutional phase I/II trial of stereotactic body radiation therapy for liver metastases. *J Clin Oncol* 2009; **27**: 1572-1578 [PMID: 19255321 DOI: 10.1200/JCO.2008.19.6329]
- 197 **Wagman R**, Yorke E, Ford E, Giraud P, Mageras G, Minsky B, Rosenzweig K. Respiratory gating for liver tumors: use in dose escalation. *Int J Radiat Oncol Biol Phys* 2003; **55**: 659-668 [PMID: 12573753 DOI: 10.1016/S0360-3016(02)03941-X]
- 198 **Wunderink W**, Méndez Romero A, de Kruijff W, de Boer H, Levendag P, Heijmen B. Reduction of respiratory liver tumor motion by abdominal compression in stereotactic body frame, analyzed by tracking fiducial markers implanted in liver. *Int J Radiat Oncol Biol Phys* 2008; **71**: 907-915 [PMID: 18514783 DOI: 10.1016/j.ijrobp.2008.03.010]
- 199 **Méndez Romero A**, Wunderink W, Hussain SM, De Pooter JA, Heijmen BJ, Nowak PC, Nuytens JJ, Brandwijk RP, Verhoef C, Ijzermans JN, Levendag PC. Stereotactic body radiation therapy for primary and metastatic liver tumors: A single institution phase i-ii study. *Acta Oncol* 2006; **45**: 831-837 [PMID: 16982547 DOI: 10.1080/02841860600897934]
- 200 **Denecke T**, Lopez Hänninen E. Brachytherapy of liver metastases. *Recent Results Cancer Res* 2008; **177**: 95-104 [PMID: 18084951]
- 201 **Ricke J**, Mohnike K, Pech M, Seidensticker M, Rühl R, Wieners G, Gaffke G, Kropf S, Felix R, Wust P. Local response and impact on survival after local ablation of liver metastases from colorectal carcinoma by computed tomography-guided high-dose-rate brachytherapy. *Int J Radiat Oncol Biol Phys* 2010; **78**: 479-485 [PMID: 20304566 DOI: 10.1016/j.ijrobp.2009.09.026]
- 202 **Collettini F**, Lutter A, Schnapauß D, Hildebrandt B, Puhl G, Denecke T, Wust P, Gebauer B. Unresectable colorectal liver metastases: percutaneous ablation using CT-guided high-dose-rate brachytherapy (CT-HDBRT). *Rofo* 2014; **186**: 606-612 [PMID: 24407711 DOI: 10.1055/s-0033-1355887]
- 203 **Ricke J**, Wust P, Wieners G, Beck A, Cho CH, Seidensticker M, Pech M, Werk M, Rosner C, Hänninen EL, Freund T, Felix R. Liver malignancies: CT-guided interstitial brachytherapy in patients with unfavorable lesions for thermal ablation. *J Vasc Interv Radiol* 2004; **15**: 1279-1286 [PMID: 15525748]
- 204 **Mearini L**. High intensity focused ultrasound, liver disease and bridging therapy. *World J Gastroenterol* 2013; **19**: 7494-7499 [PMID: 24282341 DOI: 10.3748/wjg.v19.i43.7494]
- 205 **Cheung TT**, Fan ST, Chan SC, Chok KS, Chu FS, Jenkins CR, Lo RC, Fung JY, Chan AC, Sharr WW, Tsang SH, Dai WC, Poon RT, Lo CM. High-intensity focused ultrasound ablation: an effective bridging therapy for hepatocellular carcinoma patients. *World J Gastroenterol* 2013; **19**: 3083-3089 [PMID: 23716988 DOI: 10.3748/wjg.v19.i20.3083]
- 206 **Shen HP**, Gong JP, Zuo GQ. Role of high-intensity focused ultrasound in treatment of hepatocellular carcinoma. *Am Surg* 2011; **77**: 1496-1501 [PMID: 22196664]
- 207 **Xu G**, Luo G, He L, Li J, Shan H, Zhang R, Li Y, Gao X, Lin S, Wang G. Follow-up of high-intensity focused ultrasound treatment for patients with hepatocellular carcinoma. *Ultrasound Med Biol* 2011; **37**: 1993-1999 [PMID: 22036638 DOI: 10.1016/j.ultrasmedbio.2011.08.011]
- 208 **Ng KK**, Poon RT, Chan SC, Chok KS, Cheung TT, Tung H, Chu F, Tso WK, Yu WC, Lo CM, Fan ST. High-intensity focused ultrasound for hepatocellular carcinoma: a single-center experience. *Ann Surg* 2011; **253**: 981-987 [PMID: 21394012 DOI: 10.1097/SLA.0b013e3182128a8b]
- 209 **Wu F**, Wang ZB, Chen WZ, Zhu H, Bai J, Zou JZ, Li KQ, Jin CB, Xie FL, Su HB. Extracorporeal high intensity focused ultrasound ablation in the treatment of patients with large hepatocellular carcinoma. *Ann Surg Oncol* 2004; **11**: 1061-1069 [PMID: 15545506 DOI: 10.1245/ASO.2004.02.026]
- 210 **Wu F**, Wang ZB, Chen WZ, Wang W, Gui Y, Zhang M, Zheng G, Zhou Y, Xu G, Li M, Zhang C, Ye H, Feng R. Extracorporeal high intensity focused ultrasound ablation in the treatment of 1038 patients with solid carcinomas in China: an overview. *Ultrason Sonochem* 2004; **11**: 149-154 [PMID: 15081972 DOI: 10.1016/j.jultsonch.2004.01.011]
- 211 **Wu F**, Wang ZB, Chen WZ, Zou JZ, Bai J, Zhu H, Li KQ, Jin CB, Xie FL, Su HB. Advanced hepatocellular carcinoma: treatment with high-intensity focused ultrasound ablation combined with transcatheter arterial embolization. *Radiology* 2005; **235**: 659-667 [PMID: 15858105 DOI: 10.1148/radiol.2352030916]
- 212 **Lu DS**, Kee ST, Lee EW. Irreversible electroporation: ready for prime time? *Tech Vasc Interv Radiol* 2013; **16**: 277-286 [PMID: 24238383 DOI: 10.1053/j.tvir.2013.08.010]
- 213 **Ben-David E**, Appelbaum L, Sosna J, Nissenbaum I, Goldberg SN. Characterization of irreversible electroporation ablation in in vivo porcine liver. *AJR Am J Roentgenol* 2012; **198**: W62-W68 [PMID: 22194517 DOI: 10.2214/AJR.11.6940]
- 214 **Silk MT**, Wimmer T, Lee KS, Srimathveeravalli G, Brown KT, Kingham PT, Fong Y, Durack JC, Sofocleous CT, Solomon SB. Percutaneous ablation of peribiliary tumors with irreversible electroporation. *J Vasc Interv Radiol* 2014; **25**: 112-118 [PMID: 24262034 DOI: 10.1016/j.jvir.2013.10.012]
- 215 **Deodhar A**, Dickfeld T, Single GW, Hamilton WC, Thornton RH, Sofocleous CT, Maybody M, Gónen M, Rubinsky B, Solomon SB. Irreversible electroporation near the heart: ventricular arrhythmias can be prevented with ECG synchronization. *AJR Am J Roentgenol* 2011; **196**: W330-W335 [PMID: 21343484 DOI: 10.2214/AJR.10.4490]
- 216 **Cannon R**, Ellis S, Hayes D, Narayanan G, Martin RC. Safety and early efficacy of irreversible electroporation for hepatic tumors in proximity to vital structures. *J Surg Oncol* 2013; **107**: 544-549 [PMID: 23090720 DOI: 10.1002/jso.23280]
- 217 **Cheung W**, Kavounoudias H, Roberts S, Szkandera B, Kemp W, Thomson KR. Irreversible electroporation for unresectable hepatocellular carcinoma: initial experience and review of safety and outcomes. *Technol Cancer Res Treat* 2013; **12**: 233-241 [PMID: 23369152 DOI: 10.7785/tcrt.2012.500317]
- 218 **Kingham TP**, Karkar AM, D'Angelica MI, Allen PJ, Dematteo RP, Getrajdman GI, Sofocleous CT, Solomon SB, Jarnagin WR, Fong Y. Ablation of perivascular hepatic malignant tumors with irreversible electroporation. *J Am Coll Surg* 2012; **215**: 379-387 [PMID: 22704820 DOI: 10.1016/j.jamcollsurg.2012.04.029]
- 219 **Thomson KR**, Cheung W, Ellis SJ, Federman D, Kavounoudias H, Loader-Oliver D, Roberts S, Evans P, Ball C, Haydon A. Investigation of the safety of irreversible electroporation in humans. *J Vasc Interv Radiol* 2011; **22**: 611-621 [PMID: 21439847 DOI: 10.1016/j.jvir.2010.12.014]
- 220 **Smith MT**, Ray CE. The treatment of primary and metastatic hepatic neoplasms using percutaneous cryotherapy. *Semin Intervent Radiol* 2006; **23**: 39-46 [PMID: 21326719 DOI: 10.1055/s-2006-939840]
- 221 **Huang YZ**, Zhou SC, Zhou H, Tong M. Radiofrequency ablation versus cryosurgery ablation for hepatocellular carcinoma: a meta-analysis. *Hepatogastroenterology* 2013; **60**: 1131-1135 [PMID: 23321123 DOI: 10.5754/hge121142]

- 222 **Pacella CM**, Francica G, Di Costanzo GG. Laser ablation for small hepatocellular carcinoma. *Radiol Res Pract* 2011; **2011**: 595627 [PMID: 22191028 DOI: 10.1155/2011/595627]
- 223 **Vogl TJ**, Straub R, Eichler K, Woitaschek D, Mack MG. Malignant liver tumors treated with MR imaging-guided laser-induced thermotherapy: experience with complications in 899 patients (2,520 lesions). *Radiology* 2002; **225**: 367-377 [PMID: 12409568 DOI: 10.1148/radiol.2252011171]
- 224 **Pacella CM**, Francica G, Di Lascio FM, Arienti V, Antico E, Caspani B, Magnolfi F, Megna AS, Pretolani S, Regine R, Sponza M, Stasi R. Long-term outcome of cirrhotic patients with early hepatocellular carcinoma treated with ultrasound-guided percutaneous laser ablation: a retrospective analysis. *J Clin Oncol* 2009; **27**: 2615-2621 [PMID: 19332729 DOI: 10.1200/JCO.2008.19.0082]
- 225 **Golfieri R**, Cappelli A, Cucchetti A, Piscaglia F, Carpenzano M, Peri E, Ravaioli M, D'Errico-Grigioni A, Pinna AD, Bolondi L. Efficacy of selective transarterial chemoembolization in inducing tumor necrosis in small (< 5 cm) hepatocellular carcinomas. *Hepatology* 2011; **53**: 1580-1589 [PMID: 21351114 DOI: 10.1002/hep.24246]
- 226 **Geschwind JF**. Chemoembolization for hepatocellular carcinoma: where does the truth lie? *J Vasc Interv Radiol* 2002; **13**: 991-994 [PMID: 12397119 DOI: 10.1016/S1051-0443(07)61862-4]
- 227 **Geschwind JF**, Ramsey DE, Choti MA, Thuluvath PJ, Huncharek MS. Chemoembolization of hepatocellular carcinoma: results of a metaanalysis. *Am J Clin Oncol* 2003; **26**: 344-349 [PMID: 12902882 DOI: 10.1097/01.COC.0000020588.20717.BB]
- 228 **Lo CM**, Ngan H, Tso WK, Liu CL, Lam CM, Poon RT, Fan ST, Wong J. Randomized controlled trial of transarterial lipiodol chemoembolization for unresectable hepatocellular carcinoma. *Hepatology* 2002; **35**: 1164-1171 [PMID: 11981766 DOI: 10.1053/jhep.2002.33156]
- 229 **Boily G**, Villeneuve JP, Lacoursière L, Chaudhury P, Couture F, Ouellet JF, Lapointe R, Goulet S, Gervais N. Transarterial embolization therapies for the treatment of hepatocellular carcinoma: CEPO review and clinical recommendations. *HPB (Oxford)* 2015; **17**: 52-65 [PMID: 24961288 DOI: 10.1111/hpb.12273]
- 230 **Forner A**, Llovet JM, Bruix J. Chemoembolization for intermediate HCC: is there proof of survival benefit? *J Hepatol* 2012; **56**: 984-986 [PMID: 22008737 DOI: 10.1016/j.jhep.2011.08.017]
- 231 **Llovet JM**, Real MI, Montañá X, Planas R, Coll S, Aponte J, Ayuso C, Sala M, Muchart J, Solà R, Rodés J, Bruix J. Arterial embolisation or chemoembolisation versus symptomatic treatment in patients with unresectable hepatocellular carcinoma: a randomised controlled trial. *Lancet* 2002; **359**: 1734-1739 [PMID: 12049862 DOI: 10.1016/S0140-6736(02)08649-X]
- 232 **Llovet JM**, Bruix J. Systematic review of randomized trials for unresectable hepatocellular carcinoma: Chemoembolization improves survival. *Hepatology* 2003; **37**: 429-442 [PMID: 12540794 DOI: 10.1053/jhep.2003.50047]
- 233 **Lammer J**, Malagari K, Vogl T, Pilleul F, Denys A, Watkinson A, Pitton M, Sergent G, Pfammatter T, Terraz S, Benhamou Y, Avajon Y, Gruenberger T, Pomoni M, Langenberger H, Schuchmann M, Dumortier J, Mueller C, Chevallier P, Lencioni R. Prospective randomized study of doxorubicin-eluting-bead embolization in the treatment of hepatocellular carcinoma: results of the PRECISION V study. *Cardiovasc Intervent Radiol* 2010; **33**: 41-52 [PMID: 19908093 DOI: 10.1007/s00270-009-9711-7]
- 234 **Xiong ZP**, Yang SR, Liang ZY, Xiao EH, Yu XP, Zhou SK, Zhang ZS. Association between vascular endothelial growth factor and metastasis after transcatheter arterial chemoembolization in patients with hepatocellular carcinoma. *Hepatobiliary Pancreat Dis Int* 2004; **3**: 386-390 [PMID: 15313674]
- 235 **Kobayashi N**, Ishii M, Ueno Y, Kisara N, Chida N, Iwasaki T, Toyota T. Co-expression of Bel-2 protein and vascular endothelial growth factor in hepatocellular carcinomas treated by chemoembolization. *Liver* 1999; **19**: 25-31 [PMID: 9928762 DOI: 10.1111/j.1478-3231.1999.tb00005.x]
- 236 **Jaeger HJ**, Mehning UM, Castañeda F, Hasse F, Blumhardt G, Loehelein D, Mathias KD. Sequential transarterial chemoembolization for unresectable advanced hepatocellular carcinoma. *Cardiovasc Intervent Radiol* 1996; **19**: 388-396 [PMID: 8994703 DOI: 10.1007/BF02577625]
- 237 **Varela M**, Real MI, Burrel M, Forner A, Sala M, Brunet M, Ayuso C, Castells L, Montañá X, Llovet JM, Bruix J. Chemoembolization of hepatocellular carcinoma with drug eluting beads: efficacy and doxorubicin pharmacokinetics. *J Hepatol* 2007; **46**: 474-481 [PMID: 17239480 DOI: 10.1016/j.jhep.2006.10.020]
- 238 **Golfieri R**, Giampalma E, Renzulli M, Cioni R, Bargellini I, Bartolozzi C, Breatta AD, Gandini G, Nani R, Gasparini D, Cucchetti A, Bolondi L, Trevisani F. Randomised controlled trial of doxorubicin-eluting beads vs conventional chemoembolisation for hepatocellular carcinoma. *Br J Cancer* 2014; **111**: 255-264 [PMID: 24937669 DOI: 10.1038/bjc.2014.199]
- 239 **Song MJ**, Chun HJ, Song do S, Kim HY, Yoo SH, Park CH, Bae SH, Choi JY, Chang UI, Yang JM, Lee HG, Yoon SK. Comparative study between doxorubicin-eluting beads and conventional transarterial chemoembolization for treatment of hepatocellular carcinoma. *J Hepatol* 2012; **57**: 1244-1250 [PMID: 22824821 DOI: 10.1016/j.jhep.2012.07.017]
- 240 **Gao S**, Yang Z, Zheng Z, Yao J, Deng M, Xie H, Zheng S, Zhou L. Doxorubicin-eluting bead versus conventional TACE for unresectable hepatocellular carcinoma: a meta-analysis. *Hepatology* 2013; **60**: 813-820 [PMID: 23282741 DOI: 10.5754/hge121025]
- 241 **Sherman M**. Hepatocellular carcinoma: screening and staging. *Clin Liver Dis* 2011; **15**: 323-324, vii-x [PMID: 21689616 DOI: 10.1016/j.cld.2011.03.003]
- 242 **Hong K**, Georgiades CS, Geschwind JF. Technology insight: Image-guided therapies for hepatocellular carcinoma--intra-arterial and ablative techniques. *Nat Clin Pract Oncol* 2006; **3**: 315-324 [PMID: 16757969 DOI: 10.1038/nceponc0512]
- 243 **Kennedy A**, Nag S, Salem R, Murthy R, McEwan AJ, Nutting C, Benson A, Espat J, Bilbao JI, Sharma RA, Thomas JP, Coldwell D. Recommendations for radioembolization of hepatic malignancies using yttrium-90 microsphere brachytherapy: a consensus panel report from the radioembolization brachytherapy oncology consortium. *Int J Radiat Oncol Biol Phys* 2007; **68**: 13-23 [PMID: 17448867 DOI: 10.1016/j.ijrobp.2006.11.060]
- 244 **Gramenzi A**, Golfieri R, Mosconi C, Cappelli A, Granito A, Cucchetti A, Marinelli S, Pettinato C, Erroi V, Fiumana S, Bolondi L, Bernardi M, Trevisani F. Yttrium-90 radioembolization vs sorafenib for intermediate-locally advanced hepatocellular carcinoma: a cohort study with propensity score analysis. *Liver Int* 2015; **35**: 1036-1047 [PMID: 24750853 DOI: 10.1111/liv.12574]
- 245 **Ettore GM**, Laurenzi A, Vennarecci G. Downstaging Hepatocellular Carcinoma with Yttrium-90 radioembolization: resection or transplantation? *Eur J Surg Oncol* 2014; **40**: 789-790 [PMID: 24572481 DOI: 10.1016/j.ejso.2014.01.017]
- 246 **Tohme S**, Sukato D, Chen HW, Amesur N, Zajko AB, Humar A, Geller DA, Marsh JW, Tsung A. Yttrium-90 radioembolization as a bridge to liver transplantation: a single-institution experience. *J Vasc Interv Radiol* 2013; **24**: 1632-1638 [PMID: 24160821 DOI: 10.1016/j.jvir.2013.07.026]
- 247 **Lencioni R**. Loco-regional treatment of hepatocellular carcinoma. *Hepatology* 2010; **52**: 762-773 [PMID: 20564355 DOI: 10.1002/hep.23725]
- 248 **Lu Z**, Wen F, Guo Q, Liang H, Mao X, Sun H. Radiofrequency ablation plus chemoembolization versus radiofrequency ablation alone for hepatocellular carcinoma: a meta-analysis of randomized-controlled trials. *Eur J Gastroenterol Hepatol* 2013; **25**: 187-194 [PMID: 23134976 DOI: 10.1097/MEG.0b013e32835a0a07]
- 249 **Ni JY**, Liu SS, Xu LF, Sun HL, Chen YT. Meta-analysis of radiofrequency ablation in combination with transarterial chemoembolization for hepatocellular carcinoma. *World J Gastroenterol* 2013; **19**: 3872-3882 [PMID: 23840128 DOI: 10.3748/wjg.v19.i24.3872]
- 250 **Jiang G**, Xu X, Ren S, Wang L. Combining transarterial chemoembolization with radiofrequency ablation for hepatocellular carcinoma. *Tumour Biol* 2014; **35**: 3405-3408 [PMID: 24277379 DOI: 10.1007/s13277-013-1449-9]

- 251 **Peng ZW**, Zhang YJ, Chen MS, Xu L, Liang HH, Lin XJ, Guo RP, Zhang YQ, Lau WY. Radiofrequency ablation with or without transcatheter arterial chemoembolization in the treatment of hepatocellular carcinoma: a prospective randomized trial. *J Clin Oncol* 2013; **31**: 426-432 [PMID: 23269991 DOI: 10.1200/JCO.2012.42.9936]
- 252 **Hurwitz MD**, Hansen JL, Prokopios-Davos S, Manola J, Wang Q, Bornstein BA, Hynynen K, Kaplan ID. Hyperthermia combined with radiation for the treatment of locally advanced prostate cancer: long-term results from Dana-Farber Cancer Institute study 94-153. *Cancer* 2011; **117**: 510-516 [PMID: 20886629 DOI: 10.1002/cncr.25619]
- 253 **Zagar TM**, Oleson JR, Vujaskovic Z, Dewhurst MW, Craciunescu OI, Blackwell KL, Prosnitz LR, Jones EL. Hyperthermia combined with radiation therapy for superficial breast cancer and chest wall recurrence: a review of the randomised data. *Int J Hyperthermia* 2010; **26**: 612-617 [PMID: 20849256 DOI: 10.3109/02656736.2010.487194]
- 254 **Goldberg SN**. Science to practice: Can we expand focal interventional oncologic ablation treatments into an effective systemic therapy? *Radiology* 2013; **267**: 321-323 [PMID: 23610091 DOI: 10.1148/radiol.13130140]
- 255 **Sundararajan A**, Dodd GD, Bao A, Phillips WT, McManus LM, Prihoda TJ, Goins BA. Chemoradionuclide therapy with 186Re-labeled liposomal doxorubicin in combination with radiofrequency ablation for effective treatment of head and neck cancer in a nude rat tumor xenograft model. *Radiology* 2011; **261**: 813-823 [PMID: 22025735 DOI: 10.1148/radiol.11110361]
- 256 **Li D**, Kang J, Golas BJ, Yeung VW, Madoff DC. Minimally invasive local therapies for liver cancer. *Cancer Biol Med* 2014; **11**: 217-236 [PMID: 25610708 DOI: 10.7497/j.issn.2095-3941.2014.04.001]
- 257 **Llovet JM**, Ricci S, Mazzaferro V, Hilgard P, Gane E, Blanc JF, de Oliveira AC, Santoro A, Raoul JL, Forner A, Schwartz M, Porta C, Zeuzem S, Bolondi L, Greten TF, Galle PR, Seitz JF, Borbath I, Häussinger D, Giannaris T, Shan M, Moscovici M, Voliotis D, Bruix J. Sorafenib in advanced hepatocellular carcinoma. *N Engl J Med* 2008; **359**: 378-390 [PMID: 18650514 DOI: 10.1056/NEJMoa0708857]
- 258 **Cheng AL**, Kang YK, Chen Z, Tsao CJ, Qin S, Kim JS, Luo R, Feng J, Ye S, Yang TS, Xu J, Sun Y, Liang H, Liu J, Wang J, Tak WY, Pan H, Burock K, Zou J, Voliotis D, Guan Z. Efficacy and safety of sorafenib in patients in the Asia-Pacific region with advanced hepatocellular carcinoma: a phase III randomised, double-blind, placebo-controlled trial. *Lancet Oncol* 2009; **10**: 25-34 [PMID: 19095497 DOI: 10.1016/S1470-2045(08)70285-7]

**P- Reviewer:** Yoshioka K **S- Editor:** Ma YJ

**L- Editor:** A **E- Editor:** Liu XM





Published by **Baishideng Publishing Group Inc**

8226 Regency Drive, Pleasanton, CA 94588, USA

Telephone: +1-925-223-8242

Fax: +1-925-223-8243

E-mail: [bpgooffice@wjgnet.com](mailto:bpgooffice@wjgnet.com)

Help Desk: <http://www.wjgnet.com/esps/helpdesk.aspx>

<http://www.wjgnet.com>



ISSN 1007-9327



9 771007 932045