



# NILDE

Network Inter-Library Document Exchange

Il presente documento viene fornito attraverso il servizio NILDE dalla Biblioteca fornitrice, nel rispetto della vigente normativa sul Diritto d'Autore (Legge n.633 del 22/4/1941 e successive modifiche e integrazioni) e delle clausole contrattuali in essere con il titolare dei diritti di proprietà intellettuale.

**La Biblioteca fornitrice** garantisce di aver effettuato copia del presente documento assolvendo direttamente ogni e qualsiasi onere correlato alla realizzazione di detta copia.

**La Biblioteca richiedente** garantisce che il documento richiesto è destinato ad un suo utente, che ne farà uso esclusivamente personale per scopi di studio o di ricerca, ed è tenuta ad informare adeguatamente i propri utenti circa i limiti di utilizzazione dei documenti forniti mediante il servizio NILDE.

**La Biblioteca richiedente** è tenuta al rispetto della vigente normativa sul Diritto d'Autore e in particolare, ma non solo, a consegnare al richiedente un'unica copia cartacea del presente documento, distruggendo ogni eventuale copia digitale ricevuta.

**Biblioteca richiedente:** Biblioteca del Polo Policlinico

**Data richiesta:** 20/04/2020 10:25:52

**Biblioteca fornitrice:** Biblioteca della Scuola di Scienze Mediche e Farmaceutiche. Sede di Medicina e Chirurgia

**Data evasione:** 20/04/2020 11:04:15

**Titolo rivista/libro:** Indian Journal of Dermatology Venereology and Leprology

**Titolo articolo/sezione:** Photodynamic therapy for acne conglobata of the buttocks: Effective antiinflammatory treatment with good cosmetic outcome

**Autore/i:** Borgia F, Vaccaro M, Giuffrida R, Cannavò SP.

**ISSN:** 0973-3922

**DOI:** 10.4103/ijdv.IJDVL\_683\_17

**Anno:** 2018

**Volume:** 84

**Fascicolo:** 5

**Editore:**

**Pag. iniziale:** 617

**Pag. finale:** 619

## Photodynamic therapy for acne conglobata of the buttocks: Effective antiinflammatory treatment with good cosmetic outcome

Sir,

Acne conglobata is an uncommon difficult-to-treat severe inflammatory acne variant that affects deep skin tissue, causing swelling, bleeding, purulent discharge and pain.<sup>1</sup> Several therapeutic options have been used with variable results, often leaving residual disfiguring scars. Here, we report a case of histologically proven acne conglobata in a 16-year-old Caucasian man with a 5-month history of sudden-onset painful nodular cystic eruption on the buttocks. History did not reveal any drug usage or predisposing hereditary factors. Previous treatments with oral minocycline (4 weeks), topical retinoid and systemic isotretinoin (0.5 mg/kg/d) were ineffective. Examination revealed multiple inflamed nontender suppurative nodules localized on the buttocks [Figure 1a] and lateral aspects of the pelvis, with spontaneous bleeding and purulent discharge. No lesions were detected elsewhere on physical examination. Such protracted painful eruption severely affected the patient's quality of life, interfering with daily activities. We, therefore, decided to start photodynamic therapy as monotherapy because of its antiinflammatory and antimicrobial effects as well as its ability to reduce the risk of disfiguring scars. After a written informed consent, 10% 5-aminolaevulinic acid in polyethylene glycol ointment was applied in occlusion for 3 h on the buttocks; irradiation was

then applied with diode red light at 630 nm (S630, Alpha Strumenti, Milan, Italy) for 8 min, with a total light dose of 75 J/cm<sup>2</sup>. Fluorescence, detected using violet light at 405 nm, was localized with high intensity, especially in inflammatory nodules. The patient was treated every 2 weeks for a total of six treatments over a period of three months. Intense pain and inflammation were reported after the first two sessions (visual analog scale mean values of 10/10 and 8/10, respectively) and were managed with oral paracetamol and topical application of corticosteroids, while only minimal discomfort was recorded at the successive exposures. At the end of the treatment period, a remarkable improvement of the clinical features was observed, with healing of the cutaneous nodules and no noteworthy adverse event [Figure 1b]. At 6 months' follow-up, a lasting remission with favorable cosmetic results was observed [Figure 1c]. Photodynamic therapy typically involves topical application of the photosensitizing prodrug aminolaevulinic acid or its methylated ester, converted by the heme biosynthetic pathway predominantly to protoporphyrin IX and activated by light of appropriate wavelength to produce reactive oxygen species, especially singlet oxygen, which trigger apoptosis and necrosis of target cells. In addition to established indications in nonmelanoma skin cancer, photodynamic therapy is used with increasing

frequency in several inflammatory dermatoses as well as in wound healing.<sup>2-4</sup> The greater absorption of aminolaevulinic acid together with higher production of protoporphyrin IX in hair follicles compared to other tissues seems to be the mechanism of action in inflammatory diseases of the pilosebaceous unit such as chronic folliculitis and hidradenitis suppurativa.<sup>4,6</sup> In our patient, photodynamic therapy was very effective to prevent scars as well. This striking cosmetic outcome may be the consequence of a

combination of antiinflammatory effect, immunomodulatory activity and keratinocyte photoactivation with subsequent paracrine induction of matrix metalloproteinases production in fibroblasts, favoring the remodeling of the dermal matrix architecture.<sup>4</sup> The good tolerability, high safety profile and absence of durable side effects render photodynamic therapy a valid therapeutic option for acne conglobata; its use at an early stage of the disease may accelerate resolution of the cystic lesions, reducing the risk and the severity of disfiguring scars.

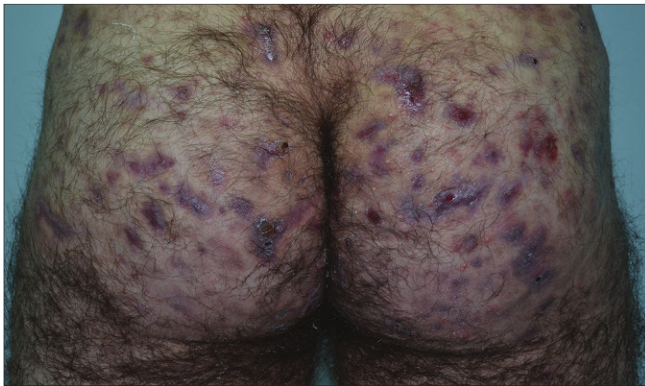


Figure 1a: Skin lesions before photodynamic therapy

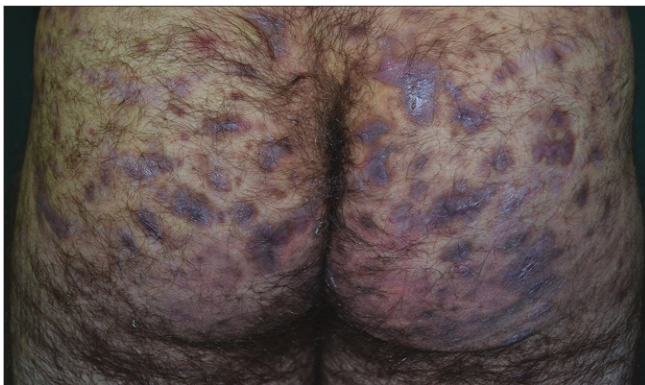


Figure 1b: Skin lesions at the end of the treatment period

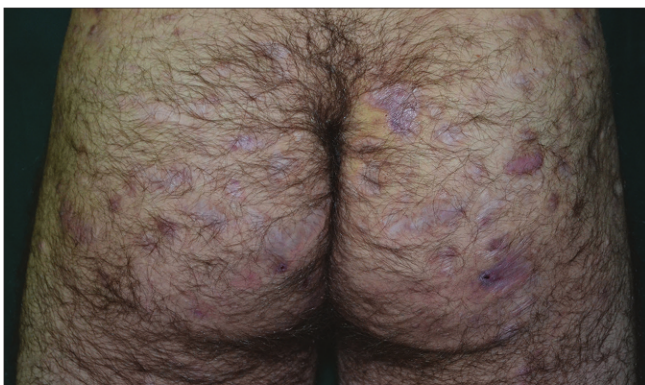

Figure 1c: Skin lesions at 6 months' follow-up

#### Declaration of patient consent

The authors certify that they have obtained all appropriate patient consent forms. In the form, the patient has given his consent for his images and other clinical information to be reported in the journal. The patient understands that name and initials will not be published and due efforts will be made to conceal identity, but anonymity cannot be guaranteed.

#### Financial support and sponsorship

Nil.

#### Conflicts of interest

There are no conflicts of interest.

**Francesco Borgia, Mario Vaccaro,  
Roberta Giuffrida, Serafinella P. Cannavò**

Department of Clinical and Experimental Medicine, Dermatology Unit,  
University Hospital "G. Martino," Messina, Italy

**Correspondence:** Dr. Francesco Borgia,  
Department of Clinical and Experimental Medicine,  
Dermatology Unit, University Hospital "G. Martino,"  
Via Consolare Valeria, Messina 98125, Italy.  
E-mail: fborgia@unime.it

#### References

1. Wang HW, Lv T, Zhang LL, Guo MX, Stepp H, Yang K, *et al.* Prospective study of topical 5-aminolevulinic acid photodynamic therapy for the treatment of moderate to severe acne vulgaris in Chinese patients. *J Cutan Med Surg* 2012;16:324-33.
2. Borgia F, Vaccaro M, Cantavenera LG, Aragona E, Cannavò SP. Ulcerative necrobiosis lipoidica successfully treated with photodynamic therapy: Case report and literature review. *Photodiagnosis Photodyn Ther* 2014;11:516-8.
3. Borgia F, Vaccaro M, Foti A, Giuffrida R, Cannavò SP. Zoon's balanitis successfully treated with photodynamic therapy: Case report and literature review. *Photodiagnosis Photodyn Ther* 2016;13:347-9.
4. Borgia F, Giuffrida R, Vaccaro M, Lentini M, Cannavò SP. Photodynamic therapy in lupus miliaris disseminatus faciei's scars. *Dermatol Ther* 2016;29:320-4.
5. Andino Navarrete R, Hasson Nisis A, Parra Cares J. Effectiveness of 5-aminolevulinic acid photodynamic therapy in the treatment of hidradenitis suppurativa: A report of 5 cases. *Actas Dermosifiliogr* 2014;105:614-7.

6. Borgia F, Saitta C, Vaccaro M, Franzè MS, Lentini M, Cannavò SP, *et al.* Nodular-cystic eruption in course of sorafenib administration for hepatocarcinoma: An unconventional skin reaction requiring unconventional treatment. *Int J Immunopathol Pharmacol* 2017;30:327-31.

Access this article online	
<b>Quick Response Code:</b>	<b>Website:</b> www.ijdvl.com
	<b>DOI:</b> 10.4103/ijdvl.IJDVL_683_17

---

This is an open access journal, and articles are distributed under the terms of the Creative Commons Attribution-NonCommercial-ShareAlike 4.0 License, which allows others to remix, tweak, and build upon the work non-commercially, as long as appropriate credit is given and the new creations are licensed under the identical terms.

**How to cite this article:** Borgia F, Vaccaro M, Giuffrida R, Cannavò SP. Photodynamic therapy for acne conglobata of the buttocks: Effective antiinflammatory treatment with good cosmetic outcome. *Indian J Dermatol Venereol Leprol* 2018;84:617-9.

**Received:** September, 2017. **Accepted:** April, 2018.

© 2018 Indian Journal of Dermatology, Venereology and Leprology | Published by Wolters Kluwer - Medknow

© 2018. This work is published under

<https://creativecommons.org/licenses/by-nc-sa/4.0/> (the "License").

Notwithstanding the ProQuest Terms and Conditions, you may use this content  
in accordance with the terms of the License.