



Available online at www.sciencedirect.com

ScienceDirect

journal homepage: <http://www.kjms-online.com>



Original Article

Comparison of EMG signals recorded by surface electrodes on endotracheal tube and thyroid cartilage during monitored thyroidectomy



Feng-Yu Chiang ^{a,b}, I-Cheng Lu ^{b,c}, Pi-Ying Chang ^c, Gianlorenzo Dionigi ^d, Gregory W. Randolph ^e, Hui Sun ^f, Kang-Dae Lee ^g, Kyung Tae ^h, Yong Bae Ji ^h, Sung Won Kim ^g, Hyoung Shin Lee ^g, Che-Wei Wu ^{a,b,*}

^a Department of Otolaryngology-Head and Neck Surgery, Kaohsiung Medical University Hospital, Kaohsiung Medical University, Kaohsiung, Taiwan

^b Faculty of Medicine, College of Medicine, Kaohsiung Medical University, Kaohsiung, Taiwan

^c Department of Anesthesiology, Kaohsiung Medical University Hospital, Kaohsiung Medical University, Kaohsiung, Taiwan

^d Division for Endocrine Surgery, Department of Human Pathology in Adulthood and Childhood “G. Barresi”, University Hospital – Policlinico “G. Martino”, University of Messina, Via C. Valeria 1, 98125, Messina, Italy

^e Division of Thyroid and Parathyroid Endocrine Surgery, Department of Otolaryngology, Massachusetts Eye and Ear Infirmary, Department of Otolaryngology, Harvard Medical School, Boston, MA, USA

^f Division of Thyroid Surgery, China-Japan Union Hospital of Jilin University, Jilin Provincial Key Laboratory of Surgical Translational Medicine, Changchun, Jilin Province, China

^g Department of Otolaryngology-Head and Neck Surgery, Kosin University, College of Medicine, Busan, South Korea

^h Department of Otolaryngology-Head and Neck Surgery, College of Medicine, Hanyang University, Seoul, South Korea

Received 27 March 2017; accepted 15 May 2017

Available online 22 July 2017

KEYWORDS

Electromyography recording;
Intraoperative neural monitoring;

Abstract A variety of electromyography (EMG) recording methods were reported during intraoperative neural monitoring (IONM) of recurrent laryngeal nerve (RLN) in thyroid surgery. This study compared two surface recording methods that were obtained by electrodes on endotracheal tube (ET) and thyroid cartilage (TC). This study analyzed 205 RLNs at risk in 110 patients undergoing monitored thyroidectomy. Each patient was intubated with an EMG ET during general anesthesia. A pair of single needle electrode was inserted obliquely into the TC lamina on each

Conflicts of interest: All authors declare no conflicts of interest.

* Corresponding author. Department of Otolaryngology-Head and Neck Surgery, Kaohsiung Medical University Hospital, Kaohsiung Medical University, 100 TzYou 1st Road, Kaohsiung, 807, Taiwan.

E-mail addresses: cwwu@kmu.edu.tw, kmuent@yahoo.com.tw (C.-W. Wu).

<http://dx.doi.org/10.1016/j.kjms.2017.06.014>

1607-551X/ Copyright © 2017, Kaohsiung Medical University. Published by Elsevier Taiwan LLC. This is an open access article under the CC BY-NC-ND license (<http://creativecommons.org/licenses/by-nc-nd/4.0/>).

Recurrent laryngeal nerve;
Vocal cord paralysis;
Thyroid surgery

side. Standard IONM procedure was routinely followed, and EMG signals recorded by the ET and TC electrodes at each step were compared. In all nerves, evoked laryngeal EMG signals were reliably recorded by the ET and TC electrodes, and showed the same typical waveform and latency. The EMG signals recorded by the TC electrodes showed significantly higher amplitudes and stability compared to those by the ET electrodes. Both recording methods accurately detected 7 partial loss of signal (LOS) and 2 complete LOS events caused by traction stress, but only the ET electrodes falsely detected 3 LOS events caused by ET displacement during surgical manipulation. Two patients with true complete LOS experienced temporary RLN palsy postoperatively. Neither permanent RLN palsy, nor complications from ET or TC electrodes were encountered in this study. Both electrodes are effective and reliable for recording laryngeal EMG signals during monitored thyroidectomy. Compared to ET electrodes, TC electrodes obtain higher and more stable EMG signals as well as fewer false EMG results during IONM.

Copyright © 2017, Kaohsiung Medical University. Published by Elsevier Taiwan LLC. This is an open access article under the CC BY-NC-ND license (<http://creativecommons.org/licenses/by-nc-nd/4.0/>).

Introduction

Intraoperative neural monitoring (IONM) has been widely used to verify the functional integrity of recurrent laryngeal nerve (RLN) during thyroid surgery. Various electrodes placements for recording electromyography (EMG) during monitored thyroidectomy have been reported in the literature, including intramuscular placements (e.g., intramuscular vocal cord electrodes placed endoscopically or through the cricothyroid membrane), and surface placements (e.g., laryngeal electrodes placed at the post-cricoid area or attached to an endotracheal tube (ET)) [1]. In recent years, ET-based surface electrodes have gained more popularity because of the essential advantages of their ease of setup and use, noninvasive nature, and capacity to derive larger areas of the target muscle [1]. However, limitations encountered during clinical use of ET-based surface electrodes, including the followings:

1. Contact between electrodes and vocal cords must be maintained for a high-quality recording. Because of the large size of the ET, however, pressure must be applied on the glottis to maintain optimal contact during surgery. Additionally, if the selected EMG ET is too large for intubation, it must be replaced with a smaller one. Conversely, a smaller EMG ET may not provide sufficient contact between the surface electrodes and vocal cords. In this situation, the initial EMG amplitude will be very low [1].
2. Verification of proper electrodes-cords position after neck positioning is necessary with direct laryngoscopy, laryngofiberscopy or Glidescope. However, repositioning an EMG ET is troublesome and time-consuming for anesthesiologists [2,3].
3. Rotation, upward displacement or downward displacement of the EMG ET during surgical manipulation may cause an unstable signal due to insufficient contact between electrodes and vocal folds [4]. Extreme displacement of the EMG ET can substantially decrease the EMG amplitude or cause a false loss of signal (LOS) owing to poor electrodes-cords contact [5]. Monitor dysfunction rates reportedly range from 3.8% to 23%, and the main cause of dysfunction is a malpositioned EMG ET

[3,6–10]. In a study by Dionigi et al. [10], 10% of thyroid surgery patients required intraoperative adjustment of the ET due to poor electrodes-vocal cords contact. In our previous study [3], intraoperative monitor dysfunction caused by a malpositioned EMG ET occurred in 6% of thyroidectomy patients, even though the proper electrodes position was routinely verified by laryngofiberscopic examination after neck positioning.

4. The EMG ET may not be applicable in patients who have had tracheostomy or in patients who require tracheostomy for general anesthesia. Additionally, the EMG ET may be inapplicable in the rare case of a trachea severely compressed by a huge goiter.
5. If the EMG ET is not routinely used, replacing a standard ET with an EMG ET may be difficult in case IONM is unexpectedly required during surgery.

Anatomically, the thyroarytenoid (TA) muscles are attached to the anterior part of the inner surface of the thyroid cartilage (TC). Therefore, electrodes on the TC are an alternative means to assess the function of TA muscle and RLN. Additionally, recording systems that use TC electrodes are theoretically more stable than those that use ET electrodes because the anatomic relationship between the TC electrodes and TA muscles is unaffected by surgical manipulation. Recently, Van Slycke et al. [11] reported their preliminary experience in the placement of acquisition electrodes on TC for IONM of RLN during thyroidectomy. However, the clinical value of using TC electrodes for IONM has not been investigated comprehensively, and their advantages and disadvantages in comparison with ET electrodes have not been reported. Therefore, this study compared surface EMG recordings between methods that use ET electrodes and those that use TC electrodes.

Methods

Patients

This study analyzed 110 surgical procedures (13 unilateral total lobectomies and 97 total thyroidectomies) performed for various thyroid diseases (57 benign and 53 malignant).

All procedures were performed by the same surgeon (Chiang, FY) in 110 patients (22 men and 88 women; age range, 23–78 years; mean age, 52 years) from January to December, 2016. Two nerves were excluded from analysis due to preoperative vocal cord palsy. Thus, 205 nerves at risk were enrolled in this study.

The standard procedures for equipment setup and anesthesia were performed by the IONM team of Kaohsiung Medical University Hospital [12]. All patients were intubated with a Nerve Integrity Monitor Standard Reinforced Electromyography Endotracheal Tube (ID, 6.0 mm for women and 7.0 mm for men) (Metronic Xomed, Jacksonville, FL, USA). The proper position of endotracheal surface electrodes was routinely verified by laryngofiberoscopy after neck positioning (Fig. 1A). During surgery, a single needle electrode (Metronic Xomed, Jacksonville, FL, USA) was obliquely inserted into each side of the lateral TC after completion of the standard procedure for thyroid pyramidal lobe dissection (Video). The wires of needle electrodes were fixed on pre-laryngeal soft tissue and surgical drape with sutures (Fig. 1B). The resultant EMG signals detected

by ET electrodes appeared on the channel 1 and 2 of monitoring screen, and those detected by TC electrodes appeared on the channel 3 during stimulation of the vagus nerve (VN) (Fig. 1C) or RLN (Fig. 1D).

Supplementary video related to this article can be found at <http://dx.doi.org/10.1016/j.kjms.2017.06.014>.

In all cases, standard IONM procedures were strictly followed, and EMG signals with the largest amplitudes (V_1 - R_1 - R_2 - V_2) were obtained and registered at each step [8,12]. In addition to the conventional intraoperative four-step procedure, the exposed RLN was routinely tested at the lowest proximal end (R_{2p} signal) and at the most distal end near the laryngeal entry point (R_{2d} signal) with a supra-maximal stimulation level after complete dissection of the RLN to detect partial nerve injury with incomplete LOS [13,14]. If the R_{2p}/R_{2d} reduction (% difference in amplitude between proximal and distal RLN stimulation) reached >20%, the exposed RLN was carefully checked to pinpoint the injured area of the nerve. The EMG signals detected by ET and TC electrodes were compared at each step. Data

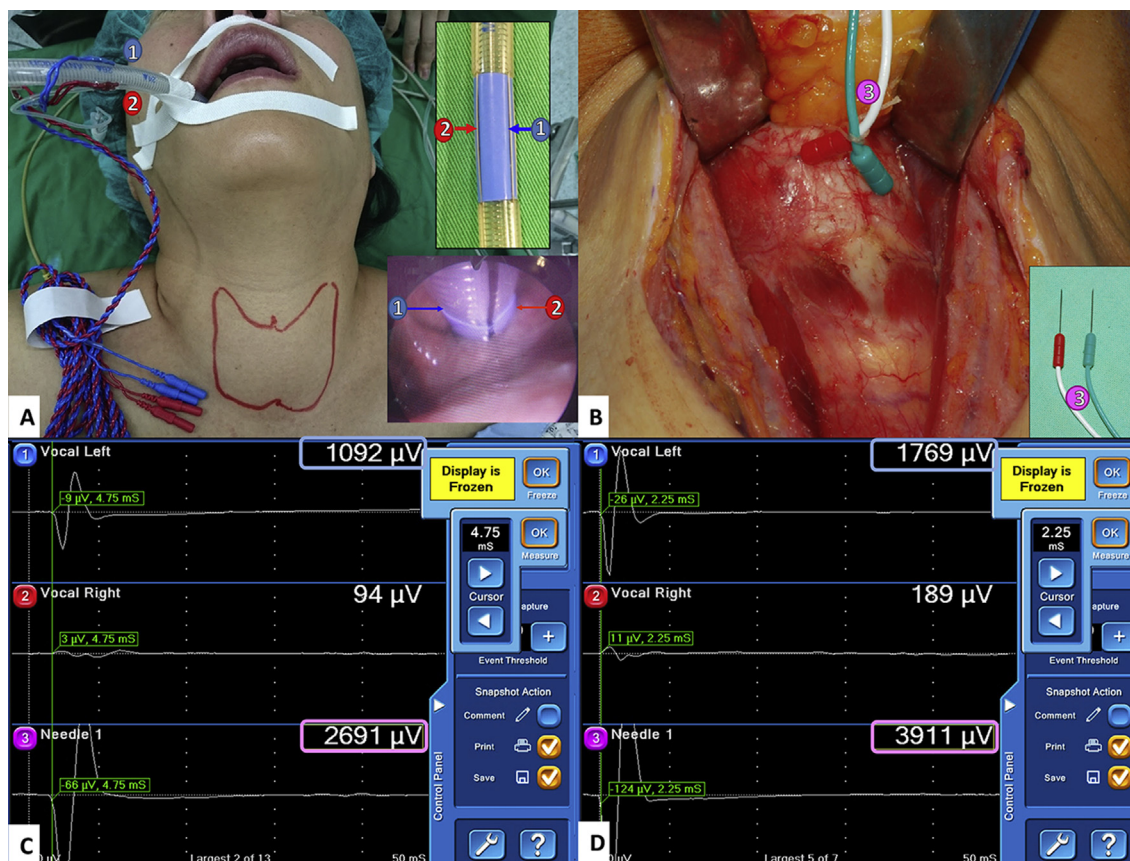


Figure 1. Placement of endotracheal tube (ET) and thyroid cartilage (TC) electrodes and their electromyography (EMG) signal recordings. (A) An NIM® Standard Reinforced EMG ET (ID, 6.0 mm/7.0 mm for women/men, Medtronic, Jacksonville, FL) was inserted for general anesthesia. The EMG ET was fixed after confirming that the exposed electrodes (blue segment) were in good contact with the vocal folds. The outline of thyroid tumor was marked with red color line. (B) After resection of the pyramidal lobe, a pair of subdermal needle electrodes (length, 12.0 mm; diameter, 0.4 mm; Medtronic, Jacksonville, FL) was inserted into the sub-perichondrium of the lateral TC. The electrode wires were then fixed on pre-laryngeal soft tissue with sutures. (C) After left vagus nerve and (D) left recurrent laryngeal nerve (RLN) stimulation, the resultant EMG signals detected by ET electrodes appeared on channel 1 and 2 of the monitoring screen, and those detected by TC electrodes appeared on channel 3. The ET and TC electrodes both showed typical vagal or RLN evoked laryngeal EMG waveforms.

collection included EMG waveform, amplitude and latency, and signal change after RLN injury.

In all patients, vocal cord mobility was video-recorded pre- and postoperatively with a flexible laryngofibroscope. Patients who revealed vocal cord dysfunction were followed up 2 weeks later and then every 4 weeks thereafter until recovery. Dysfunction that persisted for 6 months after surgery was considered permanent.

Results

Both the ET and TC electrodes reliably recorded evoked laryngeal EMG signals. The two electrode types typically obtained similar EMG waveforms and latencies for the 205 nerves in this study (Fig. 1C and D). At baseline, however, the TC electrodes obtained significantly higher EMG amplitudes. The mean pre-dissection EMG amplitudes recorded from TC and ET electrodes were $1652 \pm 848 \mu\text{V}$ versus $724 \pm 558 \mu\text{V}$ ($p < 0.001$) for V_1 signal, and $2225 \pm 1106 \mu\text{V}$ versus $960 \pm 677 \mu\text{V}$ ($p < 0.001$) for R_1 signal, respectively. Additionally, the TC electrodes obtained an initial V_1 signal amplitude $< 500 \mu\text{V}$ in only 2 (1%) nerves, whereas the ET electrodes obtained an initial V_1 signal amplitude $< 500 \mu\text{V}$ in 74 (36%) nerves.

After RLN dissection, a weak or disrupted point of nerve conduction was detected at the region of ligament of Berry (LOB) in 9 nerves. Both electrode types showed similar amplitude reductions (R_{2p}/R_{2d} ratio) (Fig. 2, and Fig. 3A–C). Among these 9 nerves, 7 nerves with partial LOS ($R_{2p} > 100 \mu\text{V}$) all showed free postoperative vocal cord mobility (Fig. 2); the remaining 2 nerves with complete LOS ($R_{2p} < 100 \mu\text{V}$) before wound closure developed temporary vocal palsy postoperatively. Neither permanent RLN palsy, nor complications from the use ET or TC electrodes were observed in this study.

In the 196 nerves without evidence of injury (no weak point of nerve conduction on the exposed RLN and normal postoperative vocal cord mobility), the mean post-dissection EMG amplitudes recorded from the TC and ET electrodes were $2379 \pm 1099 \mu\text{V}$ versus $1008 \pm 853 \mu\text{V}$ ($p < 0.001$) for R_2 signal, and $1685 \pm 800 \mu\text{V}$ versus $735 \pm 639 \mu\text{V}$ ($p < 0.001$) for V_2 signal, respectively. Overall, EMG amplitudes detected from TC electrodes showed significantly higher than those detected from ET electrodes at each step (V_1 - R_1 - R_2 - V_2).

Further comparisons of the final and initial signals (V_2/V_1) in the 196 nerves without evidence of injury revealed the following three patterns:

- (1) Signals were unchanged (defined as V_2/V_1 from 80% to 120%) in 161 (82%) nerves monitored by TC electrodes, whereas signals were unchanged in only 98 (50%) nerves monitored by ET electrodes;
- (2) Signals were increased (defined as $V_2/V_1 > 120\%$) in 50 (26%) nerves monitored by ET electrodes, whereas signals were increased in only 33 (17%) nerves monitored by TC electrodes;
- (3) Signals were decreased (defined as $V_2/V_1 < 80\%$) in 48 nerves (24%) nerves monitored by ET electrodes, whereas signals were decreased in only two (1%) nerves monitored by TC electrodes.

Overall, the EMG signals detected by TC electrodes were more stable than those detected by ET electrodes (Fig. 2). Substantial amplitude decreases (defined as $> 50\%$) occurred in 20 (10.2%) nerves monitored by ET electrodes, but in none of the nerves monitored by TC electrodes (Fig. 2). Notably, false LOS (EMG $< 100 \mu\text{V}$) events occurred in 3 of the 20 nerves with substantial amplitude decrease monitored by ET electrodes. All false LOS events resulted

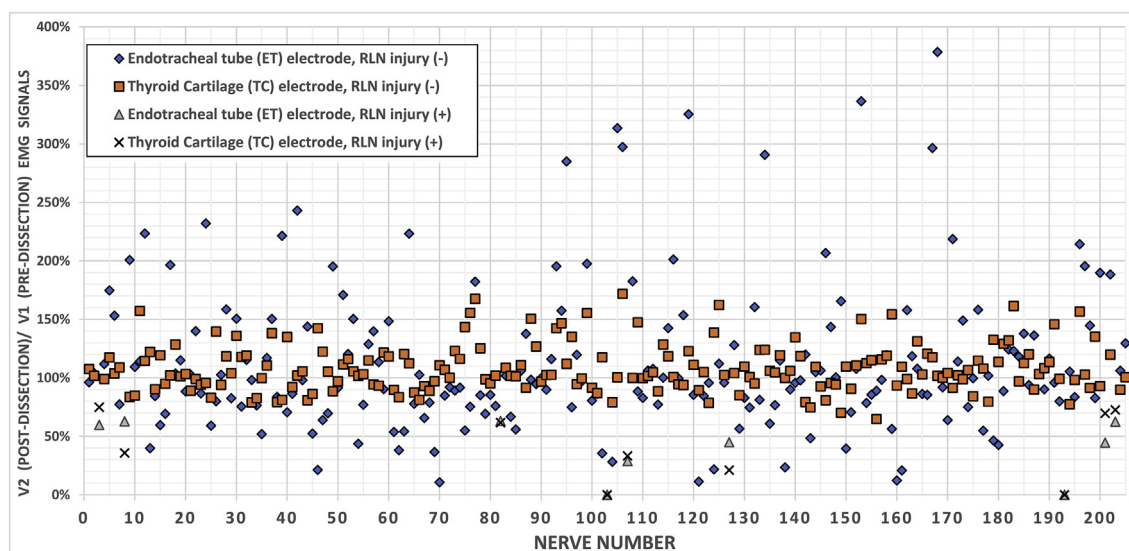


Figure 2. Comparison of the final EMG signal (V_2) and initial EMG signal (V_1) recorded by ET and TC electrodes in 205 RLNs with and without evidence of injury. In the nine nerves with evidence of RLN traction injury (Nerve No. 2, 8, 82, 103, 107, 127, 193, 201 and 203), both electrodes correctly detected the adverse EMG change and showed similar V_2/V_1 EMG signal results (Nerve No. 103 and 193 showed no recovery, but the remaining 7 nerves showed recovery). In the remaining 196 nerves without evidence of injury, the EMG signals obtained by TC electrodes were more stable and more consistent than those obtained by ET electrodes.

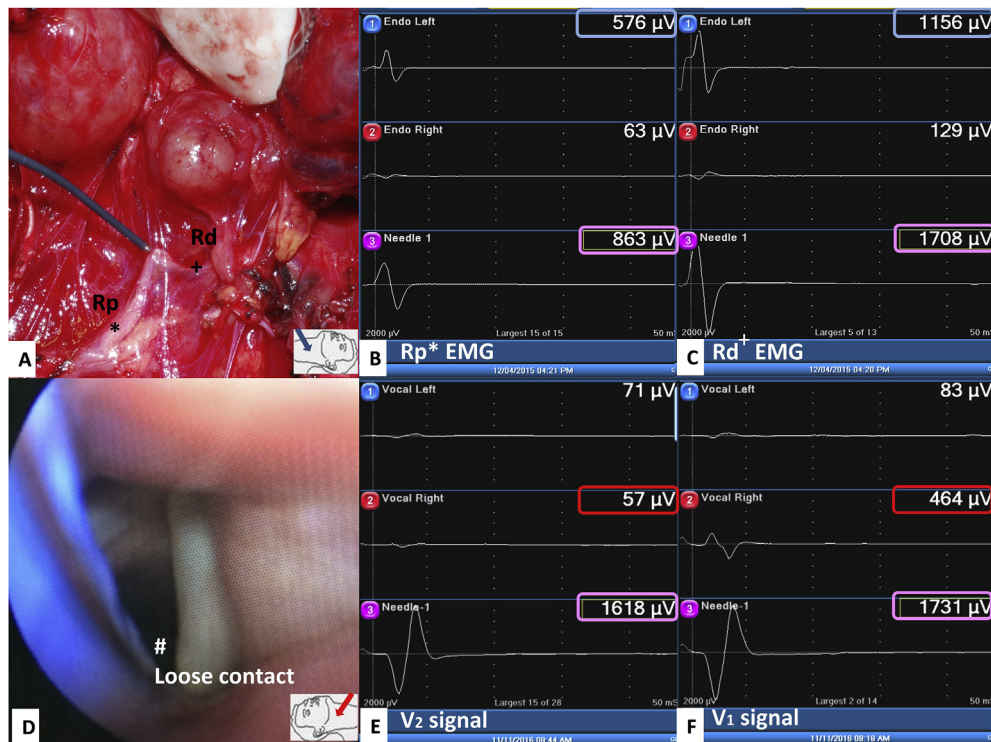


Figure 3. Comparison of changes in EMG recordings obtained by ET electrodes and TC electrodes after RLN traction injury (A–C) and after ET displacement (D–F). (A) After left RLN traction injury occurs at region of ligament of Berry, and (B) the ET and TC electrodes both recorded amplitude loss of approximately 50% after stimulation of the proximal RLN (Rp*) in comparison with (C) EMG evoked from the distal RLN (Rd+). (D) Upward displacement of the ET and loose contact between the right vocal cord (#) and ET electrodes occurred during surgical manipulation, and (E) the post-dissection EMG recorded by the right ET electrodes showed a loss of signal (channel 2 = 57 μV , <100 μV). However, the post-dissection EMG signal recorded by the TC electrodes (channel 3 = 1618 μV) did not differ from the baseline EMG signal (F, channel 3 = 1731 μV).

from ET displacement during the surgical manipulation (Fig. 3D–F).

Discussion

RLN injury remains a major cause of morbidity after thyroid surgery and can substantially affect quality of life. A major change in thyroid surgery in the past decade is the widespread use of IONM as adjunct to the standard practice of visually identifying the RLN [1]. This study compared surface EMG recordings obtained by ET electrodes (Fig. 1A) and by TC electrodes (Fig. 1B). The comparisons showed that both electrode types reliably recorded evoked laryngeal EMG signals, and obtained similar waveforms and latencies in all nerves (Fig. 1C and D). In the nine nerve injuries caused by traction stress at the region of LOB, the two electrode types reliably recorded similar EMG amplitude reductions (R_{2p}/R_{2d} ratio) (Fig. 2 and Fig. 3A–C). That is, for performing IONM, TC electrodes were as reliable as conventional ET electrodes.

Studies of ET-based IONM systems usually report a high negative predictive value of 92–100% but a low and highly variable positive predictive value of 10–90% [15]. Therefore, patients with an intact EMG signal after thyroid resection are generally expected to have normal vocal

function. Conversely, a substantial decrease or loss of signal has extremely unpredictable outcomes, ranging from normal vocal mobility to temporary or permanent cord palsy. Possible explanations for this high variability include EMG ET movement and changes in the contact between the ET electrodes and vocal cords during surgical manipulation [5]. Therefore, maintaining good contact between ET electrodes and vocal cords is essential for eliciting high and stable EMG amplitudes during IONM. According to the International Standards Guideline Statement, the larynx should be intubated with the largest EMG endotracheal tube considered safe, as this will optimize electrode contact with the vocal cords [1]. However, selecting a proper size of EMG tube for each patient can be difficult. For example, one male patient in this study required a smaller size 6.0 EMG tube after a failed intubation with a size 7.0 EMG tube.

Our experience in this study showed that, in contrast with the troublesome and time-consuming procedures for adjusting ET electrodes and verifying their proper position, the setup procedure for TC electrodes can be performed quickly and easily (Video 1). Although it was not an outcome measure in this study, setup time was around 2 min in all cases. The electrodes were not easily dislodged during surgery and could be directly visualized at all time, which provided further confirmation of their location. The

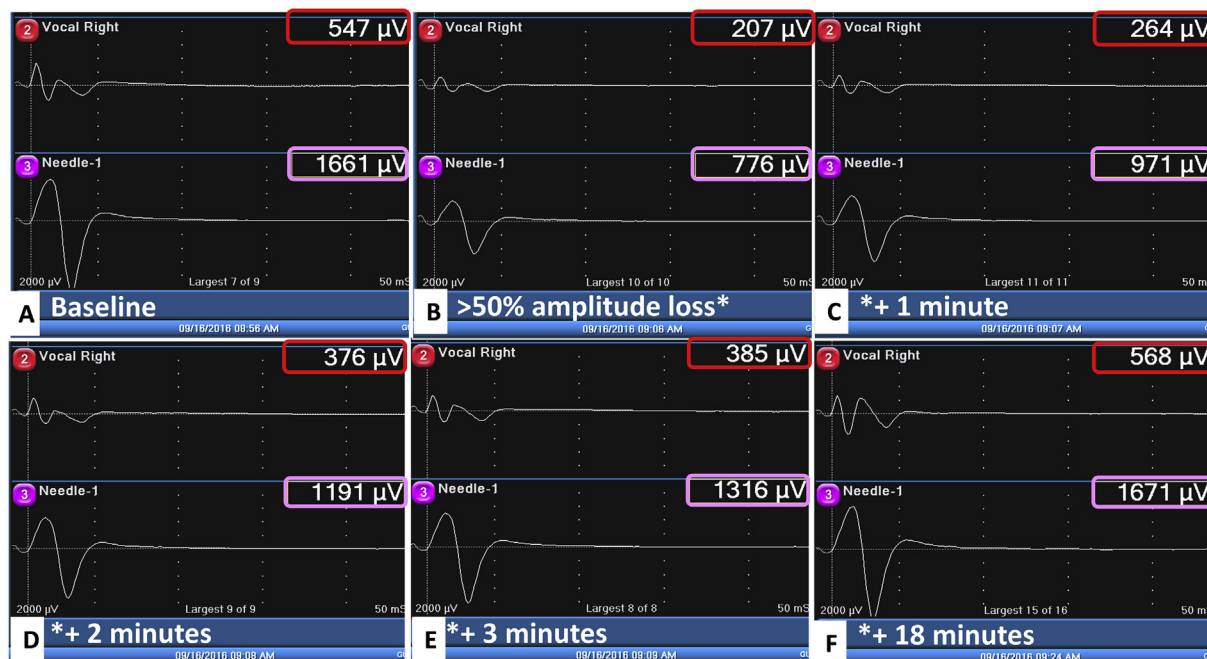


Figure 4. High and stable EMG signals recorded by TC electrodes are a useful early indicator of adverse EMG change caused by RLN traction stress. (A) Baseline EMG from TC electrodes (channel 3 of the monitoring screen) was 1661 μV . (B) Adverse EMG change (>50% amplitude decrease) caused by traction stress on the RLN was noted during surgical dissection. Therefore, surgical traction maneuver was stopped immediately at that moment (*). (C–E) After the moment (*) of traction maneuver stopped, the EMG amplitude show gradual and progressive recovery. (F) The EMG signal recovered to the baseline level within 18 min. In contrast, the ET electrodes obtained a relatively less robust signal (channel 2 of the monitoring screen) and were less effective for detecting adverse EMG change.

procedure also proved to be safe because the needles were only inserted into the sub-perichondrium and did not penetrate the TC. No laryngeal hematomas, lacerations, infections, or ruptured endotracheal cuffs occurred. However, using TC electrodes in this recording method revealed two limitations: 1) the procedure needs to expose the TC and therefore it will be difficult to be applied in procedures with small skin incision or procedures that involve endoscopy, and 2) inserting the electrodes into the sub-perichondrium may be difficult in elderly patients who have severely calcified thyroid cartilage. Therefore, we redesigned the TC electrodes to address these limitations. Our modified electrodes are currently under evaluation in ongoing animal experiments.

The initial EMG signals recorded by the TC electrodes were significantly higher than those recorded by the ET electrodes (V_1 signal: 1652 μV versus 724 μV , respectively; $p < 0.001$). A high initial EMG amplitude during IONM reportedly helps to achieve early RLN localization and identification [16], especially in thyroid operations complicated by anatomic RLN variations [17]. In this study, we found the initial high EMG amplitude from TC recording electrodes is helpful to early alarm the adverse EMG change caused by RLN traction stress (Fig. 4). In our previous experimental study [18], we observed a gradual and progressive decrease of EMG amplitude when the RLN was under traction stress. Notably, almost complete recovery of EMG signal could be achieved when traction stress was early relieved by detecting 50% of amplitude reduction. Therefore, the initial R_1 signals were used as reference data, and

a 50% amplitude decrease was considered a warning sign during lateral RLN dissection in this study. In three nerves that showed substantial amplitude decreases intraoperatively, the EMG amplitude gradually recovered to baseline after release of thyroid traction (Fig. 4).

Stable intraoperative EMG signals during monitored thyroidectomy are also needed for accurate prediction of vocal cord function after surgery. A final EMG signal that is unchanged or increased at the end of surgery generally indicates normal postoperative vocal cord function. Conversely, a large amplitude decrease of the final signal may indicate postoperative cord palsy [5,12]. In the current study, unchanged or increased final EMG signals were detected by 99% of TC electrodes but by only 76% of ET electrodes among the 196 nerves without evidence of injury. Additionally, substantial amplitude decrease (over 50%) occurred in 20 nerves (10%) monitored with ET electrodes, but in none of the nerves monitored with TC electrodes (Fig. 2). Of these, false LOS (EMG < 100 μV) events occurred in three nerves, all of which resulted from severe ET displacement during the surgical manipulation (Fig. 3D and E). These data indicate that EMG signals detected by TC electrodes are more stable than those detected by ET electrodes.

Conclusions

Both the conventional ET and new TC recording methods are useful and reliable for recording laryngeal EMG signals

during IONM. Compared to ET electrodes, however, TC electrodes obtain higher and more stable EMG signals as well as fewer false EMG signals during IONM. Thus, TC recording method is a useful, simple, and inexpensive alternative method of monitoring RLN function during thyroid surgery.

Acknowledgments

This study was supported by grants from the Kaohsiung Medical University (KMUH105-5R39; KMU-TP105E23) and the Ministry of Science and Technology (MOST 105-2314-B-037-010) Taiwan.

References

- [1] Randolph GW, Dralle H, Abdullah H, Barczynski M, Bellantone R, Brauckhoff M, et al. Electrophysiologic recurrent laryngeal nerve monitoring during thyroid and parathyroid surgery: international standards guideline statement. *Laryngoscope* 2011;121(Suppl. 1):S1–16.
- [2] Tsai CJ, Tseng KY, Wang FY, Lu IC, Wang HM, Wu CW, et al. Electromyographic endotracheal tube placement during thyroid surgery in neuromonitoring of recurrent laryngeal nerve. *Kaohsiung J Med Sci* 2011;27:96–101.
- [3] Lu IC, Chu KS, Tsai CJ, Wu CW, Kuo WR, Chen HY, et al. Optimal depth of NIM EMG endotracheal tube for intraoperative neuromonitoring of the recurrent laryngeal nerve during thyroidectomy. *World J Surg* 2008;32:1935–9.
- [4] Kim HY, Tufano RP, Randolph G, Barczynski M, Wu CW, Chiang FY, et al. Impact of positional changes in neural monitoring endotracheal tube on amplitude and latency of electromyographic response in monitored thyroid surgery: results from the porcine experiment. *Head Neck* 2016;38(Suppl. 1):E1004–8.
- [5] Wu CW, Wang MH, Chen CC, Chen HC, Chen HY, Yu JY, et al. Loss of signal in recurrent nerve neuromonitoring: causes and management. *Gland Surg* 2015;4:19–26.
- [6] Snyder SK, Hendricks JC. Intraoperative neurophysiology testing of the recurrent laryngeal nerve: plaudits and pitfalls. *Surgery* 2005;138:1183–91. discussion 91–2.
- [7] Chan WF, Lo CY. Pitfalls of intraoperative neuromonitoring for predicting postoperative recurrent laryngeal nerve function during thyroidectomy. *World J Surg* 2006;30:806–12.
- [8] Chiang FY, Lu IC, Kuo WR, Lee KW, Chang NC, Wu CW. The mechanism of recurrent laryngeal nerve injury during thyroid surgery—the application of intraoperative neuromonitoring. *Surgery* 2008;143:743–9.
- [9] Beldi G, Kinsbergen T, Schlumpf R. Evaluation of intraoperative recurrent nerve monitoring in thyroid surgery. *World J Surg* 2004;28:589–91.
- [10] Dionigi G, Bacuzzi A, Boni L, Rovera F, Dionigi R. What is the learning curve for intraoperative neuromonitoring in thyroid surgery? *Int J Surg* 2008;6(Suppl. 1):S7–12.
- [11] Van Slycke Sam, Van Den Heede Klaas, Brusselsaers Nele, Hubert V. New placement of acquisition electrodes on the thyroid cartilage in intra-operative neuromonitoring during thyroid surgery. In: *The first world congress of neural monitoring in thyroid and parathyroid surgery*; 2015. Krakow, Poland.
- [12] Chiang FY, Lee KW, Chen HC, Chen HY, Lu IC, Kuo WR, et al. Standardization of intraoperative neuromonitoring of recurrent laryngeal nerve in thyroid operation. *World J Surg* 2010;34:223–9.
- [13] Wu CW, Hao M, Tian M, Dionigi G, Tufano RP, Kim HY, et al. Recurrent laryngeal nerve injury with incomplete loss of electromyography signal during monitored thyroidectomy—evaluation and outcome. *Langenbecks Arch Surg* 2017;402(4):691–9.
- [14] Liu XL, Wu CW, Zhao YS, Wang T, Chen P, Xin JW, et al. Exclusive real-time monitoring during recurrent laryngeal nerve dissection in conventional monitored thyroidectomy. *Kaohsiung J Med Sci* 2016;32:135–41.
- [15] Dralle H, Sekulla C, Lorenz K, Brauckhoff M, Machens A. Intraoperative monitoring of the recurrent laryngeal nerve in thyroid surgery. *World J Surg* 2008;32:1358–66.
- [16] Chiang FY, Lu IC, Chen HC, Chen HY, Tsai CJ, Hsiao PJ, et al. Intraoperative neuromonitoring for early localization and identification of the recurrent laryngeal nerve during thyroid surgery. *Kaohsiung J Med Sci* 2010;26:633–9.
- [17] Chiang FY, Lu IC, Chen HC, Chen HY, Tsai CJ, Hsiao PJ, et al. Anatomical variations of recurrent laryngeal nerve during thyroid surgery: how to identify and handle the variations with intraoperative neuromonitoring. *Kaohsiung J Med Sci* 2010;26:575–83.
- [18] Wu CW, Dionigi G, Sun H, Liu X, Kim HY, Hsiao PJ, et al. Intraoperative neuromonitoring for the early detection and prevention of RLN traction injury in thyroid surgery: a porcine model. *Surgery* 2014;155:329–39.