

## Stem Cell Factor Receptor Immunoexpression in Adolescent Varicocele

Arena Salvatore<sup>1\*</sup>, Impellizzeri Pietro<sup>1</sup>, Fazzari Carmine<sup>2</sup>, Peri Flora Maria<sup>1</sup>, Antonelli Enrica<sup>1</sup>, Calabrese Ugo<sup>1</sup>, Centorrino Antonio<sup>1</sup>, Alibrandi Angela<sup>3</sup>, Romeo Carmelo<sup>1</sup>

**Purpose:** Stem cell factor receptor (c-kit) plays a crucial role in regulating proliferation and survival of germ cells. The aim of this study was to find the correlation between the number of c-kit positive germ cells, testicular asymmetry and histological grade in varicocele affected testis samples of adolescents.

**Materials and Methods:** Twenty testicular biopsy samples of adolescents affected by varicocele and eight normal control testes were included. The relationship between percentage of testicular asymmetry, number of tubular c-kit positive germ cells and severity of spermatogenic failure was assessed.

**Results:** The mean (SD; median) histological grade for spermatogenic failure in controls was 1.37(0.52; 1), while in the varicocele group, it was 2.70(1.08; 3) ( $P = .0052$ ). Mean(SD; median) number c-kit positive germ cells in the control group were 20.1(2.52; 20), while in the varicocele group it was 12.35(7.16; 12.5) ( $P = .0059$ ). Spearman test documented a significant positive correlation between percentage of hypotrophy and histological grade of spermatogenic failure ( $r = 0.5544$ , 95% CI: 0.1345 to 0.8055,  $P = .0112$ ) but a negative correlation with the number of c-kit positive cells ( $r = -0.5871$ , 95% CI: -0.8219 to -0.1817,  $P = .0065$ ). Moreover, a significant negative correlation was found between grade of histological changes and number of c-kit positive germ cells ( $P < .0001$ ).

**Conclusion:** A significant correlation between hypotrophy, histological lesions and c-kit positive germ cells exists in varicocele testes. This finding suggests a possible role for c-kit in the pathogenesis of germ cell impairment in varicocele. Histological changes and lack of c-kit germ cells were also noted in testes not displaying hypotrophy. We believe that reliable markers should be found as better predictors of testicular function in adolescent with varicocele.

**Keywords:** c-kit; histology; male infertility; testicular hypotrophy; varicocele

## INTRODUCTION

Varicocele affects testicular function and is considered a main but corrigible cause of male infertility<sup>(1-2)</sup>. Even if medical management promises a potential solution<sup>(3-9)</sup>, surgery is considered the mainstay of varicocele treatment<sup>(10)</sup>. The pathogenesis of testicular damage remains controversial and no mechanism has exclusively explained the exact way in which varicocele impairs spermatogenesis. Multifactorial pathogenesis of testicular damage includes hypoxia by small vessel occlusion and venous stasis and<sup>(11)</sup>, enhancement of scrotal and testicular temperature<sup>(12)</sup>, retrograde blood flow of renal and adrenal metabolites in the spermatic vein<sup>(13)</sup>, reduction of gonadotrophins and androgens<sup>(14)</sup>, testicular aquaporin 9 down-regulation<sup>(15)</sup>, and oxidative stress<sup>(16)</sup>. It has been reported that the expression of c-kit receptor plays a pivotal role in the survival and proliferation of type A spermatogonia<sup>(17)</sup>, mature germ cells, and regulation of gametogenesis<sup>(18-19)</sup>. Moreover, its expression in testicular tubular cells has also been

reported to be inversely related to germ cell apoptosis and hypoplasia<sup>(20-22)</sup>. Of note, alteration of transcription levels or deregulated actions of the c-kit signaling system have been associated with reproductive disorders and male infertility<sup>(21-23)</sup>. In this regard, W (dominant White spotting) and Sl (Steel) loci mutations in mice which encode the c-kit receptor, cause sterility, as they are necessary for the migration and proliferation of primordial germ cells<sup>(24)</sup>.

To the best of our knowledge, the immunoexpression of c-kit in adolescent human testicular samples affected by varicocele has not yet been investigated. The aim of the present study was to immunolocalize c-kit and to correlate it with the number of c-kit positive germ cells per tubule. Testicular volumetric asymmetry and grade of histological changes were also assessed.

## MATERIALS AND METHODS

Ethical approval for this study was received from the Local Ethics Committee (ethics code: 90/19). We retrospectively evaluated testicular incisional biopsies of

<sup>1</sup>Unit of Pediatric Surgery, Department of Human Pathology of Adult and Childhood "Gaetano Barresi", University of Messina, Messina, Italy.

<sup>2</sup>Department of Human Pathology, Ospedale Umberto I, Siracusa, Italy.

<sup>3</sup>Unit of Statistical and Mathematical Sciences, Department of Economics, University of Messina, Messina, Italy.

\*Correspondence: Unit of Pediatric Surgery, Department of Human Pathology of Adult and Childhood "Gaetano Barresi", University of Messina, Messina, Italy.

Tel: +390902213014. Email: salarena@unime.it.

Received May 2019 & Accepted February 2020

**Table 1.** Mean (SD) of histological grade and number of c-kit positive cells in each group and the relative p-value.

| Variables          | Left control testes |        |         | Left testes with varicocele |        |        | P value |
|--------------------|---------------------|--------|---------|-----------------------------|--------|--------|---------|
|                    | Mean ± SD           | Median | Q1-Q3   | Mean ± SD                   | Median | Q1-Q3  |         |
| Histological grade | 1.37 ± 0.52         | 1      | 1-2     | 2.70 ± 1.08                 | 3      | 2-4    | .0052   |
| c-kit+ germ cells  | 20.1 ± 2.52         | 20     | 17.5-22 | 12.35 ± 7.16                | 12.5   | 6.5-18 | .0059   |

20 post-pubertal adolescents (mean age (SD):14.3 (1.4) years old, range 13–18) with grade II or III idiopathic left varicocele which were obtained during inguinal varicocelectomy before the ligation of spermatic veins. Post-mortem tissue samples from eight age-matched subjects with normal lesion-free adolescent testes were also processed by employing archival blocks. Diagnosis of varicocele was made after performing physical examination and was confirmed by echo color Doppler ultrasonography. The percentage of volume difference between the right (unaffected) and left testis was calculated according to medical records and decreased volume of the left testis compared with the right was considered as testicular hypotrophy.

### Histological grading

Histological spermatogenesis was graded according to the Johnsen score. As previously described, samples were assigned to the following groups: (26)

- Normal spermatogenesis: A majority (>50%) of the spermatogenic tubules have a Johnsen's score of 10 (normal) or 9 (disorganized architecture, but with ≥ 10 sperm cells).

- Spermatogenic impairment: <50% of the spermatogenic tubules exhibit a Johnsen's score of 10 or 9. To investigate the severity of the spermatogenic impairment, this group was further divided into the following histological subgroups:

(i) Moderate hypospermatogenesis: < 50% of the seminiferous tubules have a Johnsen's score of 9 or 10 but >10% of the seminiferous tubules have a Johnsen's score of 8 (<10 sperm cells);

(ii) Severe hypospermatogenesis with few sperm cells: no seminiferous tubules have a Johnsen's score of 9 or 10, and ≤ 10% of the seminiferous tubules have a Johnsen's score of 8 (<10 sperm cells).

(iii) Severe hypospermatogenesis without sperm cells: no mature sperm cells found but at least one seminifer-

ous tubule has a Johnsen's score between 7 and 3 (presence of immature germ cells).

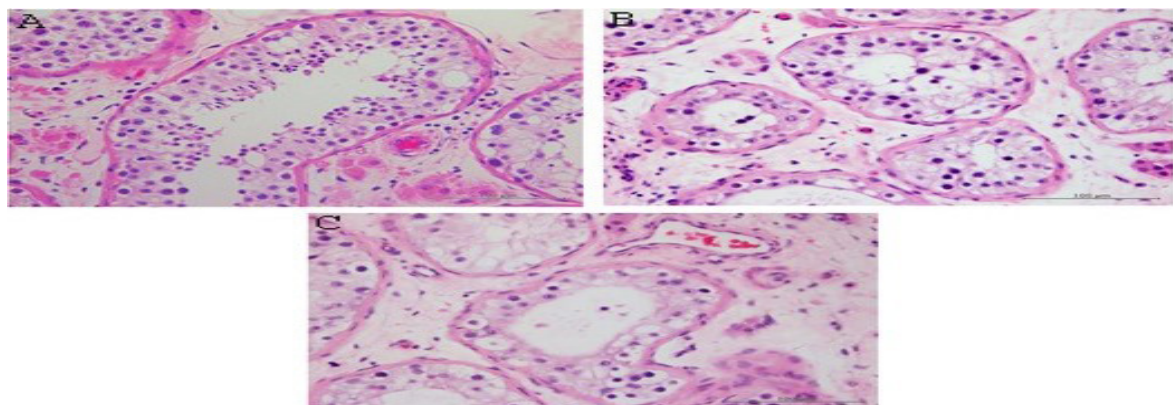
(iv) Sertoli cell-only syndrome: the seminiferous tubules have a Johnsen's score ≤ to 2 (no germ cells). Immunohistochemical evaluation

Immunostaining was carried out using a 1:50 dilution of the rabbit polyclonal anti-human c-kit (CD117) antibody (Dako- Cytomation A/S, Glostrup, Denmark) after microwave treatment. The streptavidin-biotin method (LSAB, Dako), with diaminobenzidine development (Vector VIP substrate, Vector Lab, Burlingame, CA), and methylgreen or toluidine blue nuclear counter-staining was performed. Positive controls were carried out using specimens from lung small cell carcinoma for c-kit labelling. Negative controls were obtained by omitting incubation with the primary antibody.

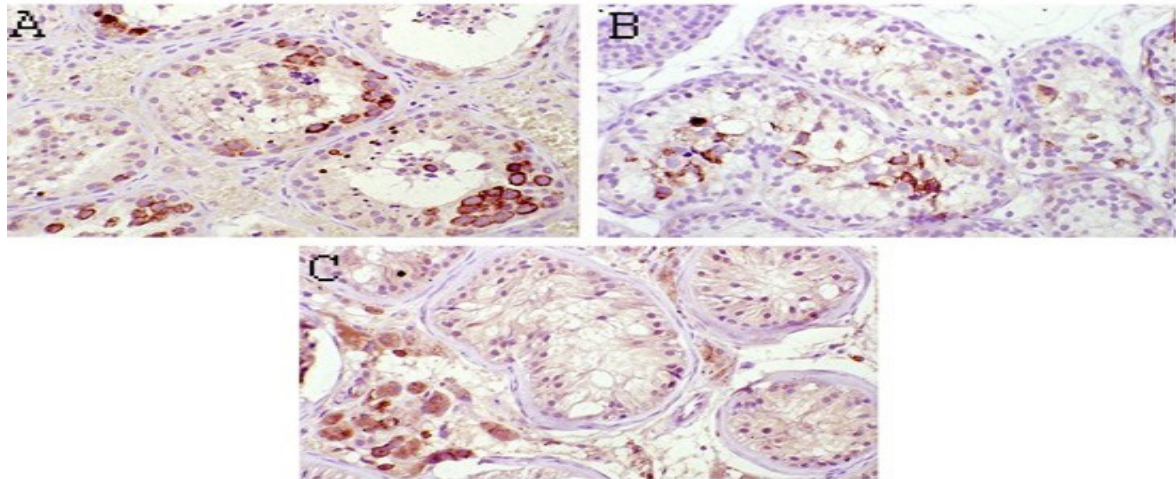
### Statistical analysis

In our study, we focused on the primary variable which was the immunoexpression of c-kit in human testicular samples. Secondary variables were the histology of the testis, the grade of histological spermatogenesis and the volume of testis.

For a quantitative analysis, the percentage of intratubular positive cells in each tubule was counted in five tubules of each specimen. As the number of observations in each group was not enough to assess the normality of the distributions, the results of each group were compared by the non-parametric Mann-Whitney *U* test. The relationship between the quantitative parameters (percentage of left testicular hypotrophy, number of c-kit positive germ cells per tubule) and the histological grade of spermatogenesis according to modified Johnsen's score<sup>(26)</sup> was studied by the non-parametric Spearman's Rank correlation test between the parametric values and values 1 (normal spermatogenesis), 2 (moderate hypospermatogenesis), 3 (severe hypospermatogenesis with few sperm cells), 4 (severe hy-



**Figure 1. A-C:** Light microscopy: **A)** Normal control testis (Johnsen's score 9-10, H&H, original magnification 200x); **B)** Varicocele affected testis showing detachment and sloughing of basal germ cells and a depletion of sperm cells (Johnsen's score 5, H&H, original magnification 200x); **C)** Severe grade of histological lesion of a varicocele affected testis, with intra and extratubular edema, venular ectasia, peritubular ectasia and marked depletion of germ cells (Johnsen's score 3, H&H, original magnification 200x).



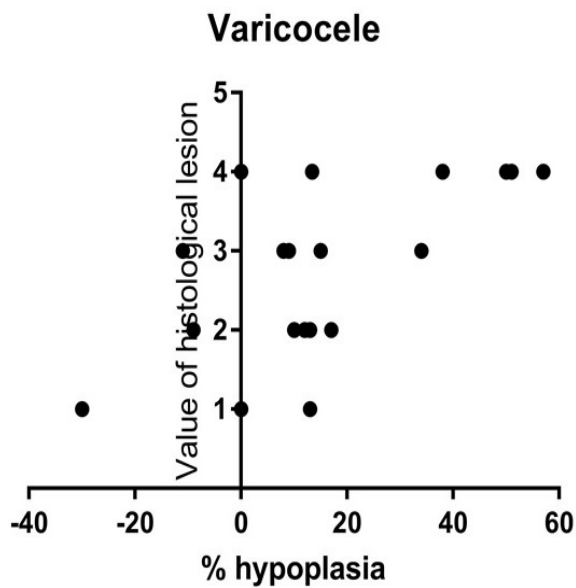
**Figure 2. A-C:** C-kit immunohistochemistry: **A)** Control testis: about 20% of c-kit positive germ cells are shown in a control testis (original magnification 200x); **B)** Varicocele testis with moderate hypospermatogenesis: about 10% of c-kit positive cells are present in sloughed germ cells (original magnification 200x); **C)** Varicocele testis with severe hypospermatogenesis without sperm cells: no positive cells are present (original magnification 200x)

pospermatogenesis without sperm cells) and 5 (Sertoli cell only syndrome) regarding the histologic subgroups<sup>(26)</sup>.  $P < .05$  was considered as statistically significant.

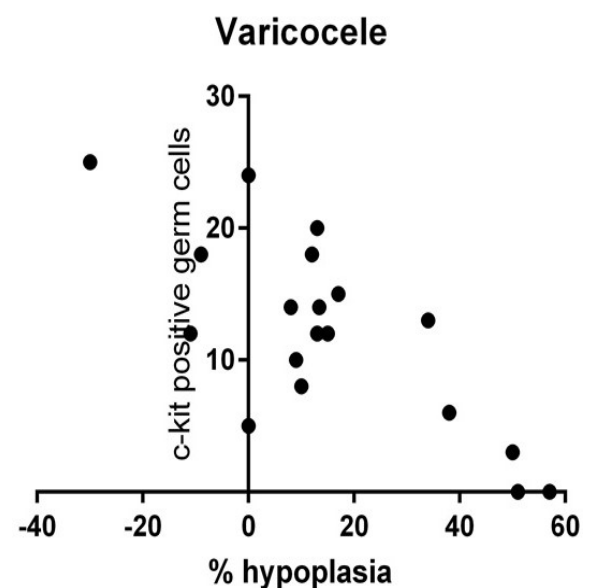
**RESULTS**

Changes in tubular and extra-tubular compartments were seen in the studied varicocele testes, displaying more or less disarranged tubular compartments. Sloughing and detachment of basal germ cells occurred with a varying degree of germ and Sertoli cell impairment, up to spermiogenesis failure. Unlike normal testes (**Figure 1A**), varicocele testes showed dilated microvessels, more or less expanded extra-tubule fluid and extracellular matrix, and many extracellular vesicles inside the seminiferous tubules. Leydig cell clusters were con-

stantly observed. A varying degree of interstitial edema prevailed, with notable peritubular and extratubular fibrosis (**Figure 1B & C**). Mean (SD) histological grade of spermatogenesis in the control group was 1.37 (0.52), while in the varicocele group, this figure was 2.70 (1.08), indicating a statistically significant difference ( $P = .0052$ ). Specifically, in the control group, 5 testes had value 1 and 3 testes demonstrated value 2. On the other hand, in the varicocele group, 3 testes had value 1, 6 had value 2, 5 demonstrated value 3, and 6 samples were value 4. Mean (SD) of c-kit positive germ cells in the control group was 20.1 (2.52) and 12.35 (7.16) in the varicocele group ( $P = .0059$ ) (**Figure 2A-C**) (**Table 1**). The mean percentage (SD) of testicular volume discrepancy between right (unaffected) and

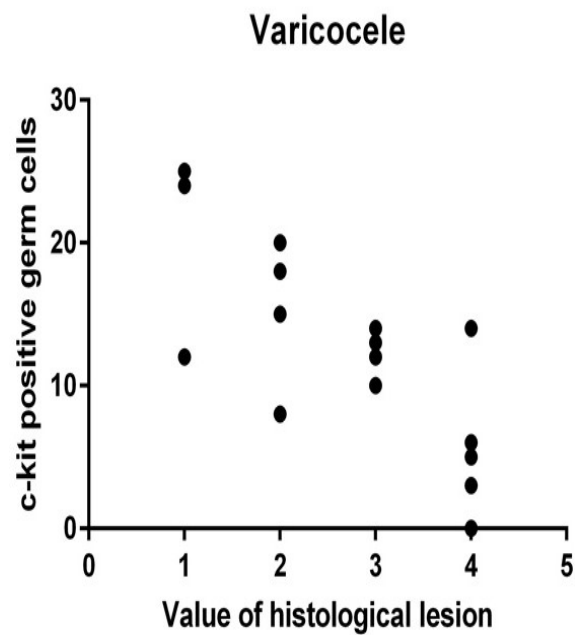


**Figure 3.** Distribution of percentage of left testicular asymmetry and histological grade of spermatogenesis in varicocele group



**Figure 4.** Distribution of percentage of left testicular asymmetry and number of c-kit positive germ cells in the varicocele group.





**Figure 5.** Distribution of percentage of histological grade of spermatogenesis and number of c-kit positive germ cells in the varicocele group.

left (varicocele affected) testes was %14.1 (%22.5), median %12.5, Q1 = 0, and Q3 = 29.7. Spearman test documented a significant positive correlation between percentage of testicular volumetric discrepancy and histological grade of spermatogenesis ( $r = .5544$ , 95% confidence interval (CI): 0.1345 to 0.8055,  $P = .0112$ ) (Figure 3) but a negative correlation with number of c-kit positive cells ( $r = -0.5871$ , 95% CI: -0.8219 to -0.1817,  $P = .0065$ ) (Figure 4). Moreover, a significant negative correlation was found between histological grade of spermatogenesis and number of c-kit positive germ cells ( $p < .0001$ ,  $r = -0.7621$ , 95% CI: 0.9035 to -0.4714) (Figure 5).

## DISCUSSION

Although surgical correction of varicocele in adolescents before onset of infertility may be advantageous, it has been reported that fertility problems will arise later in about 20% of adolescents with varicocele<sup>(26)</sup>. As sperm analysis is not obtained worldwide from pediatric patients, both for legal and ethical reasons and because patients' hormonal profiles are not fully developed, establishing the potential existence of prognostic markers that would make it possible to decide for surgery and to determine, when necessary, the appropriate time of surgery is still a controversial issue. While waiting for a reliable marker to be identified for early detection of testicular impairment in adolescents affected by varicocele, current international guidelines recommended treatment of clinical varicocele in adolescents only in selected cases such as objective evidence of reduced ipsilateral testicular size<sup>(9)</sup>. However, recently, it has been reported that 100% of adolescent patients varicocele affected with a testicular volumetric discrepancy > 20% calculated by ultrasonography fail to fulfill the World Health Organisation adult criteria for normal spermatogenesis in comparison with 50% of those with symmetrical testis<sup>(27)</sup>. Not only is it suggested that a positive

correlation between testicular hypotrophy and spermatogenic impairment exists but also that a symmetrical testis affected by varicocele does not always reflect normal semen parameters<sup>(28)</sup>. In our study, we found that there is a significant positive correlation between the percentage of testicular volumetric discrepancy and the histological grade of spermatogenesis and that testicular symmetry does not exclude the probability of an even severe testicular impairment, triggering a potential subsequent infertility. This data suggests that testicular volume should not be considered as an early, reliable marker of testicular impairment in adolescent varicocele.

Moreover, in this study, a lack of c-kit positive germ cells was found in varicocele affected testes, with a significant positive correlation with histological changes. C-kit is closely associated with developing germ cells contributing to germ-cell homeostasis<sup>(29)</sup>. A diminished expression of c-kit has been found in the testis of infertile men<sup>(30)</sup>, particularly in Sertoli-cell-only syndrome<sup>(31,32)</sup>. These observations highlight the importance of c-kit signaling for germ-cell survival and successful spermatogenesis, implying crucial participation of c-kit in the onset and maintenance of spermatogenesis<sup>(29,33,34)</sup>.

A reduced expression of c-kit in the tubular compartment of damaged varicocele-affected testes substantiates the role of this proto-oncogene in the pathogenesis of infertility. Moreover, unexpected data which emerged from our study was that there is a significant difference in histological grade of spermatogenesis between the subgroup of varicocele affected testes with a hypotrophy  $\leq 10\%$  and control testes. In this regard, 9 out of 20 varicocele-affected testes showed a volumetric testicular discrepancy  $\leq 10\%$  and in this subgroup, the histological grade of spermatogenesis was  $2.33 \pm 1.00$  which was significantly higher compared to the control group ( $P = .0495$ ). Furthermore, a lower but not significant reduction of c-kit cells was recorded in varicocele group compared with control group ( $14.89 \pm 6.918$  versus  $20.13 \pm 2.532$ ,  $P = .1193$ ). It suggests that testes affected by varicocele during adolescence can display a significant impairment of the tubular testicular function irrespective of testicular volume, and that left testicular volumetric loss is strictly correlated with histological changes, which based on our experience, is the rule. Even if current international guidelines, which provide a framework of standardized care, restrict the surgical management of idiopathic monolateral asymptomatic varicocele to conditions such as the presence of ipsilateral testicular hypotrophy, at times when sperm analysis is not available, our study suggests that a reliable and more sensitive indicator of testicular damage should be identified to avoid progressive impairment of future fertility in adolescents with varicocele. On this basis, we believe that the effort of both basic and clinical research should be focused on the identification of a reliable predictor of future infertility of adolescent affected by varicocele even when volumetric testicular discrepancy is not present. On the other hand, until a highly sensitive, specific and non-invasive indicator is found, it is at least questionable to correct all varicoceles in adolescents, since only few adolescents with varicocele will show infertility impairment in adulthood. The main limitations of this study were its retrospective nature, small sample size and the unavailability of access to testicular volume in the control group

## CONCLUSIONS

Our study showed a significant correlation between the percentage of left testicular asymmetry, histological grade of spermatogenesis and c-kit positive germ cells in varicocele affected testes. It suggests a role of c-kit in the pathogenesis of germ cell impairment in testes of adolescents affected by varicocele. However, histological changes and a lack of c-kit germ cells have also been noted in testes not displaying a significant left hypotrophy. This suggests that testicular hypotrophy is a specific but not sensitive-enough indicator of testicular damage. We believe that other markers should be investigated as better and more reliable predictors of testicular function in adolescents with varicocele.

## ACKNOWLEDGEMENT

The authors would like to thank Miss Piscilla Haass for the linguistic revision.

## CONFLICT OF INTEREST

None declared by the authors.

## REFERENCES

- Haddad NG, Houk CP, Lee PA. Varicocele: a dilemma in adolescent males. *Pediatr Endocrinol Rev* 2014; 11:274-83
- Pasqualotto FF, Lucon AM, de Góes PM et al. Testicular growth, sperm concentration, percent motility, and pregnancy outcome after varicocelectomy based on testicular histology. *Fertil Steril* 2005; 83:362-6
- Oliva A, Dotta A, Multigner L. Pentoxifylline and antioxidants improve sperm quality in male patients with varicocele. *Fertil Steril* 2009; 91:1536-9
- Practice Committee of the American Society for Reproductive Medicine; Society for Male Reproduction and Urology. Report on varicocele and infertility: a committee opinion. *Fertil Steril* 2014; 102:1556-60
- Minutoli L, Arena S, Antonuccio P et al. Role of Inhibitors of Apoptosis Proteins in Testicular Function and Male Fertility: Effects of Polydeoxyribonucleotide Administration in Experimental Varicocele. *Biomed Res Int* 2015; 2015:248976
- Arena S, Minutoli L, Arena F et al. Polydeoxyribonucleotide administration improves the intra-testicular vascularization in rat experimental varicocele. *Fertil Steril* 2012; 97: 165-8
- Minutoli L, Antonuccio P, Squadrito F et al. Effects of polydeoxyribonucleotide on the histological damage and the altered spermatogenesis induced by testicular ischaemia and reperfusion in rats. *Int J Androl* 2012; 35:133-44
- Minutoli L, Arena S, Bonvissuto G et al. Activation of adenosine A2A receptors by polydeoxyribonucleotide increases vascular endothelial growth factor and protects against testicular damage induced by experimental varicocele in rats. *Fertil Steril* 2011; 95:1510-3
- Roque M, Esteves SC. A systematic review of clinical practice guidelines and best practice statements for the diagnosis and management of varicocele in children and adolescents. *Asian J Androl* 2016; 18:262-8
- Borruto FA, Impellizzeri P, Antonuccio P et al. Laparoscopic vs open varicocelectomy in children and adolescents: review of the recent literature and meta-analysis. *J Pediatr Surg*. 2010 ;45(12):2464-9
- Chakraborty J, Hikim AP, Jhunjhunwala JS Stagnation of blood in the microcirculatory vessels in the testes of men with varicocele. *J Androl* 1985; 6:117-26
- Goldstein M, Eid JF. Elevation of intratesticular and scrotal skin surface temperature in men with varicocele. *J Urol* 1989; 142:743-5
- Hudson RW . The endocrinology of varicoceles. *Fertil Steril* 1988; 49:199-208
- Swerdloff RS, Walsh PC. Pituitary and gonadal hormones in patients with varicocele. *Fertil Steril* 1975; 26:1006-12
- Arena S, Arena F, Maisano D et al. Aquaporin-9 immunohistochemistry in varicocele testes as a consequence of hypoxia in the sperm production site. *Andrologia* 2011; 43:34-7
- Romeo C, Santoro G Free radicals in adolescent varicocele testis. *Oxid Med Cell Longev* 2014; 2014:912878
- Vigodner M, Lewin LM, Shochat L et. Spermatogenesis in the golden hamster: the role of ckit. *Mol Reprod Dev* 2001; 60:562-8
- Feng HL, Sandlow JI, Sparks AE et al. Decreased expression of the c-kit receptor is associated with increased apoptosis in subfertile human testes. *Fertil Steril* 1999; 71:85-89
- Jin G, Liu J, Qin Q, Gao S, Zhang F, Ma Y, Ding C, Dong L, Yin H, Wang Y. Increased Level of c-kit in Semen of Infertile Patients with Varicocele. *Urol J*. 2017 Mar 16;14(2): 3023-3027
- Tsuchida J, Dohmae K, Kitamura Y, Nishimune Y. The role of the c-kit receptor in the regenerative differentiation of rat Leydig cells. *Int J Androl* 2003; 26:121-5
- Sandlow JI, Feng HL, Cohen MB et al. Expression of c-Kit and its ligand, stem cell factor, in normal and subfertile human testicular tissue. *J Androl* 1996; 17:403-8
- Mauduit C, Hamamah S, Benahmed M Stem cell factor/ c-kit system in spermatogenesis. *Hum Reprod Update* 1999; 5:535-545
- Figueira MI, Cardoso HJ, Correia S, Maia CJ, Socorro S. Hormonal regulation of c-KIT receptor and its ligand: implications for human infertility? *Prog Histochem Cytochem*. 2014 ;49(1-3):1-19

24. Sette C, Dolci S, Geremia R et al. The role of stem cell factor and of alternative c-kit gene products in the establishment, maintenance and function of germ cells. *Int J Dev Biol* 2000; 44:599-608.
25. Plotton I, Sanchez P, Durand P et al. Decrease of both stem cell factor and clusterin mRNA levels in testicular biopsies of azoospermic patients with constitutive or idiopathic but not acquired spermatogenic failure. *Hum Reprod* 2006; 21:2340-5.
26. World Health Organization. The influence of varicocele on parameters of fertility in a large group of men presenting to infertility clinics. *Fertil Steril* 1992; 57:1289-93
27. Keene DJ, Sajad Y, Rakoczy G et al. Testicular volume and semen parameters in patients aged 12 to 17 years with idiopathic varicocele. *J Pediatr Surg* 2012; 47:383-5
28. Romeo C, Arrigo T, Impellizzeri P et al. Altered serum inhibin b levels in adolescents with varicocele. *J Pediatr Surg* 2007; 42:390-4.
29. Cardoso HJ, Figueira MI, Correia S et al. The SCF/c-KIT system in the male: Survival strategies in fertility and cancer. *Mol Reprod Dev* 2014; 81:1064-79
30. Feng HL, Sandlow JI, Sparks AE et al. Decreased expression of the c-kit receptor is associated with increased apoptosis in subfertile human testes. *Fertil Steril* 1999; 71:8589
31. Malcher A, Rozwadowska N, Stokowy T et al. The gene expression analysis of paracrine/autocrine factors in patients with spermatogenic failure compared with normal spermatogenesis. *Am J Reprod Immunol* 2013; 70:522-8
32. Bialas M, Borczynska A, Rozwadowska N et al. SCF and c-kit expression profiles in male individuals with normal and impaired spermatogenesis. *Andrologia* 2010; 42:83-91
33. Guerif F, Cadoret V, Rahal-Perola V et al. Apoptosis, onset and maintenance of spermatogenesis: Evidence for the involvement of Kit in Kit-haplodeficient mice. *Biol Reprod* 2002; 67:7079.
34. Raucci F, Di Fiore MM. The c-kit receptor protein in the testis of green frog *Rana esculenta*: Seasonal changes in relationship to testosterone titres and spermatogonial proliferation. *Reproduction* 2007; 133:5160.