


Thin laryngeal foreign bodies in infants: diagnostic potential of MDCT

Antonella Concerto¹, Marco Cavallaro¹ , Carmela Visalli¹, Anna Maria Bagnato², Ugo Barbaro¹ & Ignazio Salamone¹

¹Department of Biomedical and Dental Sciences and Morphofunctional Imaging, Azienda Ospedaliera Universitaria Policlinico G. Martino, Messina, Italy.

²Department of Human Pathology of Adulthood and Childhood, Azienda Ospedaliera Universitaria Policlinico G. Martino, Messina, Italy.

Keywords

Foreign body, glottis, infant, misdiagnosis, multidetector computed tomography.

Correspondence

Marco Cavallaro, Department of Biomedical and Dental Sciences and Morphofunctional Imaging, Azienda Ospedaliera Universitaria Policlinico G. Martino, 98125 Messina, Italy. E-mail: marco88cavallaro@gmail.com

Received: 26 September 2017; Revised: 27 December 2017; Accepted: 11 January 2018;
Associate Editor: Garun Hamilton.

Respirology Case Reports, 6 (3), 2018, e00301

doi: 10.1002/rcr2.301

Abstract

A laryngeal foreign body (FB) is a significant, life-threatening event in the paediatric population. Incomplete airways obstruction by a thin, laminar, radiolucent FB lodged in the glottis or supraglottis is a rare occurrence that may present with non-specific symptoms, absence of chest findings, and normal radiographic investigations, resulting in misdiagnosis, delay in diagnosis, or prolonged recovery. We report two cases of 10-month-old male infants, each with a thin radiolucent FB lodged between the vocal folds that was detected with low-dose multidetector computed tomography (MDCT) and thin-slice reconstruction. Both infants presented with symptoms of respiratory airway inflammation at clinical examination and negative neck and chest radiographs. FBs were removed by direct laryngoscopy, without complications. In our experience, low-dose MDCT with thin-slice reconstruction is particularly useful for diagnosis in cases of suspected FB aspiration with uncertain clinical presentation and negative radiographic exams.

Introduction

A laryngeal foreign body (FB) is a serious and potentially life-threatening problem in a paediatric population, especially in children younger than 3 years. Timely diagnosis and management of FB aspiration is crucial [1]. Negative neck and chest radiographs may delay diagnosis, especially in cases of incomplete obstruction with lack of signs/symptoms or in cases where a thin, radiolucent FB is lodged in the laryngeal inlet [2].

In our experience, low-dose multidetector computed tomography (MDCT), followed by thin-slice reconstruction, is particularly useful in detecting cases of occult FB aspiration.

There are few cases of glottic FBs in the literature. We report two cases of FB aspiration in infants. The FBs had the same morphology, were both wedged in the glottic region between the vocal cords, and were detected only by low-dose MDCT with thin-slice reconstruction.

Case Report

Case 1

A 10-month-old male infant was referred to the paediatric emergency room for a suspected FB in the oesophagus. The patient was in good general health, eupneic, presenting a peripheral capillary oxygen saturation (SpO₂) of 99% on room air and normal pulmonary auscultation. The mother reported a history of a choking episode, followed by paroxysm of coughing and gagging while the patient was playing, with resolution within a few minutes. She also reported a lowering of the child's voice tone after the episode; the crying was characterized by an unusual rattling, described as biphonic by the examiner. In the emergency room, the patient underwent neck, chest, and abdominal radiographs that did not detect any FBs in the digestive tract or in the tracheobronchial tree. On the suspicion of an FB in the airway, an ultra-low-dose MDCT was performed. Thin slices of 1.00 mm thickness were

reconstructed that showed the presence of a fine linear image of 8 mm with amorphous density in the glottic region, vertically arranged between the vocal cords (Fig. 1A, B).

The patient was immediately submitted to direct laryngoscopy in emergency; the removed FB was found to be a piece of conventional snack wrapping (Fig. 1C).

Case 2

A 10-month-old infant was admitted to the paediatric emergency department with chronic tracheobronchitis resistant to therapy for further investigation.

The patient presented with symptoms of respiratory system inflammation, cough, and hoarseness; at clinical examination, he was in good general conditions and eupneic. Chest and abdomen radiographs were negative. In consideration of the persistent symptomatology and lack of response to therapy, a low-dose MDCT scan with thin slices of 1.00 mm reconstruction, followed by virtual bronchoscopy (VB), was performed (Fig. 2A–C).

This technique allowed the detection of a fine linear image with amorphous density in the glottic region, vertically oriented between the vocal folds.

The patient underwent direct laryngoscopy in emergency that showed a piece of a toothbrush cover casing wedged in the glottis, which was promptly removed (Fig. 2D).

Discussion

Foreign body aspiration is a frequent cause of morbidity and mortality in childhood, especially in children between 6 months and 3 years of age [1].

Most FBs lodge in the bronchial tree, and only a small percentage (around 4%) become stuck in the larynx [3].

In our cases, both FBs were found between the vocal folds, a very rare occurrence.

Both clinical presentation and degree of obstruction depend on FB size, shape and nature, and the site of obstruction, so it is possible to see a great variability in symptoms [2].

An FB can cause complete airway obstruction, leading to sudden death if not promptly removed. On the other hand, a small FB, especially when thin, laminar, or triangular shaped, can determine a partial laryngeal obstruction, which may present with less severe symptoms. Particular attention must be paid if the patient presents with aphony or biphonic cry, as in one of our cases, as

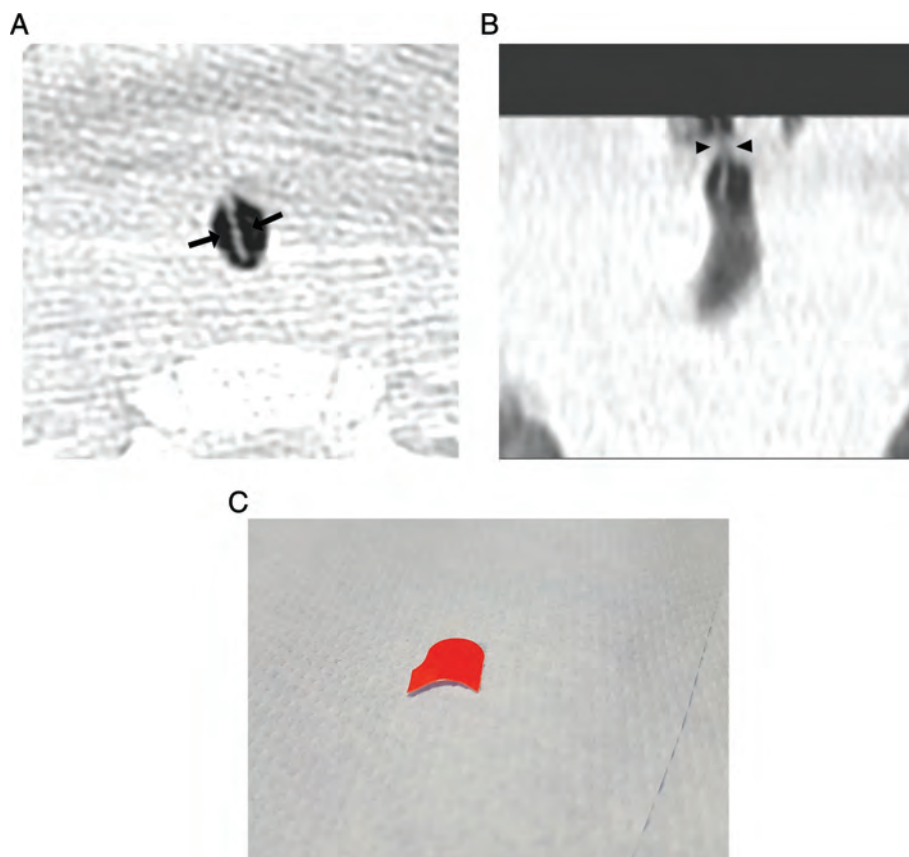


Figure 1. (A) Axial computed tomography (CT) image, demonstrating a foreign body (FB) located in glottic region (arrowheads). (B) CT image with coronal reconstruction, showing transglottic FB (arrowheads). (C) Piece of snack wrapping removed from larynx by laryngoscopy.

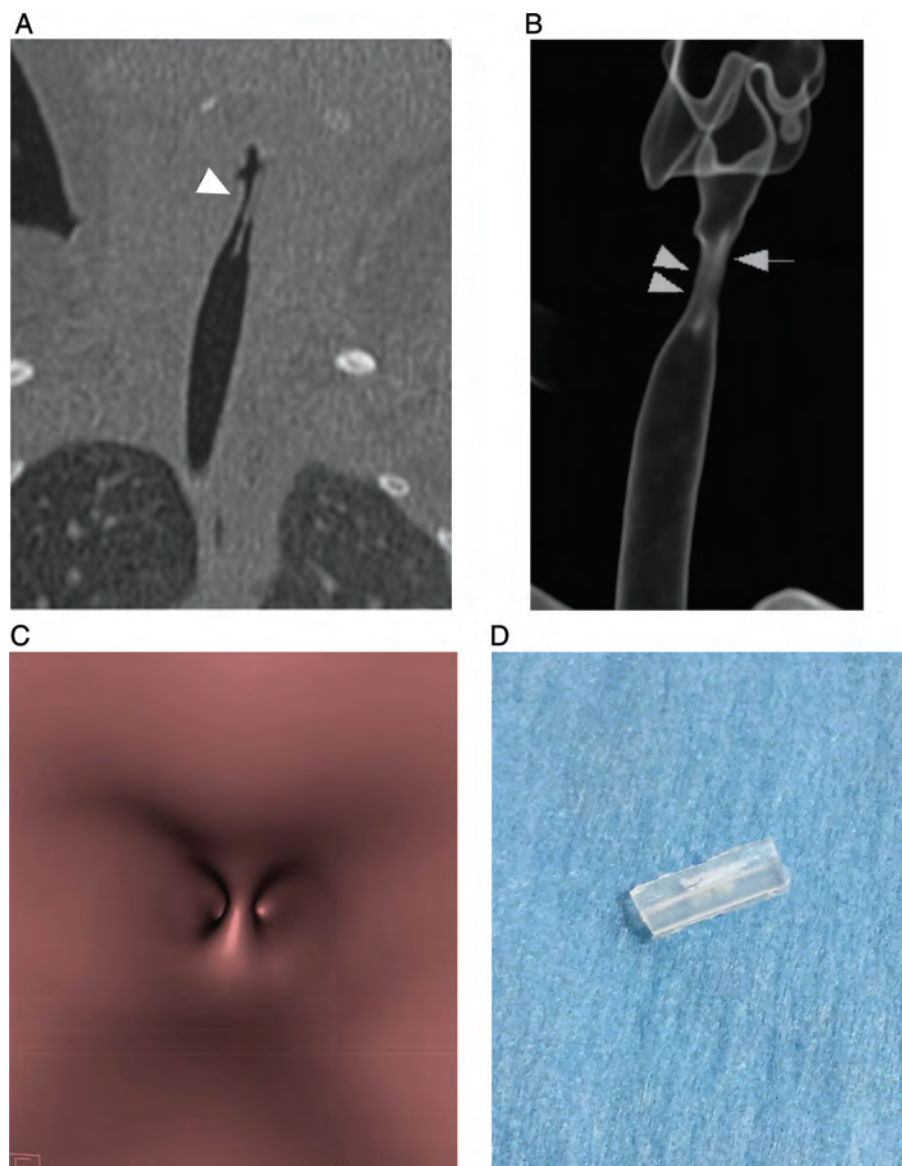


Figure 2. (A) Reconstructed coronal computed tomography (CT) image, displaying foreign body (FB) in glottis (arrowhead). (B) Three-dimensional volume-rendering technique (VRT) image with laryngography-like visualization, demonstrating FB (arrow) in glottic region (arrowheads). (C) Virtual bronchoscopic image with endoluminal surface view. (D) Piece of a toothbrush cover casing retrieved from larynx by laryngoscopy.

these symptoms have been reported to be more specific of FB aspiration [4].

Unfortunately, in most cases, symptomatology is completely non-specific, with the most common signs being cough and hoarseness. In these conditions, the clinical presentation can mimic other common diseases, such as asthma, bronchial, or recurrent pneumonia, thus resulting in possible misdiagnosis, delay in diagnosis, or prolonged recovery [5].

Diagnostic imaging plays an important role in the management of FB aspiration, helping to establish correct diagnosis and to evaluate for possible complications [6].

Chest and neck radiographies are the recommended initial examinations and can be helpful if the FB is

radiopaque. Unfortunately, it is estimated that only around 16% of FBs in the respiratory system are radiopaque [7].

In addition, typical indirect radiological signs that are sometimes seen when an FB has reached the lower airways – such as unilateral lung hyperinflation, mediastinal shift, and consolidation – are not generally present if the FB is lodged in the larynx, and radiographies are almost always normal.

Indeed, the absence of radiological manifestations has been found to be one of the most important risk factors of misdiagnosis in cases of laryngeal FB, leading to possibly serious complications, such as laryngitis, granulation tissue formation, and laryngeal stenosis [4].

Therefore, in patients with suspected FB in larynx – and more generally in the airways – it is of the utmost

importance to rapidly arrive at a correct diagnosis, which is often not easy, especially in the presence of atypical history, non-specific symptoms, and negative radiographs. In such cases, the question of what the most appropriate diagnostic workup should be is still under debate.

Direct laryngoscopy and rigid bronchoscopy are undoubtedly the gold standard for FBs aspiration, allowing both diagnosis and treatment at the same time, and they are often performed even when there is little suspicion of an FB in the airways. However, they are invasive procedures that can be associated with severe complications – such as pneumothorax, pneumomediastinum, airway laceration, subglottic oedema, and death – and are performed under general anaesthesia [8].

MDCT with a low-dose protocol is a sensitive technique that can detect radiolucent FBs in the larynx and the tracheobronchial tree. Moreover, it can be combined with VB, a technique that has three-dimensional surface-rendering and volume-rendering possibilities, thus providing a view of the internal surface of the airways.

Unlike direct laryngoscopy, this diagnostic modality does not generally require anaesthesia and makes it possible to identify the exact location of the FB, with a very high sensitivity [9].

In addition, it provides good characterization of the nature of the aspirated objects and is, thus, important for endoscopy planning, especially in cases in which FBs with an unusual shape require additional instrumentation [8].

In both our cases, low-dose MDCT with VB allowed the detection and characterization of two thin, laminar FBs wedged in the glottis region, between the vocal folds, which were then removed by direct laryngoscopy, without complications during and at the end of the procedure.

Despite its many advantages, some limitations should be considered.

The main criticism directed at computed tomography (CT) concerns radiation exposure; however, in our cases, by using the low-dose protocol, the estimated effective dose of CT scans was 0.20 mSv, a significantly lower value than natural background exposure.

False positives may occur due to endoluminal secretions or other obstructive lesions, whilst the possibility of false negatives is undoubtedly rarer (e.g. an inexpert radiologist confusing a hollow FB with the normal glottis) [10].

Finally, CT imaging without the use of sedation can be performed in cooperative children and is not always possible in patients under respiratory distress.

In conclusion, a laryngeal FB is a rare occurrence in an infant population, and the diagnosis remains a challenge,

especially when the aspirated object is thin, laminar, and radiolucent.

In our experience, low-dose MDCT with thin-slice reconstruction is particularly useful for early diagnosis in cases of suspected FBs in the larynx associated with completely non-specific symptoms and negative radiographs. Further studies that compare MDCT-VB and conventional bronchoscopy are needed in order to assess the best care management.

Disclosure Statement

Appropriate written informed consent was obtained for publication of this case series and accompanying images.

References

1. Tan HK, Brown K, McGill T, et al. 2000. Airway foreign bodies (FB): a 10-year review. *Int. J. Pediatr. Otorhinolaryngol.* 56:91–99.
2. Bloom DC, Christenson TE, Manning SC, et al. 2005. Plastic laryngeal foreign bodies in children: a diagnostic challenge. *Int. J. Pediatr. Otorhinolaryngol.* 69:657–662.
3. Cinar U, Vural C, and Turgut S. 2003. A laryngeal foreign body misdiagnosed as asthma bronchiale. *Eur. J. Emerg. Med.* 10:334–336.
4. Chen Q, Chu H, Tao Y, et al. 2017. Lessons learned from 35 cases of laryngeal foreign bodies undergoing misdiagnosis in pediatric population. *Ann. Otol. Rhinol. Laryngol.* 126:146–151.
5. Sersar SI, Rizk WH, Bilal M, et al. 2006. Inhaled foreign bodies: presentation, management and value of history and plain chest radiography in delayed presentation. *Otolaryngol. Head Neck Surg.* 134:92–99.
6. Pugmire BS, Lim R, and Avery LL. 2015. Review of ingested and aspirated foreign bodies in children and their clinical significance for radiologists. *Radiographics* 35:1528–1538.
7. Salih AM, Alfaki M, and Alam-Elhuda DM. 2016. Airway foreign bodies: a critical review for a common pediatric emergency. *World J. Emerg. Med.* 7:5–12.
8. Bai W, Zhou X, Gao X, et al. 2011. Value of chest CT in the diagnosis and management of tracheobronchial foreign bodies. *Pediatr. Int.* 53:515–518.
9. Hong SJ, Goo HW, and Roh JL. 2008. Utility of spiral and cine CT scans in pediatric patients suspected of aspirating radiolucent foreign bodies. *Otolaryngol. Head Neck Surg.* 138:576–580.
10. Jain S, Kashikar S, Deshmukh P, et al. 2013. Impacted laryngeal foreign body in a child: a diagnostic and therapeutic challenge. *Ann. Med. Health Sci. Res.* 3:464–466.