

The practical use of computed tomography in evaluation of shell lesions in six loggerhead turtles (*Caretta caretta*)

F. SPADOLA¹, G. BARILLARO², M. MORICI¹, A. NOCERA³, Z. KNOTEK⁴

¹Department of Veterinary Science, University of Messina, Messina, Italy

²Clinica Veterinaria, San Giorgio, Reggio Calabria, Italy

³Clinica Veterinaria, San Lorenzo, Palermo, Italy

⁴Faculty of Veterinary Medicine, University of Veterinary and Pharmaceutical Sciences Brno, Czech Republic

ABSTRACT: Six adult loggerhead turtles were found stranded and were rescued near Sicily within a period of 12 months. Macroscopically apparent lesions of the shell were present. After thorough physical examination, ketamine-dexmedetomidine-atipamezole induction and tracheal tube insertion all six patients underwent computed tomographic examination under inhalant anaesthesia with isoflurane. A vertebral lesion at the level of the 3rd thoracic-lumbar vertebra with vertebral lamina and the vertebral body being involved without compression of the spinal cord, a vertebral lesion at the level of the 7th thoracic-lumbar vertebra and a vertebral lesion at the level of the 8th thoracic-lumbar vertebra were recorded in the first female. Loss of the shell near the left carapace-plastron bridge, with massive haemorrhage and compression of organs were present in the second female. The remaining four turtles had only superficial lesions with no involvement of bones and organs of the coelom. Computed tomography was proved to be a valuable non-invasive method for clinical examination of stranded sea turtles.

Keywords: chelonians; shell fracture; imaging methods; computed tomography

Traumatic lesions of the shell are common problems in chelonians. Lesions of the shell vary in severity from a simple superficial abrasion with a loss of the external skin layer and exposure of the bone, up to complicated fractures of the carapace with exposure of internal organs of the coelom and injury of the soft tissues (Barten 2006). Open fractures of the shell are associated with a high risk of secondary infections and death of the patient (McArthur and Hernandez-Divers 2004). Shell fractures are always followed with massive bleeding from the bone marrow and/or vessels and if the lesions affect the upper part of the carapace in the midline, then possible trauma of the spinal cord resulting in paralysis has to be considered (Barten 1996; Hedley and Kubiak 2015). It is a challenge for the veterinarian to precisely evaluate the extent of shell damage and to provide effective treatment. A fast

method that would allow exact evaluation of the shell trauma in rescued turtles is therefore needed.

Computed tomography (CT) is an advanced method of diagnostic imaging that has proven to be a valuable tool in exotic and wildlife medicine including reptiles (Gumpenberger and Henninger 2001; Kiefer and Pees 2011; Wyneken 2014). Studies on the method and use of CT in clinical examination of tortoises and terrapins were published by Kiefer and Pees (2011); the practical use of CT in turtles was reported by Smith et al. (2000), Valente et al. (2006) and Valente et al. (2007). In chelonians CT represents a valid alternative to classical imaging techniques in evaluation of the appendicular skeleton (Abou-Madi et al. 2004; Bortolini et al. 2012), in formulating the final diagnose in cases of skeletal injuries (Abou-Madi et al. 2004; Saber and Kamal 2010) and metabolic bone disease (Raiti and

doi: 10.17221/68/2015-VETMED

Haramati 1997). CT is the safest and most sensitive method for diagnosing pathology of bones and soft tissue in chelonians (Wyneken 2014). The method also allows multiplanar reconstruction and three-dimensional images of organs and tissues inside the coelom of chelonians (Bonelli et al. 2013; Lim et al. 2013; Mans et al. 2013; Wyneken 2014).

The aim of the presented work was evaluation of the practical use of three dimensional CT for clinical examination of shell lesions in loggerhead turtles stranded and rescued near the island of Sicily.

MATERIAL AND METHODS

Animals. Six adult loggerhead turtles (*Caretta caretta*) were found stranded and rescued in the sea near Sicily within a period of 12 months (Table 1). They were transported to a wildlife rehabilitation centre of the University Veterinary Teaching Hospital, Messina, Sicily. Patients (average body weight 36.8 kg, range 20–46 kg) were subjected to a thorough physical examination, including analysis of the blood profile (haematology and plasma chemistry analyses). Severe deep lesions of the carapace and plastron were suspected to be present in two specimens (female 1 and 2). The second one (female 2) exhibited breathing difficulties. The remaining four turtles presented with shell lesions of unknown depth and possible influence on animal health and ability to dive. For better evaluation of the shell fractures and possible involvement of soft tissue organs, all six turtles were subjected to examination with computed tomography.

Anaesthesia. A combination of ketamine (15 mg/kg, Ketavet 100, Intervet, Italy) with dexmedetomidine (0.2 mg/kg, Dexdomitor, Orion Pharma, Finland) was administered intramuscularly as an induction

for inhalant anaesthesia. After tracheal tube insertion turtles were kept on inhalant anaesthesia with isoflurane (4%, Isoflo, Esteve, Spain) and oxygen. After the CT examination was done atipamezole (1 mg/kg, Antisedan, Zoetis, US) was administered intramuscularly to reverse the dexmedetomidine anaesthesia.

Computed tomography. Turtles were positioned in ventral recumbency on a large heating pad (PM24, Pet Mat®, New Zealand). High Speed CT/e (GE Healthcare, UK) with the following parameters: 120 kV, 100 mAs, 3.5 mm slices, window level from +350 to +500 HU, window width 2500 HU, were used for CT examination of turtle patients. For the multiplanar volume rendering imaging and 3D reconstructions the OsiriX software (Pixmeo, Switzerland) was used.

RESULTS

The results of CT examinations in six loggerhead turtle patients are summarised in Table 2. Turtle number 1: in addition to the shell lesions, three vertebral lesions were found, the first lesion in the 3rd thoracic-lumbar vertebra (Figures 1A and 3A), the second one in the 7th thoracic-lumbar vertebra (Figures 2B and 2C) and the third one in the 8th thoracic-lumbar vertebra (Figures 1B and 2D). In the first vertebral lesion, both the lamina and vertebral body were involved. Spinal cord compression was not found. In the other two vertebral lesions vertebral laminae were involved and spinal cord compression was not found.

Turtle number 2: loss of 10 cm of the shell tissue was found on the left side of the shell, near the carapace-plastron bridge (Figures 3A and 3B). On transverse CT images (Figures 4A and 4B) the soft

Table 1. Loggerhead turtles examined using computed tomography (*n* = 6)

Turtle	Sex	Body weight (kg)	Carapace curve	
			length (cm)	width (cm)
1	female	37	71	70
2	female	45	80	74
3	female	46	74	70
4	ND	20	62	60
5	female	40	71	66
6	ND	33	66	57

ND = not determined

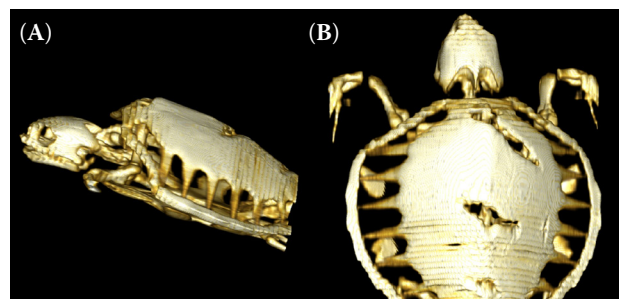


Figure 1. CT images of a loggerhead turtle. Lateral view (A) shows a lesion of the 3rd thoracic-lumbar vertebra; two lesions of the 7th and the 8th thoracic-lumbar vertebrae are shown in dorsoventral view (B)

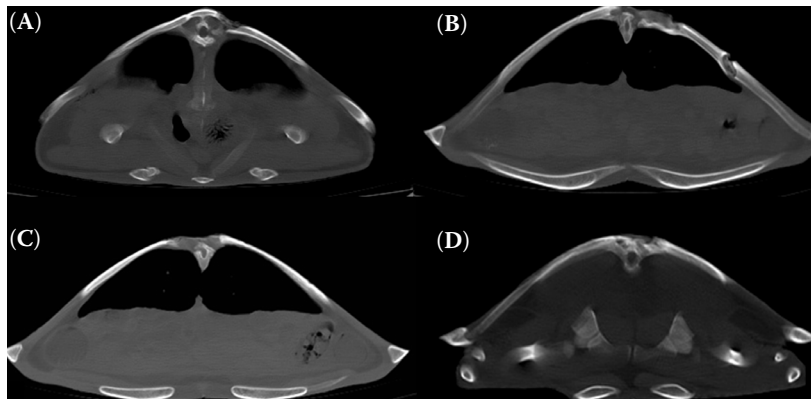


Figure 2. CT images of a loggerhead turtle 1. Transverse plane views showing three vertebral lesions: the first in 3rd thoracic-lumbar vertebra (A), the second one in the 7th (B–C) and the third one in the 8th thoracic-lumbar vertebra (D); no lesions of internal organs were found

tissues later ventral to the lung were thicker and showed less density on the left than on the right side. This was most likely indicative of haemorrhage or oedema (Figures 4C and 4D).

Coronal reconstruction (software OsiriX) of a loggerhead with massive compression of the coelom organs caused by a traumatic lesion on the shell bridge is presented in Figure 5. Turtles 3–6 had only superficial lesions, which involved neither the bone tissue nor the internal organs. In subsequent explorative laparotomy three turtles (3, 4, and 5) had plastic foreign bodies in the bowel, causing a gastrointestinal stasis, and in the last specimen (6) the reason for stranding was not identified.

Turtles 1 and 2 underwent reconstructive surgery of the shell. Antibiotic therapy (enrofloxacin 10 mg/kg *s.c.*, *q24 h*, Baytril 2.5%, Bayer, Germany)

and analgesia with tramadol (10 mg/kg *i.m.*, *q48 h*, Altadol, Formovet, Italy) according to Norton et al. (2013) were performed for two weeks after surgery. Turtles were kept in the rehabilitation centre to clean their wounds and for supportive care based on therapy with fluid (10 ml/kg *s.c.* of 1 : 1 solution with sodium chloride 0.9% and 5% dextrose), vitamin B complex (0.3 ml/kg *s.c.*, *q24 h* for seven days, Stimufos, Teknofarma, Italy) and force feeding. After three months of hospitalisation turtles were released into the rehabilitation sea area. They were presented to the clinic for health control two and four weeks after the release. Both turtles were active and in a good health condition. The remaining four turtles underwent gentle daily cleaning of the superficial lesions, with antibiotic therapy and supportive treatment similar to the first two animals.

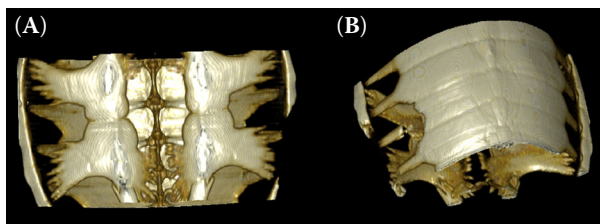


Figure 3. CT images of a loggerhead turtle 2. Ventrodorsal view (A) and oblique view (B) show the absence of a part of the left bridge (up to 10 cm)

DISCUSSION AND CONCLUSION

Veterinary surgeons are involved in turtle conservation programs by contributing to the improvement of the wild reptile's medical management. In sea turtles, traumatic injuries of the shell and soft tissue, as well as ingestion of fishhooks or plastic bags are common reasons for veterinary care

Table 2. Results of computed tomography examination in stranded loggerhead turtles ($n = 6$)

Turtle	Description of the main health complication recorded
1	vertebral lesion at the level of the 3 rd thoracic-lumbar vertebra – vertebral lamina and the vertebral body were involved without compression of the spinal cord vertebral lesion at the level of the 7 th thoracic-lumbar vertebra – vertebral lamina involved only vertebral lesion at the level of the 8 th thoracic-lumbar vertebra – vertebral lamina involved only
2	on the left side of the carapace, near the carapace-plastron bridge, loss of 10 cm of the shell massive compression of organs especially on the left lung
3–6	superficial lesions were discovered, without any connections to the bone and organs of the coelom no lesions affecting the lungs have been recorded as the possible causes of the stranding and diving difficulties

doi: 10.17221/68/2015-VETMED

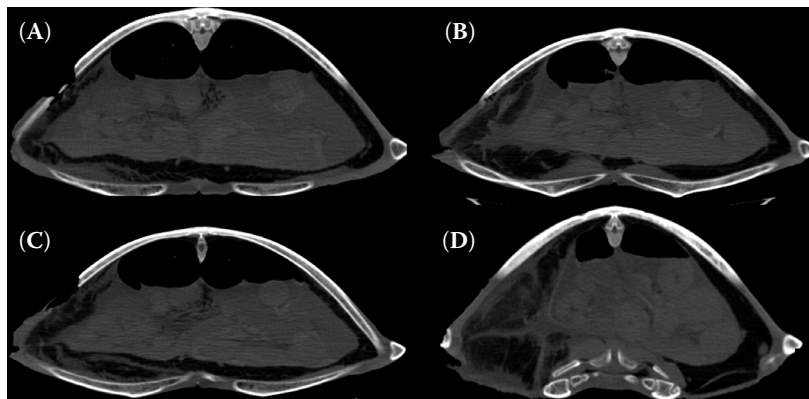


Figure 4. CT images of a loggerhead turtle 2. Transverse plane views showing depth shell lesions with the involvement of coelomic organs; the soft tissues later ventral to the lung are thicker and show less density on the left than the right side; this most likely indicates haemorrhage or oedema (arrowhead, asterisk = compressions)

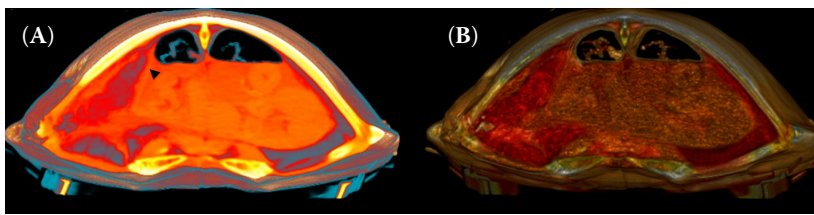


Figure 5. Coronal reconstruction (software OsiriX) of a loggerhead turtle with massive compression of the organs (black arrowhead) caused by a traumatic lesion to the shell bridge

and treatment at marine-animal rescue centres (McArthur 2004). In such cases, physical examination does not give sufficient information to allow characterisation of the exact cause of stranding, and the use of modern methods of non-invasive diagnostic imaging is necessary.

Studies dealing with diagnostic imaging in chelonians have been published (Rubel and Kuoni 1991; DeShaw et al. 1996; Hernandez-Divers and Hernandez-Divers 2001; Gumpenberger 2002; Hernandez-Divers and Lafortune 2004; Raiti 2004; Wilkinson et al. 2004; Silverman 2006). Although standard methods of veterinary radiography can be used in turtles, the final diagnosis is challenging due to superimposition of many anatomical structures. Computed tomography allows accurate definition of organs in the coelom without superimposition of adjacent structures. The slow respiratory rate in turtles minimises any possible artefacts caused by the movement of lungs (Gumpenberger 2011). The ability of CT to generate multiplanar and three-dimensional pictures provides a perfect overview of shell structures. It would not be possible to diagnose in detail the deep penetrating shell lesions that were recorded in two female loggerhead turtles in this study using radiography alone. The use of CT was useful for determining possible involvement of the spinal cord and for making the decision regarding reconstructive surgical treatment.

Computed tomography is a fast and feasible imaging method for clinical examination of stranded turtles with deep penetrating shell lesions.

Computed tomographic examinations of stranded turtle patients facilitate decisions regarding effective treatment and rehabilitation protocols.

REFERENCES

- Abou-Madi N, Scrivani PV, Kollias GV, Hernandez-Divers SM (2004): Diagnosis of skeletal injuries in chelonians using computed tomography. *Journal of Zoo and Wildlife Medicine* 35, 226–231.
- Barten SL (1996): Shell damage. In: Mader D (ed.): *Reptile Medicine and Surgery*. 1st ed. W.B. Saunders Company, Philadelphia. 413–417.
- Barten SL (2006): Shell damage. In: Mader D (ed.): *Reptile Medicine and Surgery*. 2nd ed. Saunders Elsevier, Philadelphia. 893–899.
- Bonelli MD, de Oliveira DC, Costa LAVS, Forattini JG, Rossi Jr. JL, Leite FLG, Costa FS (2013): Quantitative computed tomography of the liver in juvenile green sea turtles (*Chelonia mydas*). *Journal of Zoo and Wildlife Medicine* 44, 310–314.
- Bortolini Z, Lehmkuhl RC, Ozeki LM, Tranquili MV, Sesoko NE, Teixeira CR, Vulcano LC (2012): Association of 3D reconstruction and conventional radiography for the description of the appendicular skeleton of *Chelonoidis carbonaria* (Spix, 1824). *Anatomy Histology and Embryology* 41, 445–52.
- DeShaw B, Schoenfeld A, Cook RA, Haramati N (1996): Imaging of reptiles: A comparison study of various radiographic techniques. *Journal of Zoo and Wildlife Medicine* 27, 364–370.

- Gumpenberger M (2002): Computed tomography (CT) in chelonians. In: Proceedings of the 9th Annual Conference of Association of Reptilian and Amphibian Veterinarians, 41–43.
- Gumpenberger M (2011): Chelonians. In: Schwarz T, Saunders J (eds.): *Veterinary Computed Tomography*. Wiley-Blackwell, Oxford. 533–544.
- Gumpenberger M, Henninger W (2001): The use of computed tomography in avian and reptile medicine. *Seminars in Avian and Exotic Pet Medicine* 10, 174–180.
- Hedley J, Kubiak M (2015): Neurologic diseases of birds and reptiles. *Journal of Exotic Pet Medicine* 24, 6–20.
- Hernandez-Divers SJ, Lafortune M (2004): Radiology. In: McArthur S, Wilkinson R, Meyer J, Innis C and Hernandez-Divers SJ (eds.): *Medicine and Surgery of Tortoises and Turtles*. Blackwell Scientific Publications, London. 195–212.
- Hernandez-Divers SM, Hernandez-Divers SJ (2001): Diagnostic imaging of reptiles. In *Practice* 23, 370–391.
- Kiefer I, Pees M (2011): Computed tomography (CT). In: Krautwald-Junghanns ME, Pees M, Reese S, Tully T (eds.): *Diagnostic Imaging of Exotic Pets*. Schlutersche Verlag, Hannover. 358–367.
- Lim CK, Kirberger RM, Lane EP, Elliott DL (2013): Computed tomography imaging of a leopard tortoise (*Geochelone pardalis pardalis*) with confirmed pulmonary fibrosis: A case report. *Acta Veterinaria Scandinavica* 23, 35. DOI: 10.1186/1751-0147-55-35.
- Mans C, Drees R, Sladky KK, Hatt JM, Kircher PR (2013): Effects of body position and extension of the neck and extremities on lung volume measured via computed tomography in red-eared slider turtles (*Trachemys scripta elegans*). *Journal of the American Veterinary Medical Association* 243, 1190–1196.
- McArthur S (2004): Problem-solving approach to conditions of marine turtles. In: McArthur S, Wilkinson R, Meyer J, Innis C, Hernandez-Divers S (eds.): *Medicine and Surgery of Tortoises and Turtles*. Blackwell Scientific Publications, London. 301–307.
- McArthur S, Hernandez-Divers S (2004): Surgery. In: McArthur S, Wilkinson R, Meyer J, Innis C, Hernandez-Divers S (eds.): *Medicine and Surgery of Tortoises and Turtles*. Blackwell Scientific Publications, London. 403–464.
- Norton T, Cox S, Kaylor M, Hupp A, Thomas R, Nelsen S, Sladky KK (2013): Pharmacokinetics of Tramadol and O-Desmethytramadol in Loggerhead Sea Turtles (*Caretta caretta*). In: Proceedings of the 33rd ISTS Symposium on Sea Turtle Biology and Conservation, 2–8 February 2013, Baltimore, Maryland, 20–21.
- Raiti P (2004): Non-invasive radiology. In: Raiti P, Girling S (eds.): *BSAVA Manual of Reptiles*. British Small Animal Veterinary Association, Cheltenham. 87–102.
- Raiti P, Haramati N (1997): Magnetic resonance imaging and computerized tomography of a gravid leopard tortoise (*Geochelone pardalis pardalis*) with metabolic bone disease. *Journal of Zoo and Wildlife Medicine* 28, 189–197.
- Rubel A, Kuoni W (1991): Radiology and imaging. In: Frye FL (ed.): *Biomedical and Surgical Aspects of Captive Reptile Husbandry*. 2nd ed. Krieger Publishing, Melbourne. 185–208.
- Saber AS, Kamal BM (2010): Computed tomography and 3D reconstruction of the respiratory organs of the Egyptian Tortoise (*Testudo kleinmanni*). *Journal of Veterinary Anatomy* 3, 1–15.
- Silverman S (2006): Diagnostic imaging. In: Mader DR (ed.): *Reptile Medicine and Surgery*, 2nd ed. Saunders Elsevier, St Louis. 471–489.
- Smith CR, Turnbull BS, Osborn AL, Dube KM, Johnson KL, Solano M (2000): Bone scintigraphy and computed tomography: Advanced diagnostic imaging techniques in endangered sea turtles. In: Proceedings of the 7th Annual Conference of Association of Reptilian and Amphibian Veterinarians, 217–221.
- Valente AL, Parga ML, Espada Y, Lavin S, Alegre F, Marco I, Cuenca R (2006): Topographic anatomy and normal multi-detector computed tomography of the coelomic structures of the loggerhead sea turtle (*Caretta caretta*). In: Proceedings of the 26th Annual Symposium on Sea Turtle Biology and Conservation, Crete, Greece. 76 pp.
- Valente AL, Cuenca R, Zamora M, Parga ML, Lavin S, Alegre F, Marco I (2007): Computed tomography of the vertebral column and coelomic structures in the normal loggerhead sea turtle (*Caretta caretta*). *The Veterinary Journal* 174, 362–370.
- Wilkinson R, Hernandez-Divers S, Lafortune M, Calvert I, Gumpenberger M, McArthur S (2004): Diagnostic imaging. In: McArthur S, Wilkinson R, Meyer J, Innis C, Hernandez-Divers S (eds.): *Medicine and Surgery of Tortoises and Turtles*. Blackwell Scientific Publications, London. 187–238.
- Wyneken J (2014): Computed tomography and magnetic resonance imaging. In: Mader DR, Divers SJ (eds.): *Current Therapy in Reptile Medicine and Surgery*. Elsevier, St. Louis. 93–106.

Received: 2015–03–16

Accepted after corrections: 2016–05–23

Corresponding Author:

Zdenek Knotek, Prof., MVDr, Ph.D. Dipl ECZM (Herpetology), University of Veterinary and Pharmaceutical Sciences Brno, Faculty of Veterinary Medicine, Avian and Exotic Animal Clinic, 1/3 Palackeho St., 612 42 Brno, Czech Republic
E-mail: knotekz@vfu.cz