University of Messina

PhD Program XXXI Cycle

Medical and Surgical Biotechnologies

Coordinator: Prof. Giovanni RAIMONDO

EVALUATION OF BREATHING PATTERN AND SERUM LEVELS OF INSULIN-LIKE GROWTH FACTOR-1 AFTER RAPID MAXILLARY EXPANSION IN GROWING PATIENTS: A MULTICENTRIC RANDOMIZED CLINICAL TRIAL

PhD Thesis of:

Dr. Rosamaria Fastuca

Tutor: ***Chiar. mo Prof. Giovanni RAIMONDO***

INDEX

ABSTRACT

Background No evidence has been found on metabolic or hormonal changes involving growth hormone and its mediators after rapid maxillary expansion. The aim of the present randomized clinical trial was therefore to determine changes in apnea/hypopnea index, oxygen saturation and serum levels of insulin-like growth factor-1 in growing patients treated with rapid maxillary expansion.

Methods Treated group comprised 16 patients (10 males and 6 females) with a mean age of 9.50±1.39 years and control group comprised 16 patients (11 males and 5 females) with a mean age of 9.9±0.92 years. All patients of the treated group underwent maxillary expansion with Hyrax-type expander while control group underwent no treatment. Polysomnography exam and blood samples for the evaluation of serum levels insulin-like growth factor-1 were collected at baseline and after 12 months.

Results Apnea/hypopnea index significantly decreased of -1.82 events/hour in the treated group compared to the control. Insulin-like growth factor-1 also showed significant increase of 20.68 ng/mol in the treated group compared to control group. No significant differences were reported for oxygen saturation.

Conclusions Growing patients presenting mild OSA showed significant improvement of AHI and increase of insulin-like growth factor-1 after RME when compared to control, while no significant differences were reported for oxygen saturation.

BACKGROUND AND PREFACE

The present thesis will include the results of an experimental study (RCT) performed during the whole PhD program starting with a general brief introduction on the background of the topic. Then the introduction will be enhanced with a review of literature which will examine the current literature on the topic underlining the Author's contributions published over the PhD program that were performed as parallel studies to better explore different aspect and phases of the main topic. The Author's contributions will be underlined at the beginning of the paragraphs where needed. The description of the RCT will follow in details and future perspectives will be explored.

The implications and the effects of breathing on craniofacial growth have been widely debated as a controversial issue within orthodontics for decades (Caprioglio et al., 1999; Flores-Mir et al., 2013). The influence of breathing on mandibular growth were investigated suggesting accelerated mandibular growth and closure of the mandibular plane angle, although with a large variation, after adenoidectomy to facilitate nasal breathing (Linder-Aronson et al., 1986). In all individuals, muscular activity is reduced and upper airway resistance increased during sleep compared when awake (Worsnop et al., 2000). This does not have a notable effect on breathing in anatomically and functionally healthy individuals. On the other hand, reduction of muscular tone in children with large adenoids and tonsils, or with other underlying abnormal upper airway anatomy, may lead to airway obstruction and eventually to obstructive sleep apnea (OSA) (McNamara et al., 2015).

Along with breathing issues and craniofacial characteristics, body growth retardation was frequently observed in OSA patients (Bar et al., 1999; Nieminem et al., 2002). The complex

mechanisms behind growth retardation are still unclear. OSA might interrupt slow-wave sleep, when growth hormone (GH) is preferentially secreted and this phenomenon was observed also in chronic snorers not diagnosed for OSA. GH modifications were often related to serum levels of insulin-like growth factor-1 (IGF-1) and IGF-binding protein 3 (IGFBP-3) (Gümüssoy et al., 2009) which are related to diurnal GH secretion and reflect its anabolic role on tissues, especially muscle and bone. IGF-1 resulted significantly increased in children after tonsillectomy and adenoidectomy (T&A) surgery in previous studies thus suggesting a relevant role of the IGF-1 axis in growth retardation of children with upper airway obstruction and the consequent growth catch-up (Nieminem et al., 2002; Gümüssoy et al., 2009).

Rapid maxillary expansion (RME) is an orthodontic procedure commonly used to perform skeletal expansion of maxillary bones and it has been reported to be effective also for the upper airway increase due to the direct force exerted on the nasal area in young individuals (Caprioglio et al., 2014, 2017, 2017; Fastuca et al. 2015, 2015, 2017). Polysomnography (PSG) examinations showed improvement of the breathing pattern not only in the short-term, but also after 24 months follow-up (Villa et al., 2011).

No evidence has been found on metabolic or hormonal changes involving GH after RME. Since breathing pattern improvement was showed after treatment in some patients undergoing RME (Fastuca et al. 2015; Villa et al., 2011), the hypothesis of associated changes in GH levels might be worth investigating along with the changes in breathing pattern as showed in severe OSA patients after T&A.

REVIEW OF LITERATURE

Maxillary Expansion

History of RME

RME is a commonly used non-surgical maxillary expansion technique (Ekstrom et al., 1977) for the correction of maxillary width deficiency and posterior cross bite by increasing the width of the dental arch (Haas,1970) and of the nasal cavity (Enoki et al., 2006). Emerson C. Angell described the first clinical use of RME in 1860 reporting a case of a fourteen year old girl in whom a jackscrew across the roof of the mouth with its ends bearing against the first and second bicupsids of one side to the other corrected the maxillary transverse deficiency (Angell, 1860). Despite initial arguments against this novel technique based on the possibility of inducing serious disturbance in the surrounding hard and soft tissue, RME was attempted with varying degree of success by several practitioners during the late 1890's through the late 1920's. The earliest report of RME to specifically enhance breathing dates back to 1903 when G. Brown observed that the nasal width increased after separating the maxilla in young individuals. A few years later, a RME study evaluating the intranasal changes revealed that the distance between the lateral walls of the nasal cavity below the inferior concha increased and the subjective intranasal respiration improved (Wright 1912). During the 1930's and 1940's the use of maxillary expansion was almost completely abandoned in the United States due to the widespread acceptance of the functional theory advocating bone growth in presence of vigorous function and proper dental relations.

Over a century after the first RME publication, Haas re-introduced the concept of RME based on a successful pilot animal study followed by a human case series consisting of 45 subjects with maxillary or nasal insufficiency. The expansion was accomplished by activating the jackscrew 0.5mm per day (0.25 mm in the morning and 0.25 mm in the evening) for 21 consecutive days followed by a retention phase of 3 months. Pre, post and follow up records (frontal, lateral cephalometric X rays, dental casts and patient's subjective opinion) demonstrated the existence of a significant expansion between the mid palatal sutures, between lateral walls of the nasal cavity and the maxillary intermolar distance along with unanimous subjective improvement in nasal respiration. In addition, a triangular pattern of maxillary suture opening with the base towards the palate and the apex towards the nose, an initial forward and downard movement of the maxilla, mesial drift of the maxillary incisors after initial diastema formation, and uprighting of the mandibular teeth were also reported. Haas postulated that the initial gross reaction of the maxillary expansion was a lateral bending of the alveolar processes followed by a gradual opening of the midpalatal suture and that the zygomatic buttresses caused the separation of the maxillary halves to be wedged shaped with the apex towards the nasal cavity (Haas 1961, 1970). Interestingly, fifty years after Haas documented his findings, very little additional information has been added to this topic other than confirming what has already been reported.

Skeletal Response and Stability

RME can be achieved through the use of tooth-tissue borne or tooth-borne appliances that are fixed to the teeth either by bands or chemical bonding which are capable of producing heavy forces in the range of 15 to 50 Newton (Lagravere et al., 2005). Originally, RME was thought

to provide mostly orthopedic movement of the maxillary bones with minimal orthodontic tooth movement (OTM). However, OTM continues during the retention phase until bone stability is reached, by 4 months true orthopedic maxillary transverse width gain accounts for about half the gained expansion while the remaining comes from the lateral dental movements on their supporting bone (Proffit, 2007). In a cone beam computed tomography (CBCT) study evaluating 3 months post RME skeletal response in 30 consecutive orthodontic patients, the maxillary 1st inter-premolar (P1) and 1st inter-molar (M1) width measured from each buccal plates increased 6 mm and 6.6 mm respectively. However, when the expansion was further analyzed, the sutural orthopedic expansion accounted for only 55% and 38 % at P1 and M1 respectively of the total expansion. The remaining expansion was derived from a significant dental tipping accounting for 39% and 49% at P1 and M1 respectively and a minor contribution from the alveolar plate expansion added 6% and 13% at P1 and M1 respectively. The combined data clarified how the maxillary expansion actually occurs and also demonstrated that a decreasing orthopedic skeletal effect and increasing orthodontic tipping and alveolar bending effect exist from anterior to posterior (Garrett et al., 2008). Slow maxillary expansion on the other hand, consists of expanding the palate at a much lower rate using smaller expanding forces (0.5 mm per week) equivalent to the maximum rate at which the tissues of the midpalatal suture can adapt (Proffit, 2007). A study analyzing the long term effects of maxillary expansion from initial, post treatment and post retention dental casts measuring the points intersecting the lingual groove and the gingival margin of the maxillary first molars revealed that both: slow maxillary expansion (SME) and RME techniques were efficient in correcting the transverse discrepancy. The arch width for the SME group increased by 3.4 mm with 0.29 mm relapse while the RME group increased by 5.95mm and relapsed 0.46 mm at 10 year post retention follow up. Unfortunately, a direct comparison of maxillary

expansion efficiency could not be reached due to the decision of using SPE or RPE based on the severity of the transverse discrepancy preferring SPE when smaller transverse discrepancies were present (Filho et al., 2008).

Midpalatal suture response

Author's contributions

Giuliani A, Mazzoni S, Mangano C, Zecca PA, Caprioglio A, Vercellini N, Raspanti M, Mangano F, Piattelli A, Iezzi G, Fastuca R. Osteo-regeneration personalized for children by rapid maxillary expansion: an imaging study based on synchrotron radiation microtomography. BMC Oral Health. 2018 Jul 25;18(1):125.

Caprioglio A, Fastuca R, Zecca PA, Beretta M, Mangano C, Piattelli A, Macchi A, Iezzi G. Cellular Midpalatal Suture Changes after Rapid Maxillary Expansion in Growing Subjects: A Case Report. Int J Mol Sci. 2017 Mar 11;18(3).

Dimensional changes in the midpalatal suture produced by RME in growing subjects have been investigated by conventional radiographic techniques (Da Silva Filho et al., 1995) and CBCT (Acar et al., 2015; Franchi et al., 2010). Radiographic studies showed significant density reduction along the midpalatal suture at the end of active expansion and an increase in sutural density after 6 months of retention, indicating reorganization of the midpalatal suture (Acar et al., 2013). Along with radiographic investigations, morphologic and histologic studies in animals have been performed in order to assess changes in the midpalatal suture due to expansion procedures. Histologic investigations in animals showed that mechanical separation

at the midpalatal suture gained by RME is a multiple step healing process, characterized by new bone and connective tissue formation, followed finally by remodeling (Storey, 1955; Cleall et al., 1965; Murray et al., 1971; Ohshima, 1972). Remodeling seems to be continuous, but Storey reported that even after 3–4 weeks the normal serrated inter digitated form of suture had not yet been reconstituted. Melsen (1972, 1975) performed the first and only investigation on human beings by collecting bioptic samples at the midpalatal sutures of eight children ranging from 8 to 13 years of age, at various stages during and following RME, starting from 3 weeks after the end of the active expansion phase with autoptic samples as controls. Melsen (1972, 1975) found that a true stimulation of sutural growth was reported only in children before the pubertal growth spurt. When the patient become older several microfractures in the sutural region were found, influencing healing processes and preventing further growth within the midpalatal suture. Deepening knowledge of histologic response to RME treatment and healing processes is indeed helpful in order to better understand the timing for starting treatment since younger patients seemed to have a more favorable response. Moreover, important information might be derived from the investigation of healing time and phases in order to be oriented in choosing correct retention time intervals and preventing relapse. To our best knowledge, only Melsen (1972) investigated these important aspects in human beings, arising then the need for further confirmation of previously reported results. Furthermore, considering that a long time has passed since the publication of the previously cited article, an update might be useful. In any case, Melsen did not enroll bioptic controls since the investigation used autopsy material as the control. The present Author recently published two reports on the effects of RME on midpalatal suture (Caprioglio et al., 2017; Giuliani et al., 2018). The reported case report aimed to investigate changes in midpalatal suture in humans 7 and 30 days following RME with bioptic control samples.

Three patients (1 female and 2 males, mean age 8.3 ± 0.9 years) were enrolled in the study who presented a supernumerary tooth located at the maxillary midline which had caused anomalies in the position of the upper incisors and for this reason need to be surgically removed. Indeed, the sample was enrolled for the presence of a median maxillary supernumerary unerupted tooth (mesiodens) in mixed dentition, which had to be removed since causing eruption problems to the upper incisors in each single case. Two patients (1 female, subject 1 and 1 male, subject 2) presented maxillary transverse deficiency that needed to be corrected with RME treatment before the supernumerary tooth extraction thus facilitating surgical procedure by reducing the amount of bone around the extraction site. The third patient did not need RME treatment but was enrolled as control (subject 3) since the supernumerary tooth on the maxillary midline was present. Each patient underwent CBCT recording prior to the surgical treatment to accurately plan the surgery (Fig. 1).

Figure 1. *Volume rendering of the pretreatment cbct: (a and b) treated patients; (c) control patient.*

RME was performed until dental overcorrection. The expander was then kept on the teeth as a passive retainer and the patients underwent no further orthodontic treatment during retention (Fig. 2).

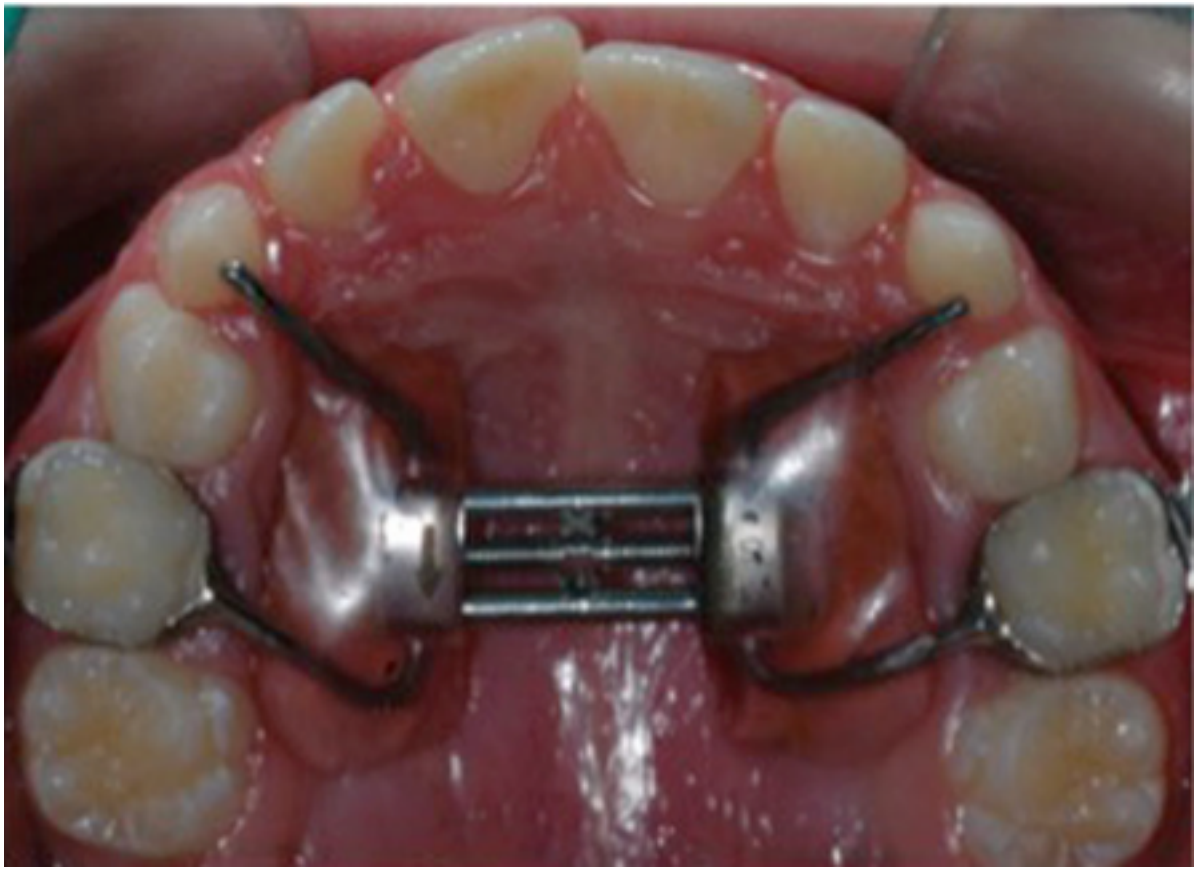

Figure 2. *Modified Haas-type expander anchored to deciduous teeth.*

The samples were harvested with the clinical aim to remove bone for the supernumerary tooth extraction. When possible, maxillary suture and bone margins were both included in the sample. All the biopsies were processed for histology in the first investigation (Fig. 3-15) (Caprioglio et al., 2017) and evaluated by complementary imaging techniques, namely

Synchrotron Radiation-based X-ray microtomography (microCT) and comparative light and electron microscopy, in a second investigation (Giuliani et al., 2018).

Midpalatal suture changes after RME were reported to be of great interest (Liu et al., 2015) since a deeper knowledge of this processes might help in treatment options and modalities. The reported case report aimed to investigate immediate histologic changes in midpalatal suture in humans following RME compared to control and was conducted on selected patients who had to perform surgery in the palatal area for other clinical reasons. A similar previous investigation did not enroll biopsy controls (Melsen, 1972) which were instead enrolled in the cited case report. Despite the young age (8.3+/-0.9 years), the subjects exhibited suture gap but with inter-digitations in the midpalatal suture, as previously reported in patients around the age of 10 (Melsen, 1972). At this age, changes in suture morphology from squamosity to sinuosity were observed (Melsen, 1972), supporting the cited report since remodeling of the bone margins of the palatal suture was evident with different maturation stages of the newly-formed bone areas characterized by wide osteocyte lacunae. Moreover, the morphology of the suture at this age (subject 3) presented a parallel orientation of the collagen fibers related to the suture long axis similar to lamellar bone, which is traditionally considered as a stress-strain resistant type of bone. RME performed in pre-pubertal age might avoid fracture of inter-digitations due to immature stages of growth and bone remodeling (Liu et al., 2015). Seven days after the end of expansion (subject 1) newly-formed bone with osteoid matrix undergoing mineralization was evident not only on the bone margins, indicating mineralization processes from within the center of the suture, which seemed to be an original finding of the investigation, as was the peculiar fishbone appearance of the trabecular bone. Moreover, newly-formed bone showed collagen fibers in a transversal orientation related to the suture long axis in comparison to the control sample, where a longitudinal orientation was observed.

This orientation was suggested to be related to the response to mechanical forces as shown in mice and this finding has never been reported in humans (Hou et al., 2007). Within the suture few areas of blood clot with several red blood cells were observed, probably caused by the trauma of maxillary expansion, but no inflammation cells were reported. This result is in contrast with Melsen who reported hyperemia and inflammation associated with osteoblastic activity near to the bone margins in the midpalatal suture 3 weeks after expansion. Inflammation cells were not evident at 7 and 14 days after expansion also in several animal investigations, meanwhile the osteoblastic activity was reported right after the midpalatal splitting (Murray et al., 1971). Cleall et al. (1965) found predominantly disruptive, inflammatory processes and osteoclastic activity in monkeys. The initial inflammatory aspect was reported only in these investigations, meanwhile the hyperemia seemed to be present in all the performed studies on animals (Storey, 1955; Cleall et al., 1965) and human beings (Melsen, 1972) in the first few days after midpalatal suture separation. In the case report no inflammation cells nor osteoclastic activity was noted. Although inter digitations were present in the suture at this stage of growth the suture morphology was still immature. At 30 days (subject 2) there was a 29% increase of newly-formed bone which showed thicker trabeculae and the peculiar fishbone appearance with parallel orientation and confluent in several areas. Diffused osteoblastic activity was evident also at this stage but also vascular activity was noted. Similar results were reported by Melsen (1972) who found newly-formed bone along the margins and in the middle of the suture with confluent islands in cross-section bony extensions 4 weeks after the end of expansion but no angiogenesis was reported and the normal serrated inter-digitated shape of suture had not yet been reconstituted. The results of the cited investigation are limited to the restricted number of patients, since bone biopsy is not ethically justified only to assess treatment outcomes. Therefore, only patients who had to

undergo surgery for clinical reasons could be selected. Furthermore, the results are limited to the appliance that was tooth-anchored on primary teeth. Moreover, the observation time was limited to 30 days after RME but it would be very useful to perform long-term investigations. The quantity of RME might affect the suture since rapid expansion protocols were shown to create midpalatal suture separation followed by the filling of the defect with new bone. Once the midpalatal suture separation is obtained, the amount of expansion might affect the healing time of the bone that starts after the midpalatal separation and keeps going for several months after. The sample harvested from subject 2 showed more advanced healing processes compared to subject 1.

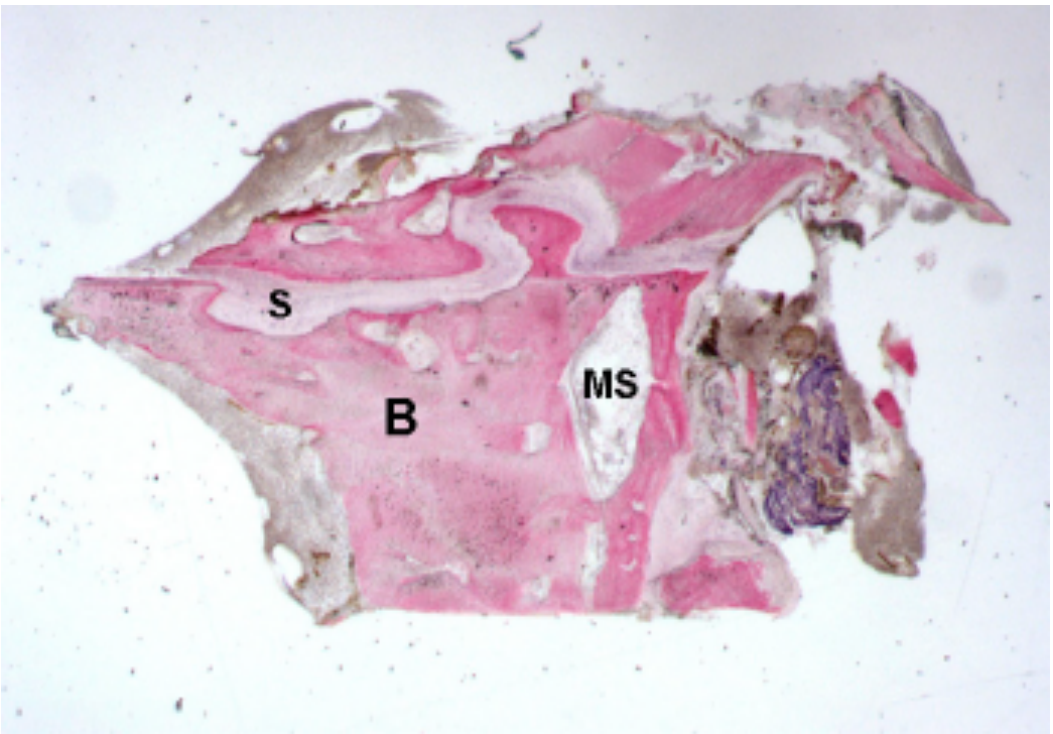

Figure 3. *Control. Mature bone (B) with small marrow spaces (MS) was observed. The gap of the palatal suture (S) appeared characterized by inter-digitations. Toluidine blue and acid fuchsin were used. Original magnification 12x.*

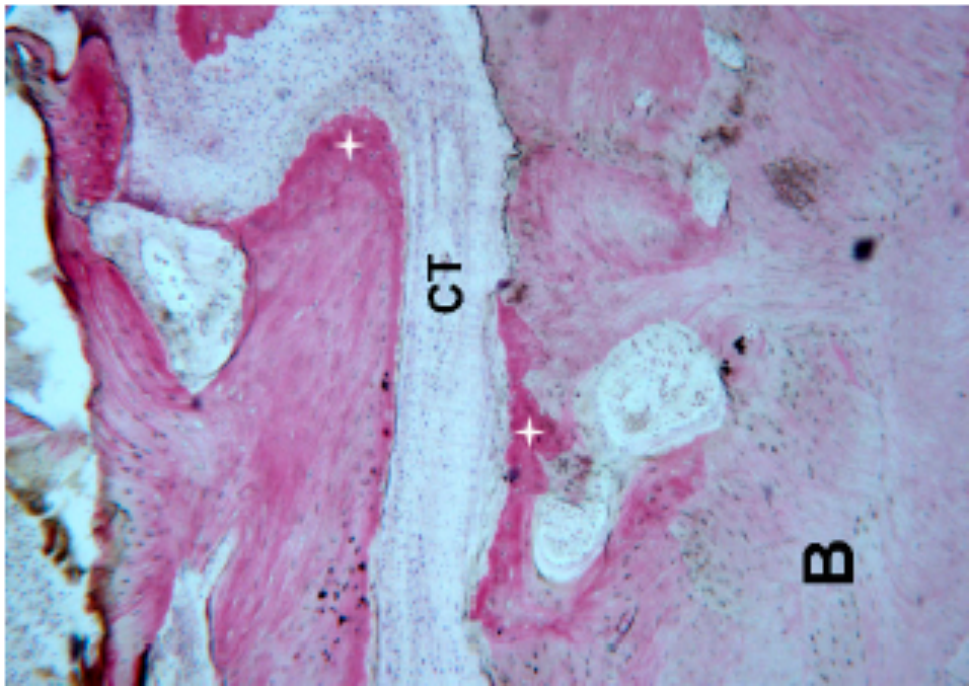

Figure 4. *Control. Connective tissue (CT) in the middle of the suture as well as mature bone (B) and newly formed bone (+) was observed. Toluidine blue and acid fuchsin were used. Original magnification 40x*

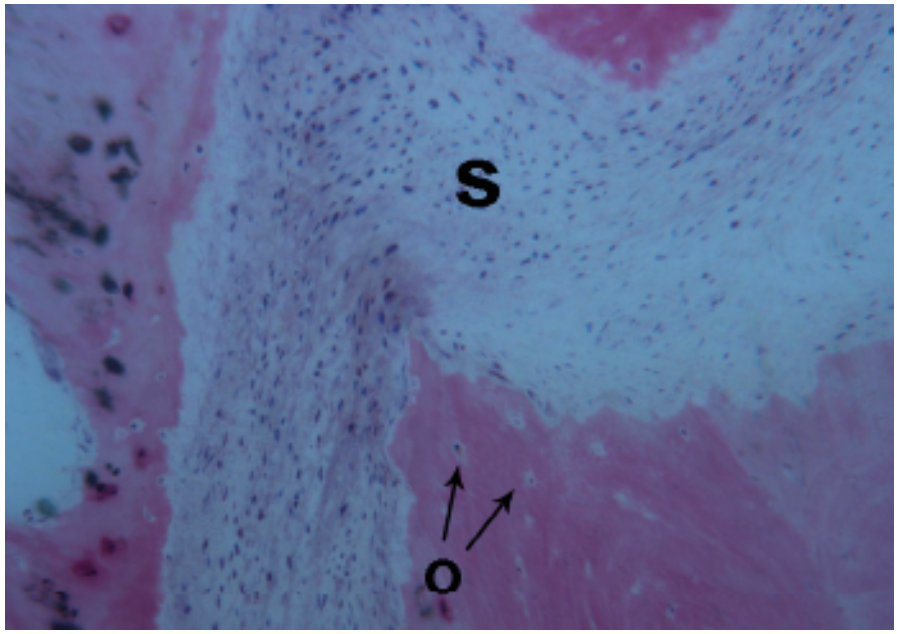

Figure 5. *Control. The bone margins of the suture (S) were irregular. New bone with wide osteocyte lacunae (O black arrows) was observed. Toluidine blue and acid fuchsin were used. Original magnification 100x.*

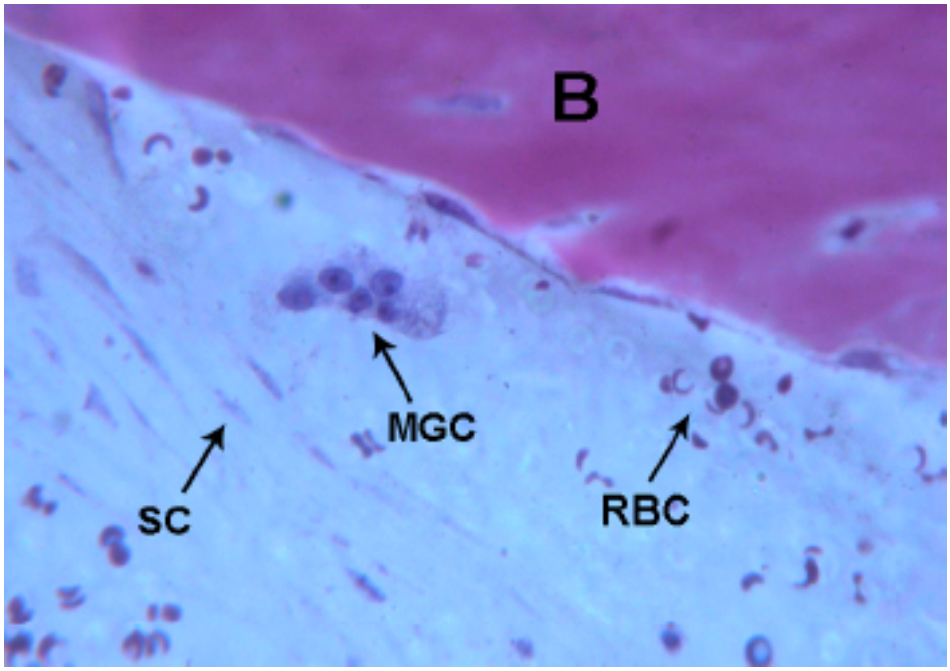

Figure 6. *Control. Multi-nucleated giant cells (MGC) near the marginal bone, spindle cells (SC) and red blood cells were observed (RBC). Bone (B).Toluidine blue and acid fuchsin were used. Original magnification 400x.*

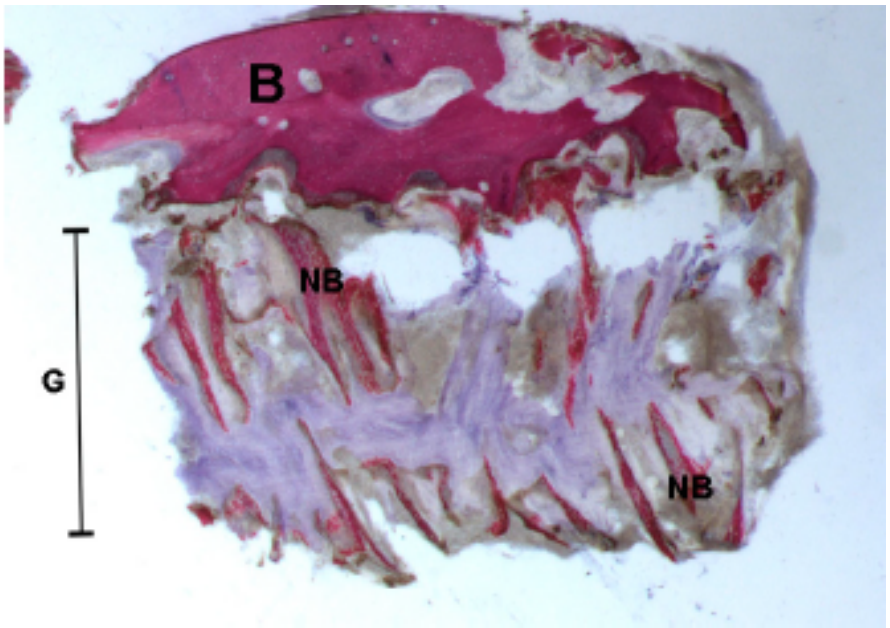

Figure 7. *Mature bone with small marrow spaces (B) and, in the gap (G) after rapid maxillary expansion, trabecular new bone (NB) with storiform appearance was observed. Toluidine blue and acid fuchsin were used. Original magnification 12x.*

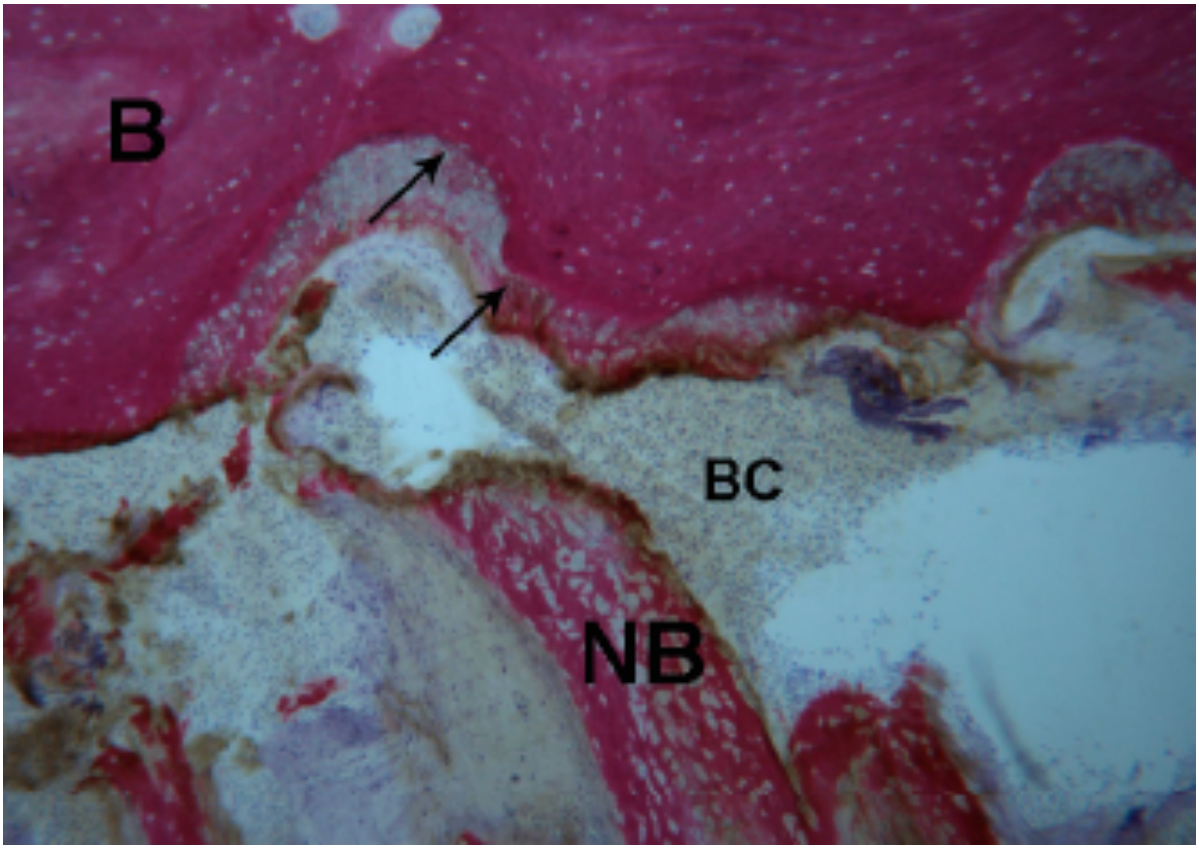

Figure 8. *Test 7 days. The bone margins of the suture were characterized by inter-digitations (black arrows), where the newly-formed osteoid matrix undergoing mineralization directly was also observed. Inside the suture, newly-formed trabecular bone (NB) was detected. In the suture gap a blood clot (BC) was present. Toluidine blue and acid fuchsin were used. Original magnification 40x.*

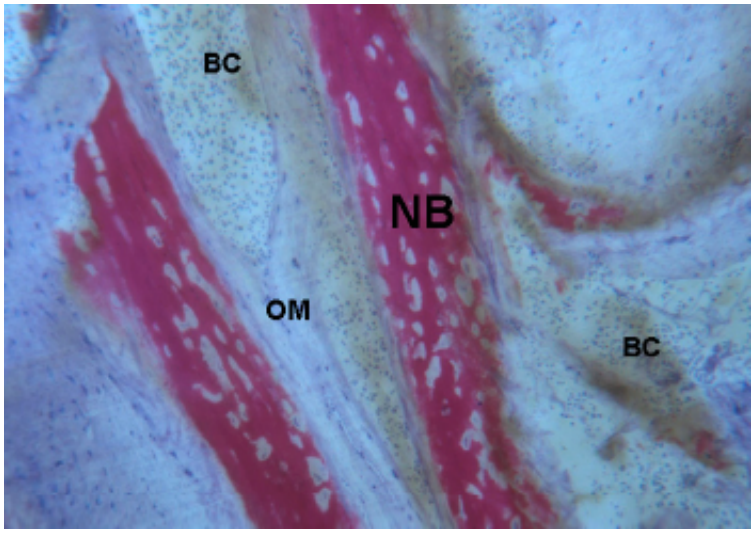

Figure 9. *Test 7 days. The trabecular newly formed bone (NB) had a parallel trend and was surrounded by osteoid matrix (OM) undergoing mineralization. In a few areas of the blood clot (BC) numerous red blood cells were present. Toluidine blue and acid fuchsin were used. Original magnification 100x.*

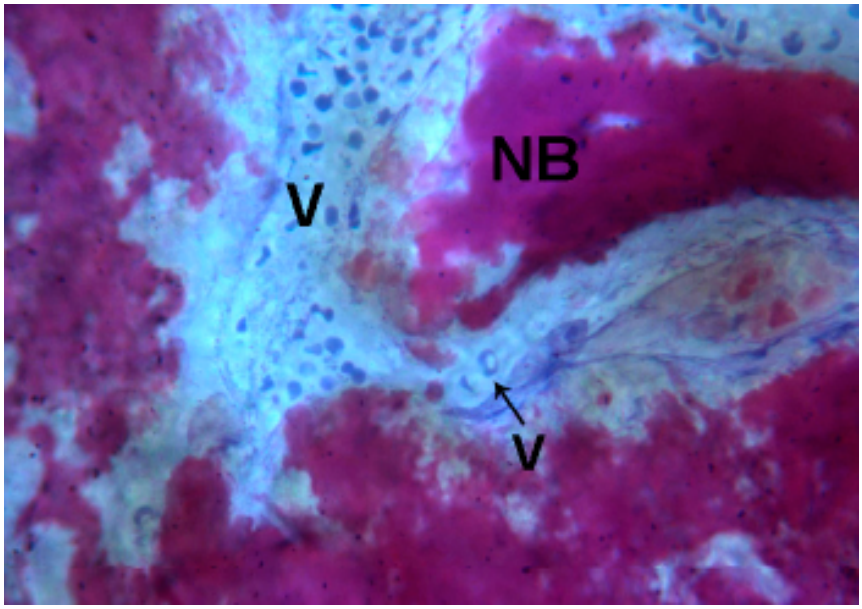

Figure 10. *Test 7 days. Newly-formed spicules (NB) close to large (V) and small vessels (V and black arrow were observed. Toluidine blue and acid fuchsin were used. Original magnification 200x.*

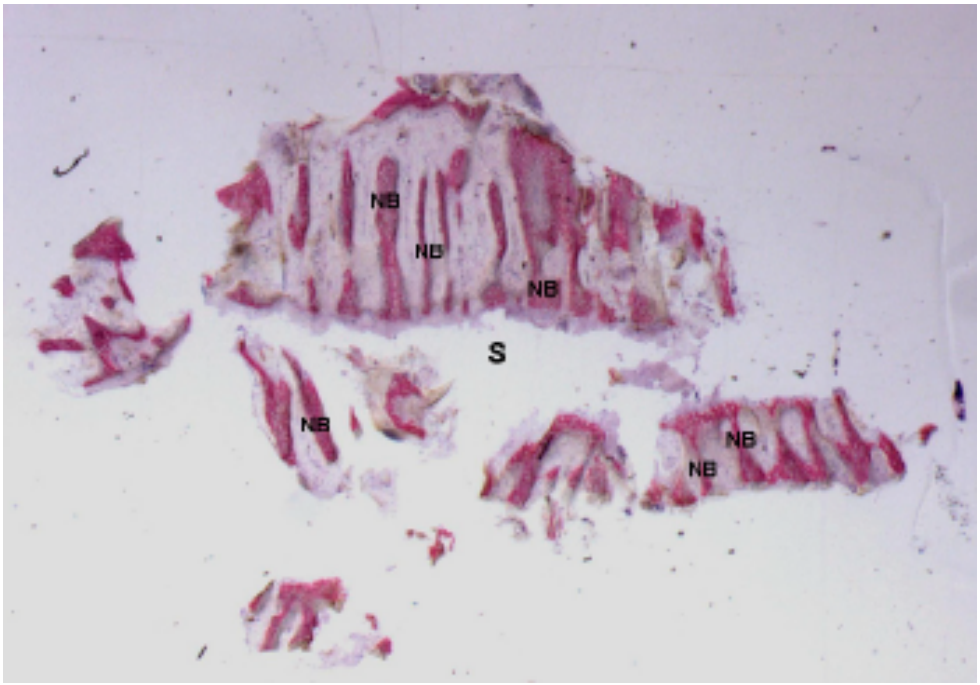

Figure 11. *Test at 30 days. The newly-formed bone trabeculae (NB) were oriented perpendicularly to the long axis of the suture (S) and run parallel to each other. Toluidine blue and acid fuchsin were used. Original magnification 9x.*

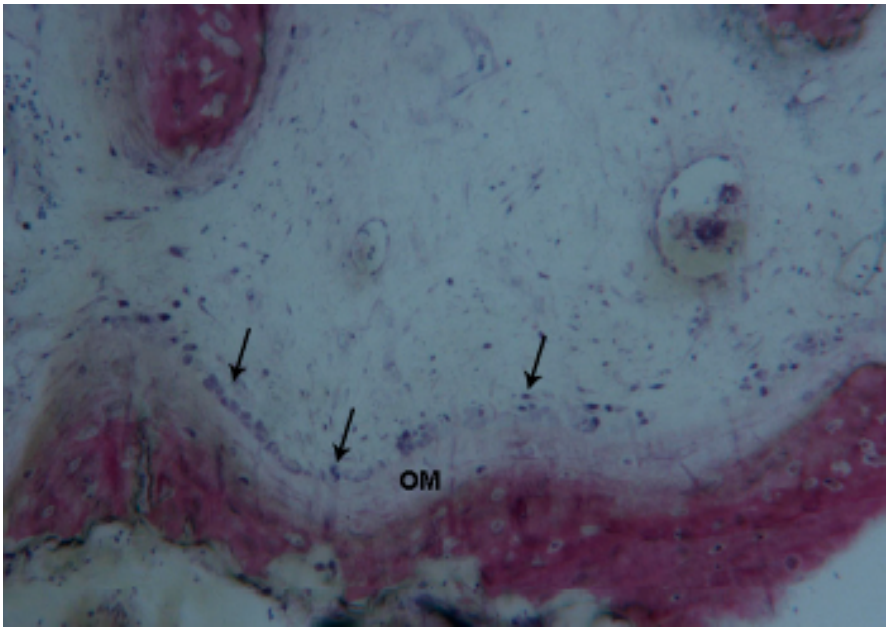

Figure 12. *Test at 30 days. A small portion of the bone margins of the palatal suture was evident, lined by osteoblasts (black arrows) producing osteoid matrix (OM). Toluidine blue and acid fuchsin were used. Original magnification 100x.*

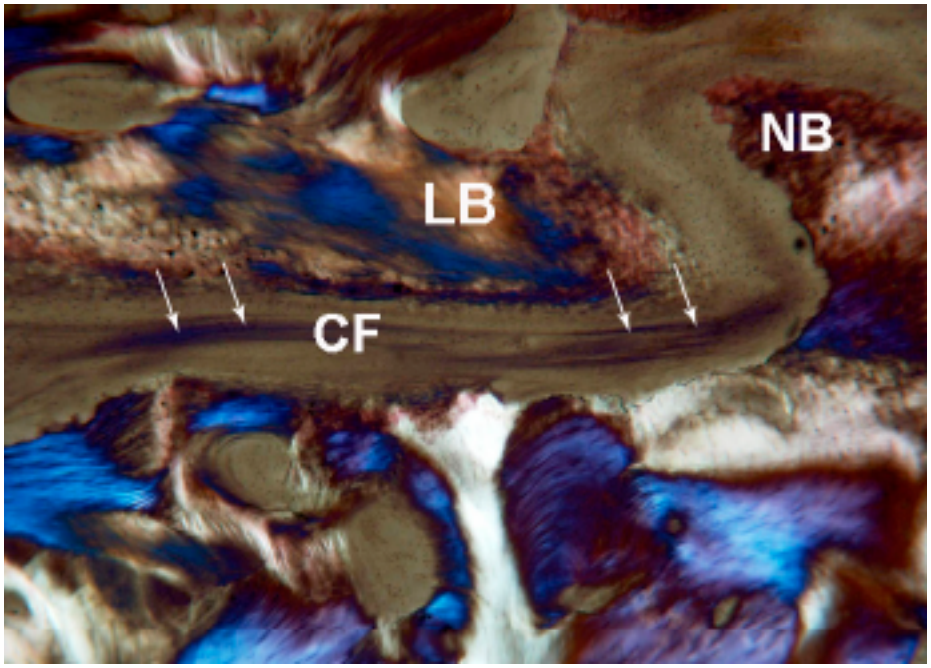

Figure 13. *Control. Under polarized light, parallel lamellar bone (LB) and newly-formed bone (NB) without parallel collagen fiber orientation were observed. In the middle of the suture collagen fibers (CF white arrows) oriented parallel to the long axis of the suture were seen. Toluidine blue and acid fuchsin were used. Original magnification 40x.*

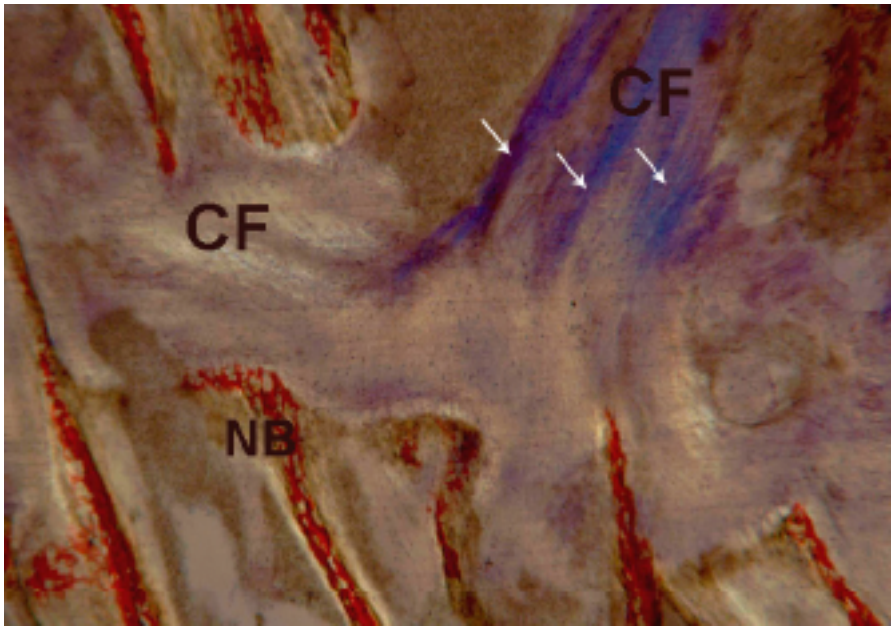

Figure 14. *Test at 7 days. Under polarized light, newly-formed bone (NB) and collagen fibers (CF) with a storiform orientation (white arrows) were observed. Toluidine blue and acid fuchsin were used. Original magnification 40x.*

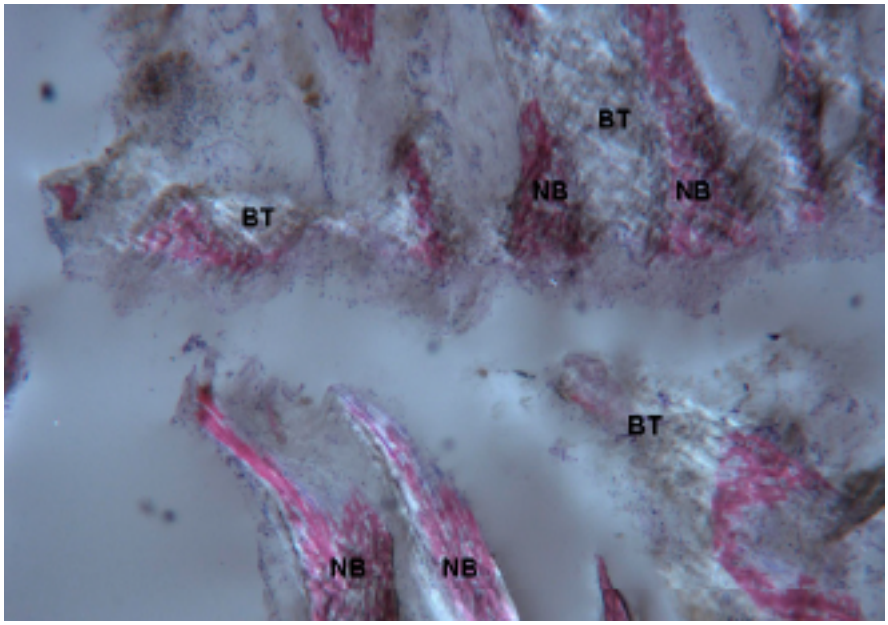

Figure 15. *Test at 30 days. Under polarized light, newly-formed bone (NB) undergoing mineralization could be observed. Not yet organized newly-formed bone trabeculae (BT) were also evident. Toluidine blue and acid fuchsin were used. Original magnification 40x.*

As documented in literature (Giuliani, 2016), it is often suggested to couple 2D conventional microscopy with advanced 3D quantitative analysis. Indeed, with the use of microCT, it is reasonable to get significant morphometric results on a statistical sample sometimes narrower than the number of patients involved in the histologic study (Suresh et al., 2012). In the second study, microCT allowed to achieve significant quantitative results (Fig. 16-18) in spite of including a single subject for comparisons at 7 days, 30 days after RME, and a control. Indeed, the previous case report (Cparioglio et al. 2017) on the same subjects was only descriptive and exclusively based on 2D data. In agreement with histological findings, this microCT study detected a relevant amount of newly formed bone both 7 and 30 days after RME. Furthermore, as previously reported (Caprioglio et al., 2017), it was observed a progressive mineralization with the peculiar in-plane fishbone appearance of the trabecular bone. As reported in literature

(Storey, 1955), the suture mineralization and morphology were confirmed in 3D to be still immature respect to the control, also 30 days after RME. However, the microCT analysis did not confirm in 3D another finding observed in 2D by light and electron microscopy, i.e. that the newly formed bone trabeculae were oriented perpendicularly to the long axis of the suture and run parallel to each other. Several microCT data contributed to denying in 3D this observation: the calculated value of DA, both 7 and 30 days after the RME, suggests a rather isotropic and poorly oriented structure; the combined significant increase in the number of trabeculae and their connectivity is not compatible with a structure consisting of parallel trabeculae.

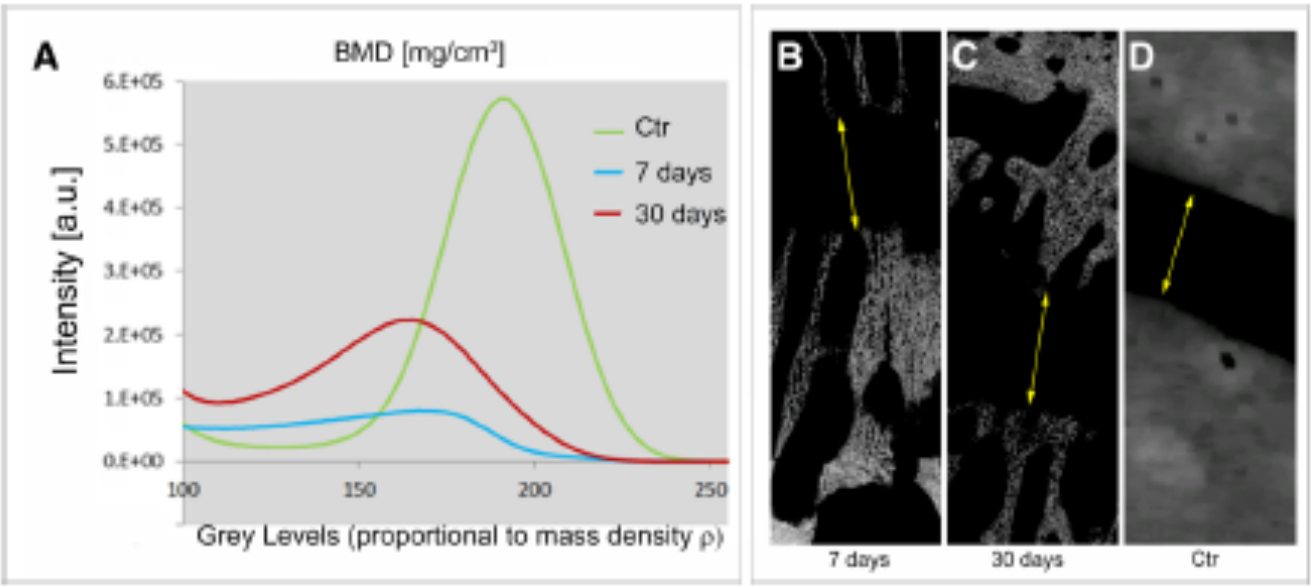

Figure 16. *Portion of the "intensity vs. gray levels" profile. The grey levels are proportional to the linear attenuation coefficient μ that, in turns, is nearly proportional to ρ, the bone mineral density (BMD). The integrated areas of the represented peaks correspond to the newly formed mineralized bone volume in RME-treated midpalatal sites and in the control. b-d Representative 2D sections of the treated palatal sites 7 days (b) and 30 days (c) after RME, and of the palatal control (d). The thickness of the suture channel was similar to that of the control suture (400–700 μm, yellow arrows), showing that the storiform way of remineralization was already started 7 days after RME*

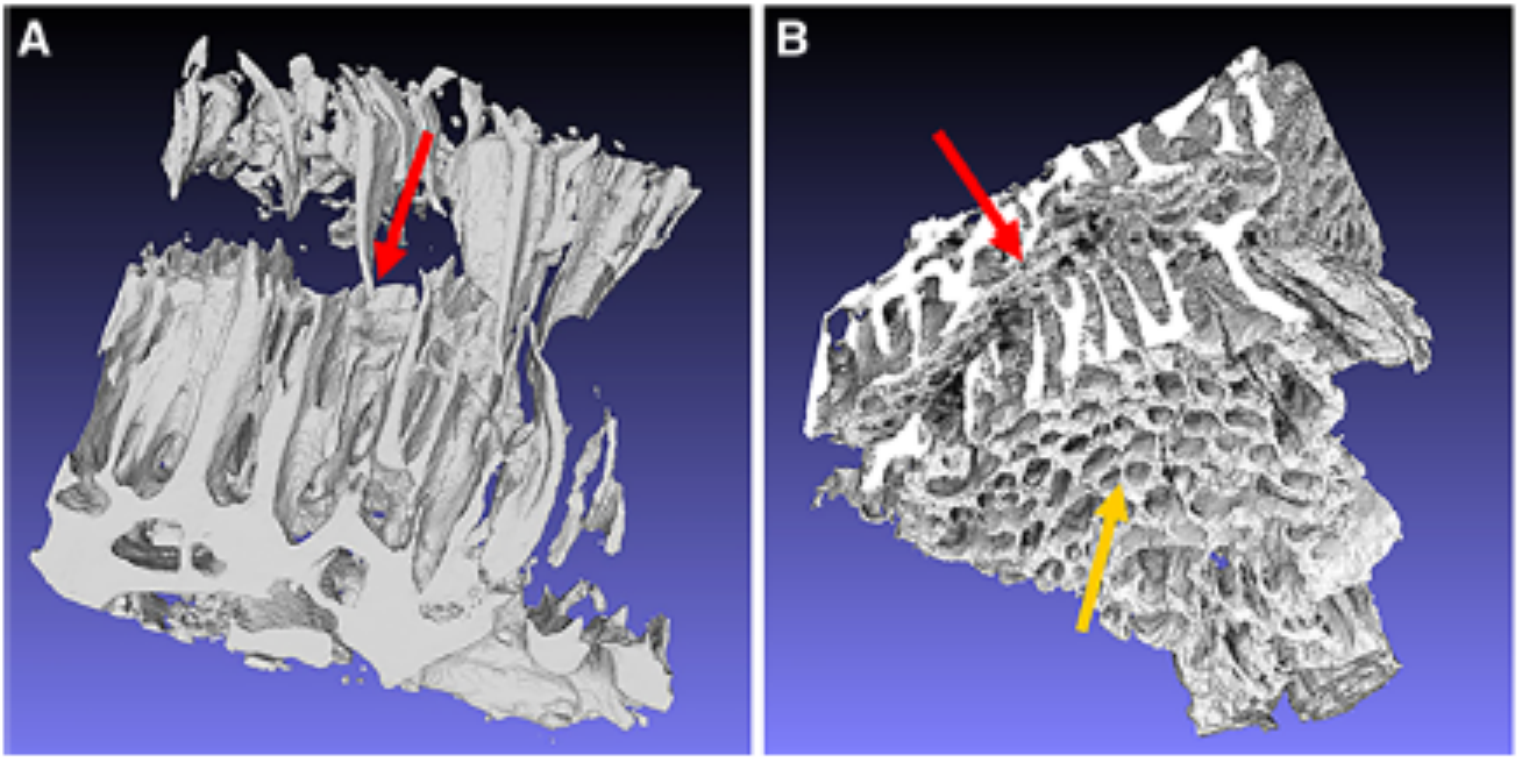

Figure 17. *3D microCT rendering of the biopsies retrieved 7 days (a) and 30 days (b) after the RME. Both the specimens clearly showed the meshwork of the bone perforated by non-mineralized spaces. The direction indicated by the red arrows corresponded to the section plane of histological and SEM micrographs. The right image offers a better view of the canals (yellow arrows) that cross the whole thickness of the bone to reach the sutural channel.*

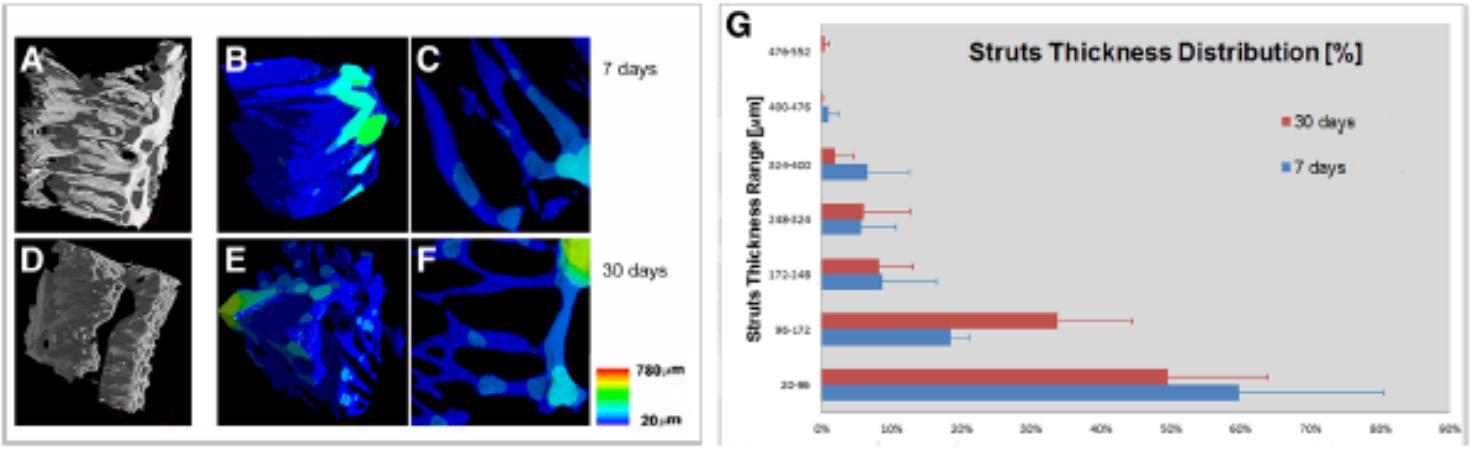

***Figure 18**, **a-c** Biopsy retrieved 7 days after RME: (**a**) 3D microCT reconstruction; (**b**) Study in 3D of the thickness distribution basing on a color map; (**c**) 2D sampling color mapped slice. d-f Biopsy retrieved 30 days after RME: (**d**) 3D microCT reconstruction; (**e**) Study in 3D of the thickness distribution basing on a color map; (**f**) 2D sampling color mapped slice. Thickness scale for the color map at the bottom-center position. (**g**)Histogram of the distribution of the newly formed bone thickness in both the RME-treated midpalatal biopsies. These data demonstrate that there was a slight (not significant; $p > 0.05$) increase in thickness of the struts from 7 days to 30 days after RME.*

Further case reports should be focused on the investigation in different timepoints in order to better clarify when the bone healing process might end and give important guidelines on retention and relapse.

Side Effects

Secondary effects of RME relate to the heavy forces produced by the RME appliance which could produce bite opening, microtrauma of the midpalatal suture and temporo-mandibular joint structure and root resorption among others (Lagravere et al., 2005). Periodontal involvement is the most commonly cited side effect of RME due to the possibility of damaging the buccal cortical plates and developing gingival recessions when high forces are

directed towards the banded teeth. A retrospective study analyzing the periodontal effect of RME in 17 growing patients demonstrated that immediately after the expansion the first maxillary molar buccal plate thickness is reduced by 0.5 mm. However, at 6 months post expansion, only the lingual bone plate thickness of both first molars was significantly increased with no differences in the ratio between intermolar widths at the apex and crown levels (Ballanti et al., 2009). In a CBCT study evaluating the buccal alveolar bone changes 3 months after the end RME activation with Hyrax appliance, it was found that the buccal bone thickness decreased 1.1 mm and 1.2 mm for the 1st premolars and 1st molars respectively while the buccal marginal bone level decreased by 4.5 mm and 2.9 mm respectively. This study suggested that the buccal movement of teeth may potentiate the probability of buccal bone dehiscence at the maxillary 1st premolar due to the increased buccal marginal bone loss associated with apical narrowing at this level (Rungcharassaeng et al., 2007). Although periodontal consequences may be present after RME, available literature demonstrate that buccal bone thickness returns to normal level and no periodontal concern should be raised if the patient had an initially normal buccal bone thickness.

The present Author recently reported original findings *(accepted in March 2018, publishing in January 2019)* on periotontal effects of RME with different appliances. Dislocation of teeth outside their alveolar process, in fact, can damage the periodontium and for this reason maxillary expansion using deciduous teeth as anchorage in mixed dentition might be suggested. The aim of the reported study was to compare changes of buccal bone plate thickness on upper first permanent molars after rapid maxillary expansion performed in mixed and permanent dentition with different anchorage. Two groups of patients were evaluated with CBCT before (T0) and after (T1) rapid maxillary expansion. Group E (21 patients) underwent rapid maxillary expansion using deciduous teeth as anchorage, Group 6 (16 patients)

underwent rapid maxillary expansion using permanent teeth as anchorage. According to the results RME performed in mixed dentition with the appliance anchored to deciduous teeth did not reduce the buccal bone plate thickness of the upper first permanent molars, except for the mesial roots on both sides. Meanwhile, RME performed in permanent dentition produced a reduction of the buccal bone plate thickness of upper first permanent molars when they act as anchor teeth. The range of reduction of the buccal bone thickness of upper first permanent molars when they act as anchor teeth showed statistically significant differences when compared to the overall absence of bone reduction when RME is performed in mixed dentition. Nevertheless the bone loss (ranging between 0.73 mm and 1.25 mm) is not clinically significant. Important consideration should then be given to other factors that might play a relevant clinical role. Soft tissue, in fact, might cover the bone defect created as fenestration, more frequently in maxillary alveolar ridge, or dehiscence. The occurrence of a recession in these cases was suggested to be strictly related to gingival inflammation. The first clinical recommendation should be to avoid using permanent molars as anchor teeth when deciduous teeth are suitable.. For this reason timing plays a fundamental role in terms of avoiding postponing maxillary expansion in permanent dentition but preferring as a valid alternative a two-phase treatment. For older patients presenting at the orthodontic examination when deciduous teeth are no longer suitable, a careful evaluation of the gingival biotype should be performed before positioning bands of the appliance on the upper first molar. In some cases also accompanied by radiographic investigation involving CBCT when the clinical investigation is doubtful. Then a follow-up during the expansion with the clinical examination through touching the roots at the appointments and a rigid oral hygiene regime should be mandatory. Another option when a large amount of expansion is needed in growing patients with a thin gingival biotype might be bone anchored maxillary expansion.

RME therapy appears to involve an ample portion of the craniofacial complex, as the maxilla is associated with 10 bones in the face and head (Bell et al., 1981). This involvement has been hypothesized following investigations based on histologic methods, radiologic imaging, photoelastic models, bone scintigraphy, and finite element analysis.

Findings from Leonardi et al. (Leonardi et al., 2011) showed that circum-maxillary sutures articulating directly to the maxilla were opened more extensively than those indirectly articulated. In fact, the distant structures of the craniofacial skeleton (zygomatic bone and temporal bone) were also affected by transverse orthopedic forces, although to a lesser extent. All in all, an increased width in circumaxillary sutures, with the highest amount of opening at the internasal suture (0.386 mm) and the lower at the zygomaticotemporal suture (0.213 mm) was observed. Results indicated that the amount of widening after RME therapy is different among sutures and highly variable among subjects.

Treatment Timing

Like all craniofacial sutures, the mid palatal suture becomes more tortuous and interdigitated with increasing age. In children up to ten years of age, almost any expansion device will tend to separate the mid palatal suture. However, by adolescence a relatively heavy force from a rigid jackscrew is needed to separate the interdigitated suture (Proffit 2007). In this context, Baccetti et al. evaluated patients with different stages of cervical vertebrae maturation index and found that the early treated individuals who had not reached the pubertal growth spurt at the onset of RME showed on average 3mm of expansion of the mid-palatal suture while the late treated ones averaged only 0.9mm. His finding suggested that an effective long-term change at the skeletal level occurs when the patients were treated prior to pubertal peak growth and higher dental effect is present in individuals treated after pubertal growth spurt

(Baccetti et al., 2001).

Distant Skeletal Effects

Finite element analysis (FEA) is defined as a computer simulation method performed by dividing the interested region into discrete elements interconnected at nodes with assigned material property that represents the physical property of the model. A FEA study evaluating the effects of the maxillary expansion on the neighboring bones demonstrated that in the closed suture model (adult type suture) significant stress areas were present at the buccal alveolar processes, distal aspect of the maxilla, inferior aspect of the zygomatic arches and pterygomaxillary fissure region (Lee et al., 2009). Thus, areas surrounding the zygomatic processes were suggested to provide a buttressing effect against the forces of expansion. In the patent midpalatal suture model (growing child) however, the pterygomaxillary fissure demonstrated to be the highest stress point. This finding confirmed the impact of maxillary expansion in facilitating the treatment effects of a class III facemask therapy in growing individual (Lee et al. 2009). In the same patent suture model, tension stress was also present at the upper portion of the nasal cavity suggesting that the palatal expansion with heavy forces in young children may create undesireable changes in the nose (Lee et al., 2009, Proffit, 2007). For both groups, the lateral displacement of the maxillary halves appeared nonparallel, with a slightly wider opening towards the anterior and the separation of the maxilla occurring as if a hinge was positioned superiorly at the base of the nose (Lee et al., 2009). Clinical studies evaluating the effects of orthopedic expansion via RME postulated that not only bodily separation of the midpalatal suture exists, but also buccal rotational force on the maxillary alveolar shelves and changes to the surrounding frontomaxillary, zygomaticomaxillary,

zygomaticotemporal and pterygopalatine sutures (Garrett et al., 2008).

Skeletal Dimension and Airway

RME has been reported to be effective also for the upper airway increase due to the direct force exerted on the nasal area in young individuals (Caprioglio et al., 2014) with breathing pattern problems.

Breathing pattern and cranio-facial growth

The effect of type of breathing on craniofacial growth has been widely debated as a controversial issue within orthodontics for decades. It has been maintained that when significantly large adenoids are present, nasal breathing is (partially) obstructed leading to mouth breathing and thus the stereotype of the adenoid face (Subtelny, 1954; Linder-Aronson, 1970). However, the complexity of the association between nasal obstruction and facial growth has also been discussed (McNamara, 1981; Warren and Spalding, 1991; Trotman et al., 1997; Vig, 1998). The adenoid face is characterized by an incompetent lip seal, a narrow upper dental arch, retroclined mandibular incisors, increased anterior face height, a steep mandibular plane angle, and retrognathic mandible compared with faces of healthy controls (Linder-Aronson, 1970; Flores-Mir, 2013). Comparable changes in the craniofacial structure have been described in a group of subjects with large tonsils (Behlfelt et al, 1990). This development has been explained in a 'mechanical' way as occurring because of changes in the muscular balance. When mouth breathing, the tongue position in the oral cavity is low and the balance between forces from the cheeks and tongue is different compared with healthy children. This may lead to a lower mandibular position and an upward/backward head posture

with all the above-mentioned dental and skeletal consequences (Solow and Kreiborg, 1977; Linder-Aronson, 1979; Solow et al, 1984).

Role of hormones on cranio-facial growth

After adenoidectomy to facilitate nasal breathing, accelerated mandibular growth and closure of the mandibular plane angle have been reported, although with a large variation (Linder-Aronson et al, 1986). In a more detailed analysis, anterior facial height was found to be unaffected and remained longer in the initially large adenoid subjects than in healthy controls 5 years after adenoidectomy. In the same study, growth of the mandibular ramus and condylar process of adenoidectomy patients was found to be greater than that in the control subjects (Kerr et al, 1989). The changes found have been previously explained by alteration in tongue position and autorotation of the mandible (Linder-Aronson, 1979). However, in order to decrease the mandibular plane angle, more growth in posterior face height/ramus height is needed.

Endochondral bone formation in the condylar cartilage and bone apposition in the lower border of the mandible (gonial region) contribute to the growth in height of the mandibular ramus. Studies on mandibular condylar cartilage have shown that the cartilage not only is a passive growth site, but also has some tissue-separating potential (Copray et al, 1988). It has also been maintained it to be active in displacing the condylar process downwards (Kantomaa, 1987). In addition, the mandibular condylar cartilage seems to be a target and production site of hormonal agents as evidenced by IGF-I receptor and IGF-I messenger RNA expression in the cartilage (Visnapuu et al, 2001, 2002). Patients with GH (GH) deficiency have been shown

to have a small posterior face height compared with age and gender-matched healthy controls (Pirinen et al, 1994). Furthermore, administration of GH to patients with GH deficiency, such as those with Turner syndrome or in bone marrow transplant patients, has shown that mandibular growth, particularly the ramus growth, is accelerated in those cases compared with control healthy children (Simmons, 1999). The increase in mandibular ramus height by GH can be explained by two theories. One is the presence of an increased endochondral bone formation in the condylar cartilage (Peltomäki T, 2007) and the other is the presence of an increased bone apposition in the lower border of the mandible through the anabolic effects of GH on the masseter and medial pterygoid muscles (Vogl et al, 1993).

Maxillary Constriction and Obstructive Sleep Apnea

Obstructive sleep apnea (OSA) is characterized by episodes of complete or partial upper airway obstruction during sleep, often resulting in gas exchange abnormalities and arousals, which disrupt sleep. The condition exists in 2 to 5 percent of children and can occur at any age (Rosen et al., 2004). Untreated OSA is associated with cardiovascular complications, impaired growth (including failure to thrive), learning problems, and behavioral problems. Early diagnosis and treatment may decrease morbidity. Potential consequences of untreated OSA in children include:

- Inattention and behavioral problems (eg, hyperactivity, impulsivity, rebelliousness and aggression).
- Daytime sleepiness.
- Growth – Severe OSA can be associated with failure to thrive, and treatment can lead to weight gain and growth.
- Cardiovascular disease – Cardiovascular consequences may include systemic

hypertension, right and left ventricular dysfunction.

Each of these conditions may benefit from treatment of OSA, though in some cases definitive proof at the level of randomized clinical trials does not yet exist. The initial screening for OSA is typically done by the primary care clinician. Children with suspected OSA should be referred to a specialist in sleep medicine or otolaryngology (ear, nose, and throat). Alternatively, the referring provider may be able to arrange for a polysomnogram (PSG) if a facility with experience in pediatric PSG is available. Then children with abnormal results of PSG, or with other significant sleep problems, can then be referred to the appropriate specialist. OSA is typically defined by clinically relevant symptoms and an apnea hypopnea index (AHI) >1 or hypoventilation (CO_2 >50 mmHg for >25 percent total sleep time) as determined on PSG. The decision to initiate treatment and choice of treatment depend upon the child's age, presence of any underlying medical issues, risk factors, clinical symptoms (such as nighttime sleep problems or daytime dysfunction), and results of PSG if performed, as outlined below:

Adenotonsillectomy – Referral to a specialist for adenotonsillectomy evaluation is generally indicated for otherwise healthy children who have OSA and adenotonsillar hypertrophy (including ≥1+ tonsils) (Marcus et al., 2012). After the full evaluation, the decision about whether to proceed to surgery should be made collaboratively with the family, considering in particular the degree of clinical symptoms (nocturnal and daytime), as well as the tonsil size and OSA severity. Adenotonsillectomy also may be initial therapy for children with other contributors to OSA such as obesity or other comorbidities, if appreciable adenotonsillar tissue is present, even if there is no clear hypertrophy. The rationale is that adenotonsillectomy may improve upper airway patency enough to ameliorate or resolve the OSA, even if it does not correct all of the etiologies. Such patients should be managed by a clinician experienced with

pediatric sleep-related respiratory abnormalities;

Watchful waiting – For otherwise healthy children with mild or moderate OSA confirmed by PSG (AHI >1 and <10), watchful waiting with supportive care is a reasonable alternative to adenotonsillectomy. This approach is based on the acceptable outcomes for patients followed with watchful waiting in the Childhood Adenotonsillectomy Trial (CHAT) trial (Marcus et al., 2013). If this approach is chosen, the child should be reevaluated clinically within six months, or reevaluated sooner if symptoms worsen;

Positive airway pressure therapy – For patients with minimal adenotonsillar tissue or a strong preference for a nonsurgical approach, positive airway pressure therapy is an alternative to adenotonsillectomy. It also may be appropriate to stabilize children with severe OSA prior to adenotonsillectomy or another surgical procedure, or for children with persistent OSA despite adenotonsillectomy. Positive airway pressure may consist of continuous positive airway pressure (CPAP) or bilevel positive airway pressure (BPAP).

The following treatments can be considered in selected cases, either instead of or as an adjunct to the primary therapy:

Rapid maxillary expansion – Prepubertal children with OSA and a narrow palate (crossbite) and little adenotonsillar tissue are candidates for treatment with rapid maxillary expansion (RME). RME is an orthodontic technique that widens the palate and nasal passages, thereby increasing airway patency. Such patients should be managed by an orthodontist experienced with pediatric sleep-related respiratory abnormalities;

Corticosteroids or antiinflammatory therapy – For children with mild or moderate OSA and nasal obstruction due to adenoidal hypertrophy, a trial of intranasal corticosteroids or leukotriene modifier therapy may be performed for two to four weeks, prior to determining whether the therapy should be continued long-term as an adjunct or alternative to

adenotonsillectomy or positive airway pressure.

Other therapies – Selected children with OSA may derive benefit from adjunctive therapies. As examples, obese children with OSA may benefit from weight loss, and all children may benefit from avoidance of environmental allergens or irritants such as tobacco smoke. In addition, positional therapy (eg, elevation of the head of the bed) can be considered.

Maxillary constriction has also been postulated to play a role in the pathophysiology of OSA. Despite the reference of multiple contributing factors for the development of OSA including retrognathic mandible, shorter AP face length, reduced distance from the posterior nasal spine (PNS) to posterior pharyngeal wall, lower positioned hyoid bone, larger soft palate, smaller pharynx, larger tongue size, obesity and combination thereof (Johal et al., 2007), a constricted maxilla has also been associated with narrowing the upper airway dimension and increasing the risk for OSA by inducing a low tongue posture (Subtelny, 1954). Sleep apnea is defined as a decrease in respiration yielding hypoxia and hypercapnia during sleep, caused by either neurologic origin or actual physical blockage of the airway also known as OSA. Subjects with centrally driven apneic event present no effort to overcome the apnea, whereas the opposite is true for the OSA sufferers. The American Academy of Sleep Medicine defines OSA as episodes of breathing cessation or absence of respiratory airflow for over 10 seconds despite respiratory effort. Epidemiology reports indicate that this is a highly prevalent respiratory sleep disorder affecting 4% of men and 2% of women (Haskell et al., 2009). The most serious consequences of OSA are the cardiovascular diseases such as hypertension, tachycardia, atherosclerosis, increased risk for cerebrovascular accidents, coronary artery disease and more (Madani et al., 2007). The pathogenesis of these effects is still being studied but it is generally accepted that the intermittent hypoxia and hypercapnia episodes triggers homeostatic

compensations in the body, leading to cardiovascular diseases over time (Sharabi et al., 2004). It is believed that the sleep induced relaxation of the muscles attached to the soft tissues of the pharynx is aggravated by gravity and the retropositioning of the tongue mass during supine position narrowing the airway lumen (McCrillis et al., 2009). Treatment of OSA consists in preventing the collapse of the lumen of the pharynx during sleep. At present, several treatment options based on the severity of the apneic events are rendered, including continuous positive airway pressure (CPAP) therapy, surgical treatments and mandibular repositioning devices therapy. Oral appliances have been reported to improve breathing by decreasing nasal resistance and reducing the AHI. For breathing to take place, patency of the pharynx or upper airway is vital. With the exception of the two ends of the airway, the nares and the small intrapulmonary airways, the pharynx is the only collapsible segment of the respiratory tract with the potential to be altered by diverse treatment effects (Haskell et al., 2009).

According to Lenza et al. the upper airway can be divided into smaller segments to better understand the physiologic changes as well as the treatment effects (Lenza et al. 2010). The various portions of the upper airway, superiorly to inferiorly include:

- Nasopharynx: The upper most portion of the airway, mainly the nose. It begins with the nares extending back to the hard palate at the superior portion of the soft palate. This includes the nasal septum and the nasal turbinates.
- Retropalatal airway (velopharynx): This area extends from the hard palate to the inferior tip of the soft palate, including the uvula and the uppermost segment of the posterior pharyngeal wall. Major muscles include the tensor palatini and levator palatini, which elevate the soft palate, and the musculous uvulae providing elevation of the uvula.
- Retroglossal airway (oropharynx): This area includes the oral cavity, beginning with

the back portion of the mouth and extending rearward to the base of the tongue or tip of the epiglottis. Tonsils and tongue muscles are located in this segment.

- Hypopharynx: The area extends from the tip of the epiglottis to the lowest portion of the airway at the larynx.

In all individuals, muscular activity is reduced and upper airway resistance increased during sleep compared when awake (Worsnop et al, 2000). This does not have a notable effect on breathing in anatomically and functionally healthy individuals. On the other hand, reduction of muscular tone in children with large adenoids and tonsils, or with other underlying abnormal upper airway anatomy, may lead to airway obstruction and eventually to OSA. Interestingly, these children have been found to have similar craniofacial characteristics as adenoid face children (Caprioglio et al., 1999). The first treatment of choice for OSA children is removal of adenoids and tonsils, if they are indeed hypertrophic (Nieminen et al., 2002). It can thus be postulated that some children with a clinical diagnosis of an adenoid face may also have OSA. Of particular interest is the recent cephalometric study on 5-year-old children with OSA verified with PSG (Zettergren-Wijk et al., 2006). This study showed that OSA children have a different facial morphology compared with age-matched controls. The mandibular plane angle was found to be posteriorly inclined, anterior face height to be greater, and posterior face height smaller than control children. At the 5-year follow-up after T&A, no major craniofacial differences were noted. In a closer look at the growth changes it becomes evident that anterior face height remained greater in the OSA children than in the control children (difference of average 2.5 mm), but presented an average increase in both groups of children. Yet, the mandibular plane angle was decreased in the OSA children. This may be explained by the described greater posterior face height growth (ramus growth) in the OSA children compared

to controls (difference of average 2 mm). After T&A, OSA patients showed increase of the nasal breathing pattern and modifications of GH serum levels were noted with growth catch-up.

OSA, breathing function and body growth

Along with breathing issues, body growth retardation is frequently observed in OSA patients. The complex mechanisms behind growth retardation are still unclear. OSA might interrupt slow-wave sleep, when GH is preferentially secreted and this phenomenon was observed also in chronic snorers not diagnosed for OSA. GH modifications were often related to serum levels of IGF-1 and IGFBP-3 which are related to diurnal GH secretion and reflect its anabolic role on tissues, especially muscle and bone. IGF-1 resulted significantly increased in children after T&A surgery in previous studies thus suggesting a relevant role of the IGF-1 axis in growth retardation of children with upper airway obstruction and the consequent growth catch-up (Bar et al., 1999; Nieminen et al., 2002).

The present Author performed a systematic review *(under review)* on metabolic effects of treatment in patients with OSA which aimed to systematically review the available scientific literature on the relationships among OSA patients, GH axis and other metabolic changes and growth alterations before and after T&A treatment. Several studies investigated relationships among OSA patients, GH axis metabolic changes and/or growth alterations before and after OSA treatment but some results are still contradictory indicating that complex and multiple mechanisms might be involved. To date only one systematic review and meta-analysis was performed on growth and growth biomarker changes after T&A in sleep-disordered breathing (SDB) patients. The following study updated the literature and selected different inclusion criteria. Moreover this is the first study presenting the attempt to review the available literature

regarding metabolic mediators changes such as endothelial and neurocognitive function mediators and local inflammation mediators.

Growth mediators

- IGF-I

GH was shown to stimulate the synthesis of IGF-I in the liver and other target tissues (Tapanainen et al. 1992). IGF-I is considered as the main mediator of the growth-promoting actions of GH (Isaksson et al., 1987) reflecting the daily mean GH levels, and it has been reported to correlate well with the physiologic changes in GH secretion (Furlanetto, 1990). Among pre-pubertal children, IGF-I was reported to be clearly not sex-dependent (Juul et al., 1994). IGF-I showed significant higher levels in OSA patients 1 month, 3, 6 and 9 months after T&A (Bar et al., 1999) but no significant differences right after surgery (Nachalon et al., 2014). Nachalon et al. (2014) were the only authors who evaluated growth mediators immediately after T&A finding no significant differences in IGF-I levels, suggesting that this mediator might need at least 1 month to reach significantly higher concentrations (Kang et al., 2008). Moreover all the other selected studies investigated older patients samples in pre-pubertal age, meanwhile Nachalon et al. (2014) referred to children aged 6-36 months. The evidence of other selected articles suggested that T&A might influence the GH-IGF-I axis by increasing IGF-I levels, leading to acceleration of growth in SDB patients and the results were pretty homogeneous. Nevertheless some limitations were present in the study of Tatlıpınar et al. (2012) since only clinical history based diagnosis of SBD was performed. All the studies were performed at pre-pubertal age thus reducing bias due to the pubertal spurt which might cause itself an increase of growth mediators. When compared to control groups, OSA patients showed significant lower levels of IGF-I at baseline (Selimoğlu et al., 2003) even though

contradictory results were found by Nieminen et al. (2014), and the significant difference was also maintained after T&A regardless of the significant improvement among the time points according to Zhang et al. (2015) This latter study investigated twins, using one affected by OSA as treated and the other not affected by OSA as control. According to their results OSA might affect growth manners and early surgical intervention could only partially reverse the growth inhibit. In these cases early intervention might be highly recommended.

- *IGFBP-3*

IGFBP-3, the GH-dependent major carrier protein of IGF-I, was shown to correlate significantly with nocturnal GH secretion, but not as strongly as IGF-I (Blum et al., 1993). Although IGFBP-3 probably exerts some functions of its own on cells, its major role seems to be the prolongation of the half-life of IGF-1 (O'Brien et al., 2006). The major advantage of IGFBP-3 determinations in diagnostics is its relative stability over time (Blum et al., 1993), and it might therefore be a more reliable indicator of GH secretion over a longer time interval than IGF-I. It is also less dependent on age than IGF-I (Rosenfeld et al.,1999). IGFBP-3 showed significantly higher levels in OSA patients 6 and 9 months after T&A according to the results of Tatlıpınar et al. (2012). On the contrary, Bar et al. (1999) and Selimoğlu et al. (2003) found no significant changes after T&A.

The reported dissociation between IGF-I and IGFBP-3 levels might express the complexity of the IGF-I and the IGF-binding protein systems, which are controlled by several positive and negative feedback pathways, rather than one simple pathway. The increase in IGF-I levels without a corresponding change in IGFBP-3 levels may indicate an elevation of the free IGF-I levels, because IGFBP-3 is the major binding protein in the circulation according to both authors (Bar et a., 1999; Tapanainen et al., 1992). Only Nieminen et al. (2012) and Selimoğlu

et al. (2003) compared IGFBP-3 levels between OSA patients and controls. OSA patients showed significant lower levels IGFBP-3 at baseline and significant higher levels 6 months after T&A according to the results found by Nieminen et al. (2012) meanwhile no significant differences were found by Selimoğlu et al. (2003). Moreover, according to Selimoğlu et al. the increase in IGFBP-3 concentration after T&A in the study of Nieminen et al. might imply decreased GH secretion over a significant time span prior to treatment.

Growth alterations in OSA patients were also focused on craniofacial anomalies and it still not clear if they might derive more from alteration of the breathing function or if they are directly influenced by the GH axis anomalies.

Endothelial mediators

OSA was suggested as an important and independent risk factor for altered endothelial function and cardiovascular disease (Sánchez-de-la-Torre et al., 2013). The involved mechanisms are not still completely understood and they seem related to the increase in circulating adhesion molecules in children with OSA (O'Brien et al., 2006). Moreover, OSA presents sleep fragmentation that might cause systemic inflammation and sympathetic activation thus leading to endothelial dysfunction, which has been shown to precede the formation of plaque and atherosclerosis (Jelic et al., 2008). sCD40L is a binding protein on the surface of endothelial cells and triggers the increased expression of inflammatory mediators, growth factors, and the procoagulant tissue factor such that increased levels of sCD40L essentially represent the presence of an increased risk in the context of a variety of cardiovascular disorders. Gozal et al. (2007) found significantly higher levels of sCD40L in OSA patients when compared to a control group. Even though sCD40L showed significant decrease after T&A, their levels were still significantly higher than controls 4-6 months after

T&A. Because the duration of follow-up was relatively short, it is still unclear as to whether these children with persistently abnormal hyperemic responses and elevated sCD40L will improve at later stages. Moreover FMD was employed by Chan et al. (2015) in OSA patients compared with nonsnoring control subjects. This parameter was shown to be independent from reactive hyperemia thus representing a more precise means to assess endothelial function. According to their results OSA patients showed reduced FMD, which was reversible with surgical treatment indicating reversal of endothelial dysfunction following surgical intervention.

Neurocognitive function and mediators

OSA children showed specific cognitive dysfunctions that include deficits in memory, problem solving and behavioral functioning (Beebe et al., 2002). BDNF is an important member of the neurotrophin family, abundant in the brain and periphery that induces long-term changes in synaptic composition, ion channel expression and neurotransmitter production in the neuronal structures of the brain. Reduced BDNF levels in the human brain are associated with cognitive deficits, impaired memory performance and depression (Chen et al., 2001). According to the results of Wang et al. (2010) BDNF serum levels significantly decreased 3, 6 and 12 months after T&A in OSA patients. The authors suggested that concomitant decrease in serum and plasma BDNF might indicate that it was specifically removed from peripheral blood maybe due to increased demand following the improvement of sleep parameters. The nervous system might then be able to recover after T&A, and so the demand for BDNF would increase, potentially resulting in the reduction of circulating BDNF levels.

Local inflammation

Anti-inflammatory agents are often employed in treatment of upper airway diseases and glucocorticoids were suggested to inhibit inflammation by up-regulation of T-regulatory (T-reg) cells and the secretion of interleukin (IL)–10 by these cells (Esteitie et al., 2011). According to the results of Esteitie et al. (2011) pretreatment with FFNS compared with no treatment resulted in inhibition of Interleukin (IL)-6 secretion by adenoid cells without affecting other cytokine levels significantly. This result might partially explain the mechanism by which intranasal corticosteroid therapy provides relief for children with OSA, and it is emphasized by the prospective and randomized design followed by the authors to divide the experimental group and the control group before T&A. The selected inclusion criteria allowed the present systematic review to include twelve studies since only in vivo studies were selected and limited cases studies and case reports were excluded. Some of the initially selected articles were excluded since they did not present treatment outcomes or clear pre- and post- treatment data on clinical treatments. However the methodologies of the selected studies were varied thus a meta-analysis was not possible. Also, these studies failed to give the higher level of scientific evidence, which is only attainable through the use of randomized clinical trials except for Esteitie et al. (2011) who indicated randomization process in patients enrollment. In the absence of the highest level of evidence, clinicians have to make decisions based on lower levels of evidence.

Maxillary expansion and breathing pattern: where are we now?

Author's contributions:

Fastuca R. Maxillary expansion and breathing function: Where we are now?. Int J Orthod Rehabil 2016;7:121-3.

Fastuca R, Perinetti G, Zecca PA, Nucera R, Caprioglio A. Airway compartments volume and oxygen saturation changes after rapid maxillary expansion: a longitudinal correlation study. Angle Orthod. 2015 Nov;85(6):955-61.

Fastuca R, Lorusso P, Lagravère MO, Michelotti A, Portelli M, Zecca PA, D' Antò V, Militi A, Nucera R, Caprioglio A. Digital evaluation of nasal changes induced by rapid maxillary expansion with different anchorage and appliance design. BMC Oral Health. 2017 Jul 14;17(1):113.

Fastuca R, Zecca PA, Caprioglio A. Role of mandibular displacement and airway size in improving breathing after rapid maxillary expansion. Prog Orthod. 2014 Apr 29;15(1):40.

According to the anatomical proximity between nasal cavity and hard palate, an orthopedic expansion of the former might occur as consequence of the RME treatment. This hypothesis has initially been investigated decades ago. In particular, earlier studies (Wertz, 1968; 1970) evaluated the advantages of RME treatment in improving nasal airflow in patients with nasal stenosis. It was later suggested that RME treatment triggers effects on nasal width (Brown, 1903) and volume (Zhao et al., 2010). Indeed, some studies (Hershey et al., 1976) showed a reduction in nasal airway resistance after RME treatment. Consistently, an investigation (Warren et al., 1987) reported up to 45% increase in nasal cross-sectional areas after

expansion. In spite of this evidence, considering the V-shaped opening pattern of the midpalatal suture (Wertz, 1968; 1970), the only purpose of increasing respiratory performance has been reported as not sufficient to indicate an RME treatment (Warren et al., 1987).

More in detail, airway changes upon RME treatment have been studied using different methodologies including acoustic rhinometry (Doruk et al., 2007), two-dimensional (Wertz, 1968; 1970), and three-dimensional (3D) (Montgomery et al., 1979) cephalometrics. One of the most used morphological techniques nowadays is represented by the 3D cone-beam computed tomography (CBCT) that allows a full 3D and reliable quantification of anatomical changes even for the airway compartments. Other functional diagnostic tools that can be employed to investigate the effects of RME on airflow include the PSG examination. This recording widely employed in OSA patients (Villa et al., 2011) gives useful information about breathing pattern, and showing quantitative data such as oxygen saturation (SpO_2) and AHI. Indeed, a morphological modification of the airway spaces does not necessarily implies a greater respiratory performance (i.e., function) or *vice versa*, and studies including only the anatomical investigations of the RME treatment on airway compartments volume might be limited in their conclusions. Several previous studies (Görgülü et al., 2011; Ribeiro et al., 2012; Smith et al., 2012) evaluated airway volume changes after RME treatment dividing airway in different compartments to better describe effects at different levels. Indeed, an important distinction should be performed between anatomical skeletal changes and airway changes. The former modifications, in fact, might be of different amounts according to the amount of expansion that is related to maxillary transverse discrepancy and are influenced by the resistance of the sutures around maxillary bones (Leonardi et al., 2011). According to a recent study using CBCT (Cordasco et al., 2012), RME produces significant skeletal

transverse augmentations in the palatal and nasal regions. These increments are bigger in the lower portion of the nasal cavities. Moreover, RME is able to increase significantly skeletal nasal cavity volume. The volume increase is equally distributed between the anterior and the posterior part of the nasal cavity. Greater increases in width were observed in the nasal floor region rather than in the middle nasal width region, thus supporting the reverse "V" shape opening model of the craniofacial complex (Wertz, 1970). On the contrary, airway changes are related to more complex variables and indeed to the breathing pattern of the patient. Unfortunately, skeletal widening of the nasal cavity does not necessarily imply a proportional improvement of the airway since airway obstruction causes might be not related to skeletal anatomical reasons. The airway might be divided in upper (from the nostrils to posterior nasal spine), middle (from posterior nasal spine to the basis of the tongue), and lower compartment (from the basis of the tongue to epiglottis) and in every portion, different mechanisms responsible for improvement or worsening of breathing might take place. In a recent study (Caprioglio et al., 2014) airway was examined as upper, middle, and lower compartments and as a whole. According to their results, only nasal cavity had a significant increase in volume after RME treatment. These findings are explained by the close anatomical proximity of the upper airway compartment, i.e., nasal cavity, with the hard palate subjected to orthopedic expansion. Similar results were reported previously (Görgülü et al., 2011; Ribeiro et al., 2012; Smith et al., 2012). In particular, Smith et al. (2012) divided the airway volume in nasal cavity, nasopharynx, and oropharynx showing a significant increase in the nasopharynx volume after RME treatment. The apparent inconsistency between those results and the present evidence may be related to the different separations or combination of the nasopharynx and oropharynx followed. This multiplicity of results could be related to the presence or absence of adenoid tissue in nasopharynx before treatment. Chang et al. (2013)

reported bony expansion and significant cross-sectional area increase immediately posterior to the hard palate after RME treatment and suggested that effects on the upper airway would be local, and it diminishes farther from the maxillary suture, possibly as a result of soft-tissue adaptation.

Iwasaki et al. (2012) used CBCT and computational fluid dynamics to estimate the effects of RME on nasal airflow function (pressure and velocity). In the most of the examined patients, the pressure and velocity of nasal ventilation after RME resulted significantly lower than before treatment indicating an improvement in nasal breathing (Iwasaki et al., 2012). The study by Zhao et al. (2010) is the only one that included an untreated control group and saw no significant changes between treated and controls in airway volumes after RME treatment. Moreover, more complex mechanisms are involved in respiratory function changes after RME. Iwasaki et al. (2013) recently compared changes of the tongue posture with changes in the nasal airway ventilation pattern after RME treatment. According to their findings, children with nasal airway obstruction have a low tongue posture regardless of RME treatment meanwhile improvement of the nasal airway ventilation condition might be associated with improved low tongue posture after RME. Even though encouraging results were recently arisen, especially with the means of new 3D technologies, long-term follow-up needs to be investigated.

Matsumoto et al. (2010) investigated long-term effects of RME on nasal cavity using acoustic rhinometry, computed rhinomanometry, and posteroanterior cephalometric radiography demonstrating an increase in nasal osseous width with less significant increases in nasal area and nasal resistance and suggested that the effects of RME could be more evident at the bony level (Cordasco et al., 2012) than at the mucosal level and this might be due to compensatory

hypertrophy of the nasal mucosa after expansion. A recent review concluded that the stability of the results can be expected for at least 11 months after the orthopedic therapy (Baratieri et al., 2011). Further randomized and blinded controlled studies are needed to strengthen the evidence of the long-term RME effects on airway dimensions and functions.

The present Author contributed to scientific literature with several publications in the past few years. Three of these articles will be treated more in detail to better elaborate on the topic and the aims of the present thesis.

One of these reports (Fastuca et al., 2015) is the first study demonstrating a significant correlation between baseline middle and lower airway volumes (Fig. 19-20) and SpO_2 changes obtained as a consequence of RME in subjects having posterior crossbite. The multiple backward logistic regressions showed that the more the subjects presented a reduced nasal volume in the middle and lower compartments of the airway, the more they would benefit from RME in terms of improved SpO_2, with the middle compartment being better correlated than the lower compartment.

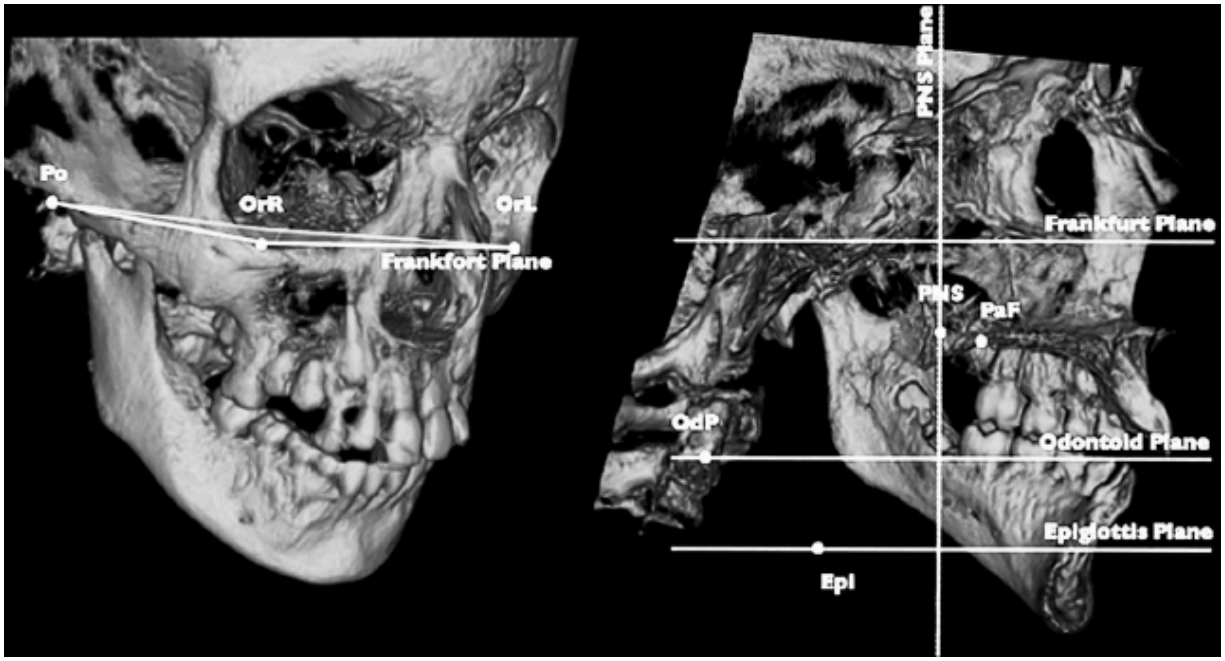

Figure 19. *3D landmarks and plans used for airway identification and segmentation*

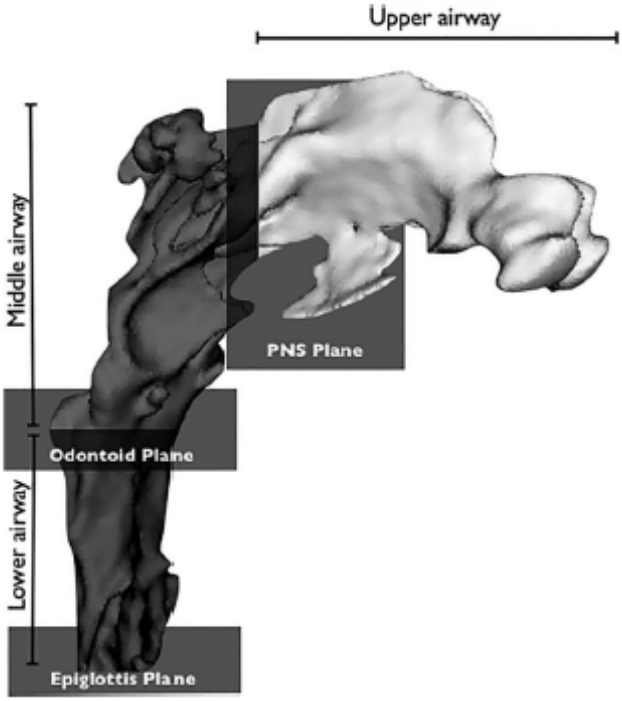

Figure 20. *Airway compartments. Upper airway from nares to PNS plane; middle airway from PNS Plane to odontoid plane; lower airway from odontoid plane to epiglottis plane.*

Interestingly, the combination of baseline middle and lower airway volumes explained up to 75.7% of the overall SpO_2 changes after treatment. This result might suggest the importance of not only nasal obstruction, as shown by other authors (Iwasaki et al., 2013), but also the contingent stenosis of the middle and lower pharynx wherein tonsil and adenoid hypertrophy might play an important role in reducing the airway lumen. The regressions model showed no association of the baseline airway compartments with sex, age, or AHI variations. Evaluating AHI as a secondary outcome, we found in the sample group an improvement in the index with a reduction in apneic events of 4.2 per hour. These findings support those stating that RME is effective in improving respiratory function. There is some evidence in the literature showing that RME improves respiratory function in OSA patients, thus reducing the AHI (Villa et al., 2011). The tested sample had value of 5.8 +/-1.1 events/ hour for AHI at baseline, which might be considered slightly higher than physiological standards. Diagnosis of OSA was excluded during the subjects' enrollment since none of the subjects presented any of the symptoms or signs to indicate a positive diagnosis of PSG (Marcus et al., 2012). RME treatment might positively affect nasal function by enlarging the hard and the soft nasal airway tissues. It is known that RME produces a functional improvement of the breathing pattern in patients with nasal obstruction or stenosis (Iwasaki et al., 2013). Previous studies (Görgülü et al., 2011; Ribeiro et al., 2012; Smith et al., 2012) divided the airway into various compartments evaluating volume before and after RME to better clarify the effects of treatment. Several authors (Smith et al., 2012; Chang et al., 2013) have reported a significant enlargement of the nasal cavity and nasopharynx, in agreement with the present results, but no significant increase in the other investigated airway compartments, such as the oropharynx and hypopharynx, suggesting that effects on the upper airway were local as a result of soft tissue

adaptation farther from the midpalatal suture (Chang et al., 2013). Nevertheless, differences in compartmental segmentation were noticeable between the present method and the above-mentioned studies, which might explain the different outcomes. Indeed, according to the present results, not only the upper and nasal airways but also the middle and lower airway compartments underwent significant volume increases.

Such increases were greater for the upper compartment, ie, the nasal cavity, and slightly lower for the middle and lower compartments. Nasal cavities expansion after RME was then examined more in detail by the Author of the present thesis in two other publications (Fastuca et al., 2014; 2017). In the most recent one (Fastuca et al., 2017) the purpose was to evaluate the response of nasal cavities to three different types of expander, anchored to the permanent or deciduous teeth. No authors compared the impact of RME appliances anchored to deciduous teeth with traditional RME appliances anchored to permanent teeth in determining nasal changes.

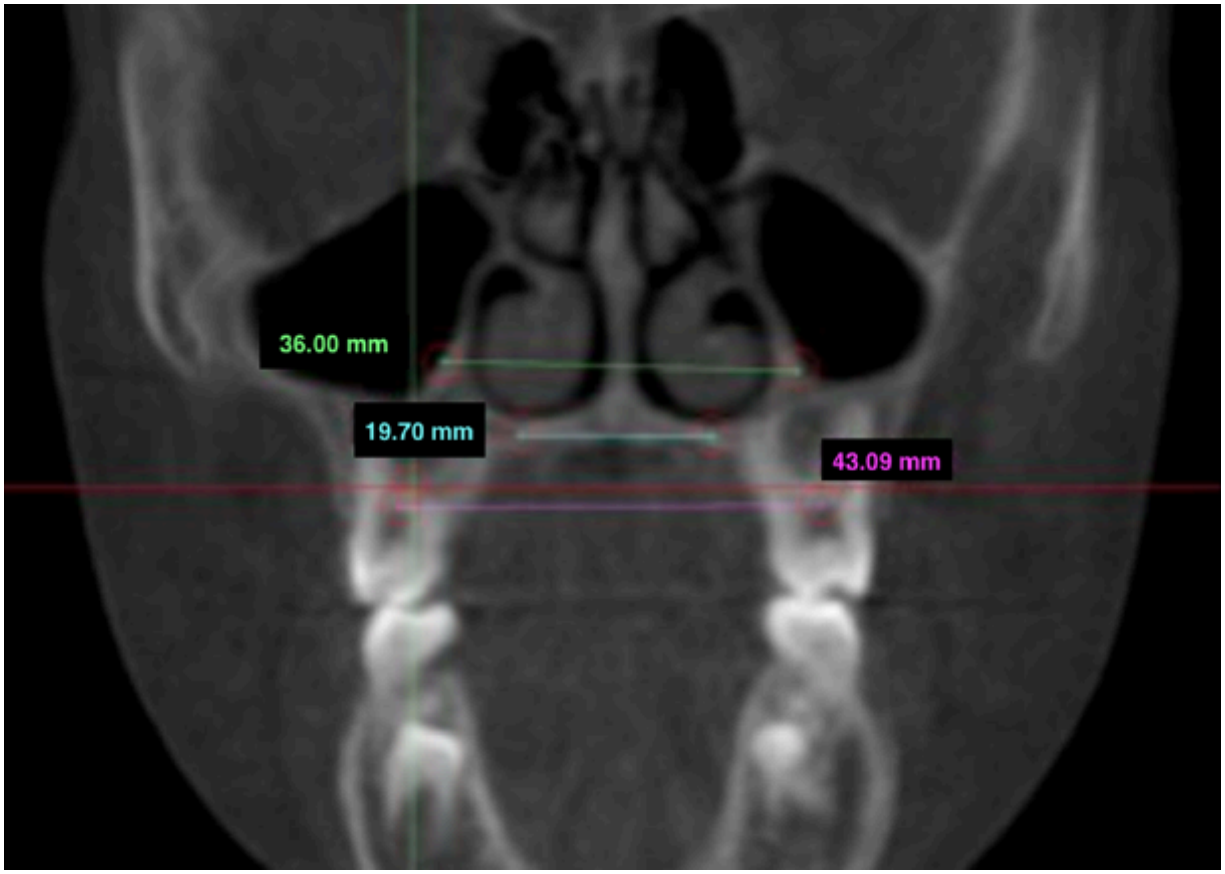

Figure 21. *Linear transverse measurements performed to measure nasal diameters before and after RME.*

In this investigation no statistically significant differences of the variables understudy (Fig. 21) were found when RME appliance was anchored on deciduous or permanent teeth. It allows speculating that RME by using deciduous anchorage is effective, as much as traditional RME, into obtaining an increase of nasal size (Caprioglio et al., 2014; Fastuca et al., 2015). This positive impact on nasal cavity could be included in the list of the benefits previously reported by literature for this kind of anchorage, such as the lack of sequelae on permanent teeth (Garib et al., 2014) and the better and more stable expansion of the anterior area of maxilla with the improvement of the anterior alignment (Ugolini et al., 2015). In the current study the differences of the nasal size increments obtained by using the modified Hyrax-type

appliance (HX-E group) (Fig. 22) and the modified Haas-type appliance (HS-E group) (Fig. 23), both anchored to deciduous teeth, were no statistically significant.

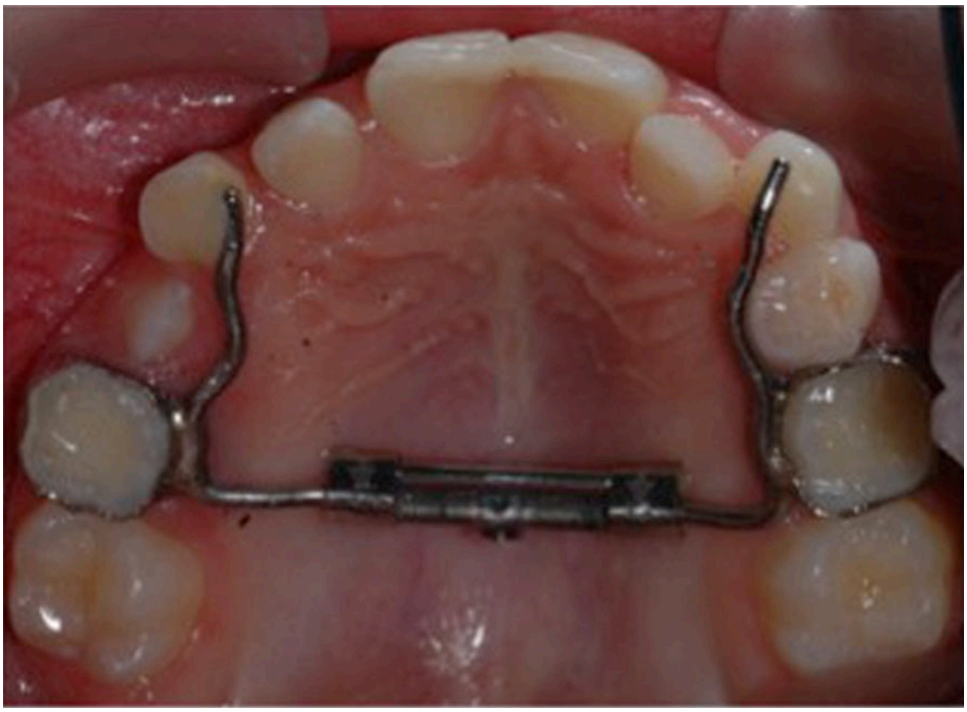

Figure 22. *Modified Hyrax-type expander anchored to deciduous teeth.*

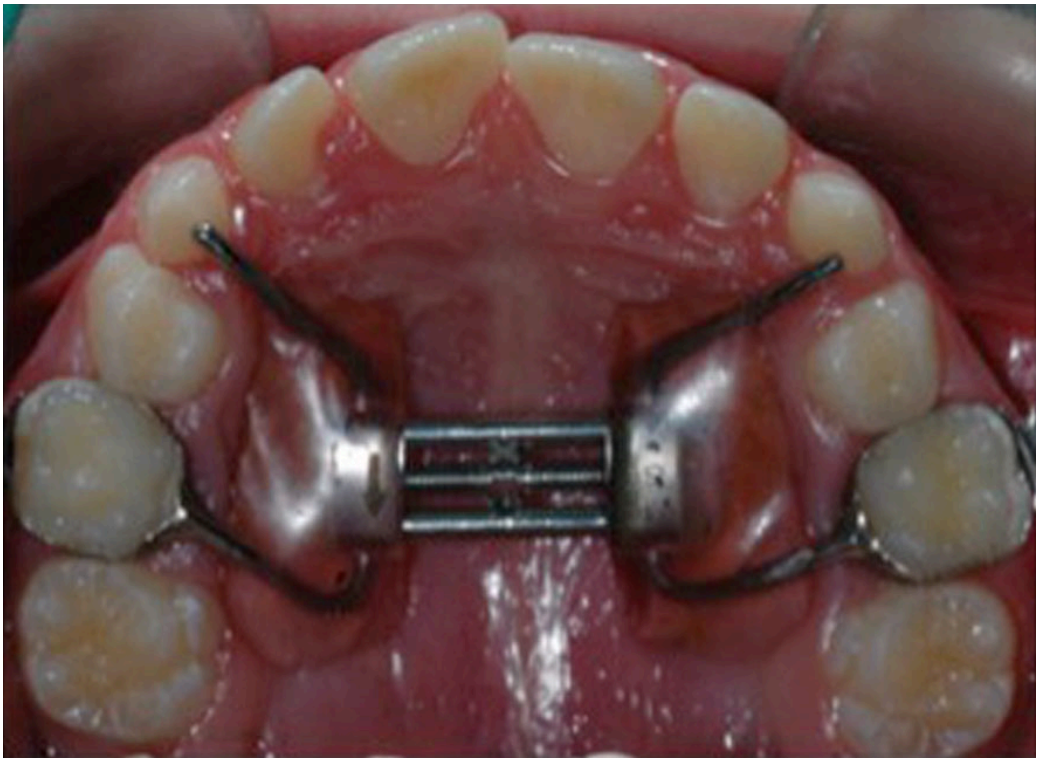

Figure 23. *Modified Haas-type expander anchored to deciduous teeth.*

This outcome is consistent with the findings by Garib et al. (2014) that compared toothborne with tooth-tissue-borne expanders anchored to permanent teeth. Significant values of expansion were observed in all groups by studying both nasal floor width and nasal wall width. The increase of nasal floor width is comparable with that of previous studies (Caprioglio et al., 2017). An amount of expansion of 2.8 mm, close to the results of the current research, was recorded by Izuka et al. (2015) in a CBCT study. Other authors, even finding significant enlargement of the nasal floor, did not achieve similar values of expansion (Zeng et al., 2013); the different amount of expansion applied on the patients should be taken into account to explain these discrepancies. Anyway the mentioned authors used permanent teeth as anchorage. The amount of expansion of nasal wall of the current paper is also comparable

with previous studies (Zeng et al., 2013). The mean increase of nasal wall width after RME was found to be lower than the mean increase of nasal floor width. This data would seem to support the reverse 'V' shape opening model of the cranio-facial complex on the coronal view (Wertz, 1970). RME in early mixed dentition by using deciduous teeth as anchorage represents an effective treatment option for growing patients showing maxillary constriction, with potential benefits for nasal skeletal expansion. Anyway further researches would be needed to give information on the above mentioned functional consequences as well as on the long-term stability of the airway changes produced by RME on deciduous teeth. In fact significant expansion of nasal cavity shape does not assure an improvement of the breathing function which would need to be evaluated with different quantitative methods such as acoustic rhinometry.

Repositioning of the tongue (due to dental changes) (Ugolini et al., 2014) and the mandible (as a result of the clinical procedure) (Fastuca et al., 2014) might occur as consequences of RME and might influence or be influenced by the changes in the breathing pattern. The present Author investigated the role of mandibular displacement (Fig. 24) and airway size in improving breathing after RME in a recent publication. The objective of this study was to use CBCT to investigate whether changes in oropharyngeal volume and mandibular displacement significantly influenced the breathing pattern improvement shown by PSG recordings in growing patients after RME treatment.

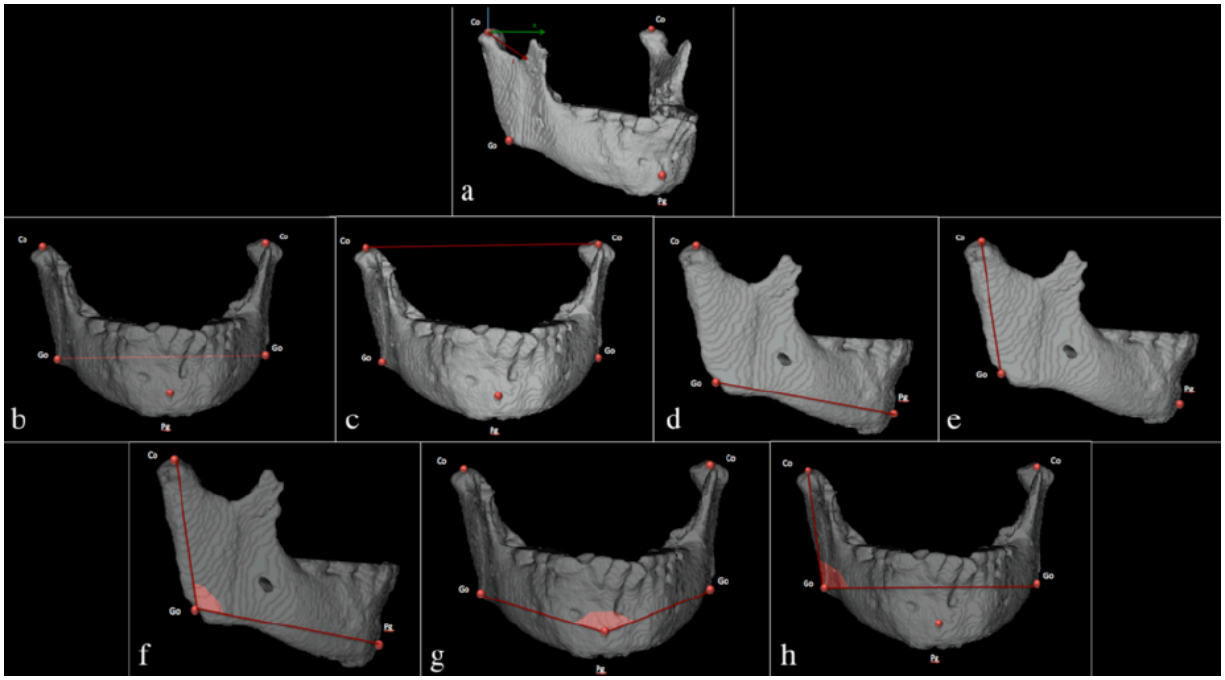

Figure 24. *Cephalometric analysis to evaluate mandibular displacements.*

According to the results, all the patients of the sample underwent an improvement of their breathing pattern according to the PSG examinations. SpO_2 increased, meanwhile AHI decreased at T1 suggesting functional improvement in the breathing pattern because of the enhancement of the oxygen saturation and reduction of the apnea/hypopnea events. Similar results were reported by other studies (Villa et al., 2011) which investigated breathing performances in patients after RME using PSG examination in OSA patients and found significant improvements in AHI that remained stable after 24 months after treatment. However, even though breathing improvement was recorded in the present study sample, no significant difference was found in oropharyngeal volume changes neither significant mandibular displacements. The functional breathing improvement did not seem related to hypothesize mandible repositioning and oropharyngeal volume enlargement. Previous studies

investigated airway changes after RME analyzing different airway compartments or the whole volume (Görgülü et al., 2011; Ribeiro et al., 2012; Smith et al., 2012; El and Palomo, 2014). El and Palomo (2014) performed a morphological evaluation of airway volumes comparing RME-treated patients to a control group finding significant increases in nasal volumes. Nevertheless, neither oropharyngeal volume nor mandibular displacements underwent to significant changes after RME treatment according to their results. Zhao et al. (2010) included an untreated control group and found no significant changes between treated and controls in retropalatal and retroglossal airways after RME treatment. The results of this investigation are in agreement with the previously reported studies, and they suggest that the reasons of breathing improvement after RME in the investigated sample might not lie in oropharyngeal volume changes but rather should be researched in other compartments of airway such for example nasal cavity. According to other authors [29], the effect of RME on the upper airway might diminish farther down the airway and separating from the maxillary suture where the appliance forces are mainly exerted. A recent study (Caprioglio et al., 2014) confirmed that nasal cavity volumes seem to be significantly influenced by RME unlike other compartments of airway. Furthermore, the improvements of respiratory performances seem to be interestingly related more to the upper airway than to oropharyngeal airway in OSA patients who underwent maxilla-mandibular advancement within maxillofacial surgery (Ronchi et al., 2013). Moreover, more complex mechanisms are involved in respiratory function changes after RME. Iwasaki et al. (2013) recently compared changes of tongue posture with changes in the nasal airway ventilation pattern after RME treatment. According to their findings, children with nasal airway obstruction have a low tongue posture regardless of RME treatment meanwhile improvement of the nasal airway ventilation condition might be associated with improved low tongue posture after RME. The measurement of the volumes of airway

compartments may be biased by several factors such as head and tongue position during CBCT scan acquisition, breathing, swallowing movements, and repositioning of the tongue and the mandible after treatment (McNamara et al., 2010). Therefore, the reliability and repeatability of the CBCT recording of airway compartment has been questioned. Several studies suggested mandible reposition after RME in Class II patients (Guest et al., 2010; Baratieri et al., 2011). The sample of the present study did not include Class II patients but only Class I with positional posterior crossbite. The sample characteristics might have biased the present investigation considering that no forward repositioning of the mandible might occur in this study as it was shown in Class II patients. Nevertheless, mandibular shift might occur thus reducing the positional crossbite after RME. Previous studies (Leonardi et al., 2012) suggested small amount of changes in condylar position in patients presenting functional posterior crossbite and undergone RME.

AIM

No evidence has been found on metabolic or hormonal changes involving GH after RME. Since breathing pattern improvement was showed after treatment in some patients undergoing RME, the hypothesis of associated changes in GH levels or its mediators might be worth investigating along with the changes in breathing pattern as showed in OSA patients after T&A. The present study is original since similar investigations were never been performed earlier. Some implications should be analyzed.

Some consideration on PSG exam should be performed. PSG should consist on a take home device which patients should use the first day and return it to the doctor the following day. The data collected by the device should be analyzed by a specialized pediatrician. Blood samples should be collected and results should also be interpreted by a specialized pediatrician. In this interval time, treatment group subjects should undergo RME and control group should undergo no treatment. PSG exam would allow to exclude OSA patients.

The aim of the present randomized clinical trial (RCT) was therefore to determine changes in AHI, SpO_2 and serum levels of IGF-1 in growing patients treated with RME.

METHODS

The protocol for the present randomized clinical trial was reviewed and approved by the Ethical Committee of the University of Messina (Approval no. 103/16 dated 10/125/2016) and of the University of Alberta, Edmonton, CA (dated 12/05/2015) and the followed procedures adhered to the World Medical Organization Declaration of Helsinki.

The initial sample was selected according the following inclusion criteria: i) good general health according to medical history and clinical examination; ii) maxillary transverse discrepancy (skeletal discrepancy) with or without unilateral posterior crossbite; iii) age between 7 and 10 years old (this age range was chosen to prevent bias in terms of pubertal peak growth since at this age it is assumed males and females have not had it yet); iv) body mass index (BMI) normal (not below the 25th percentile and not above the 75th percentile) according to age; v) 0< AHI ≤5 (normal to mild OSA). Exclusion criteria were: i) craniofacial syndrome or anomalies; ii) noticeable asymmetries; iii) other orthodontic treatment; iv) skeletal Class III (ANB<0°); v) AHI >5 (moderate to severe OSA. All the subjects presenting at the Department of Orthodontics of University of Messina (Messina, Italy) and University of Alberta (Edmonton, Canada) seeking for orthodontic treatment and who met the inclusion and exclusion criteria were consecutively enrolled in the study between March 2016 and May 2017.

The signed informed consent for releasing diagnostic records for scientific purposes was obtained from the both the patients and their parents prior to be enrolled for the present study.

Sample Size Calculation

Sample size was calculated considering as primary outcome the amount of changes in AHI index. A clinically relevant change of 0.4 events/hour with a combined standard deviation (SD) of 1.8 events/hour derived from a pilot study performed on 3 patients per group was established. To retrieve β=0.80 with α set at 0.05 a sample of at least 16 patients per group was needed. 10% dropout of patients should be considered, then a greater number of patients was enrolled for a total number of 18 patients per group.

Randomization Procedure

An allocation sequence was generated using an electronic computer program. Every new patient presenting and adherent to the inclusion and exclusion criteria was allocated to treatment group or control group (using www.random.org). Then, the allocation information (randomization results) was consulted by the statistician every time a new patient was enrolled. The treating clinician was blinded from the randomization procedure but blinding was not possible during the treatment period for clear conditions of control patients who did not have any appliance. The trained operator who performed the PSG examinations and blood samples was blinded to the group assignment since all the records were performed without appliances. The study was blinded in regard to the statistical analysis: blinding was obtained by eliminating from the elaboration file every reference to patient group assignment. A consort diagram showing the flow of patients through the trial is provided in Fig. 25.

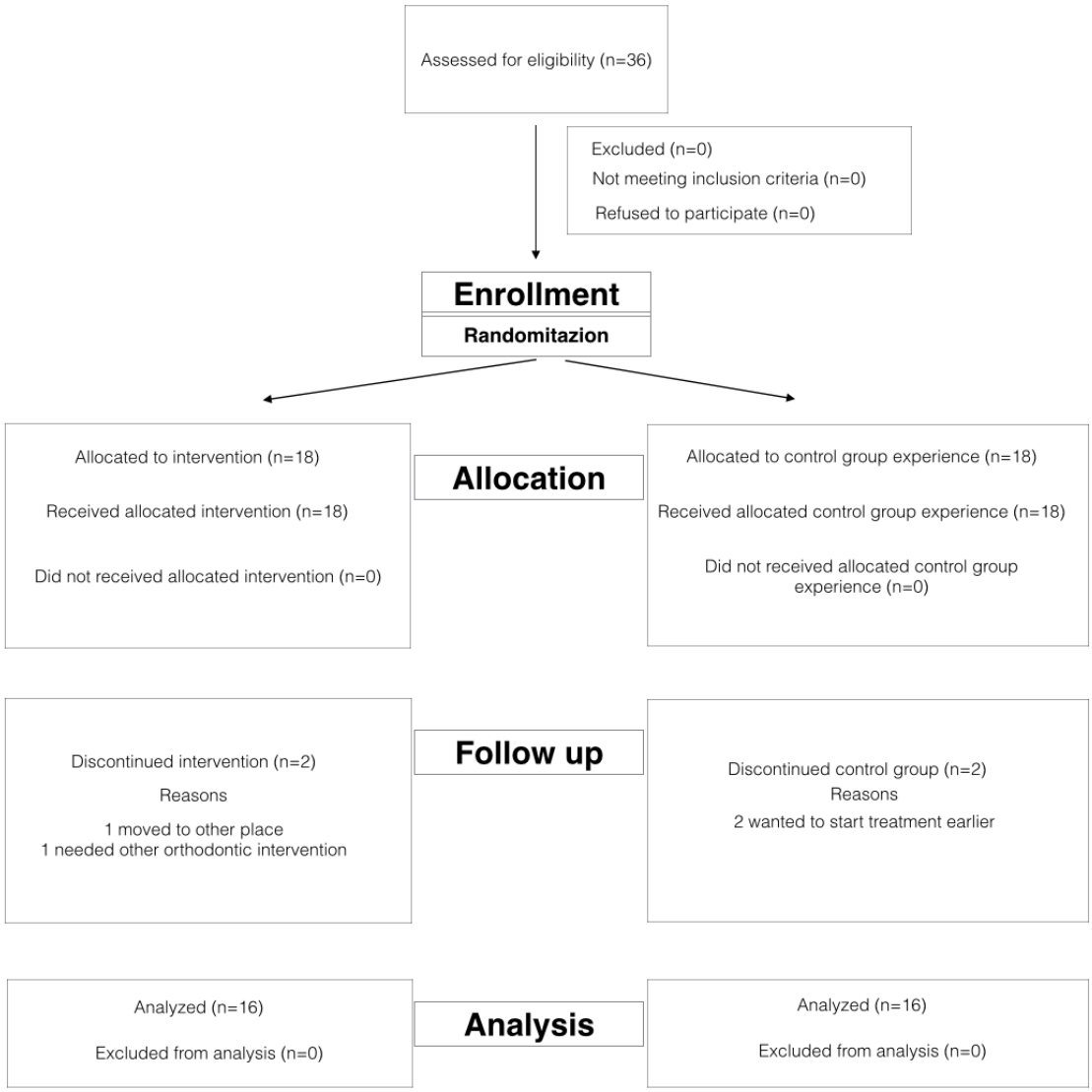

Figure 25. *Flow diagram of patients' enrollment.*

Treated group comprised 16 patients (10 males and 6 females) with a mean age of 9.50±1.39 years and control group comprised 16 patients (11 males and 5 females) with a mean age of 9.9±0.92 years (Table 1).

	Treated Group (n=16)		Control Group (n=16)	
	Mean	***SD***	***Mean***	***SD***
Age (years)	9.50	1.39	9.96	0.92
BMI	35.95	29.83	39.00	34.04
SpO_2 (%)	95.81	1.59	96.42	0.52
AHI (events/hour)	3.09	1.29	2.44	1.89
IGF-1 (ng/mol)	195.64	62.74	175.60	64.38

Table 1. Starting forms of the treated group and control group. *Data are shown as Mean and SD.*

Intervention

All patients of the treated group underwent maxillary expansion with Hyrax-type expander with a 10-mm screw (A167-1439, Forestadent, Pforzheim, Germany) banded to the upper second deciduous molars or upper first permanent molars (Fig. 26). The choice of performing RME on deciduous molars, when possible, needs some clarifications. When maxillary expansion is needed, with or without a crossbite, maxillary first molars might tilt buccally to compensate for the skeletal discrepancy (Rosa et al., 2016). If expansion is performed on permanent molars in this case, the buccal inclination worsens, since it was reported to increase by about 3° to 4° toward the buccal side. On the contrary, if RME is performed on deciduous teeth without a palatal wire extension, the permanent first molars are free to correct their axes toward the palatal side due to occlusal forces, thus allowing for greater skeletal expansion and avoiding the risk of scissorsbite of the maxillary molars.

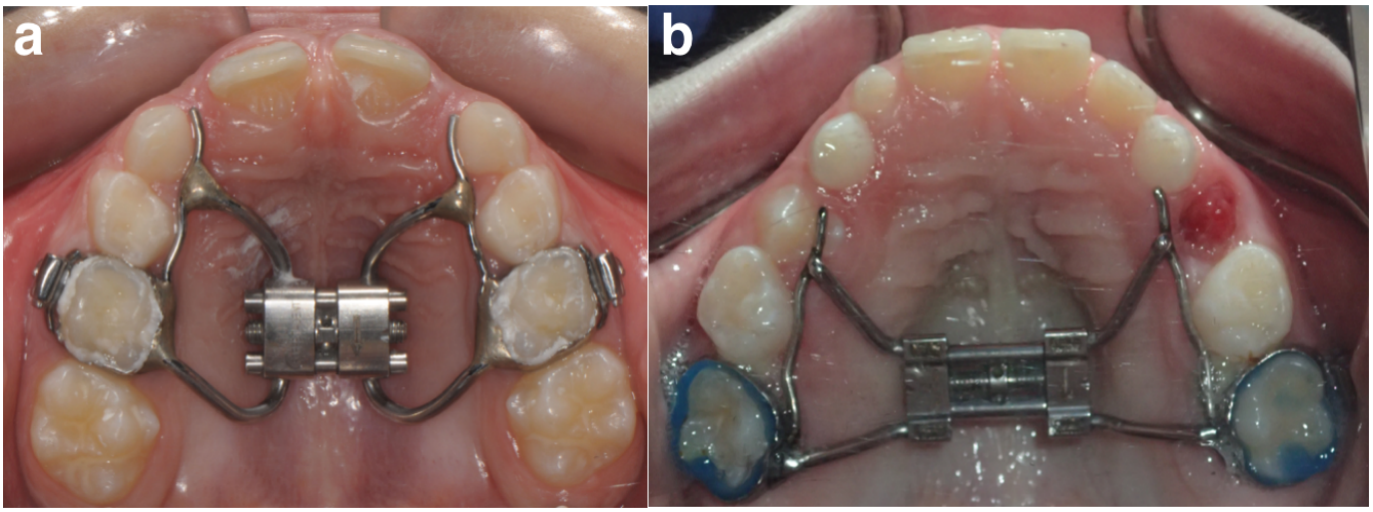

Figure 26. *Hyrax-type expander banded to the upper second deciduous molars (a) or upper first permanent molars (b).*

The screw of the palatal expander was initially turned twice (0.45 mm initial transversal activation). Afterwards, parents of the patients were instructed to turn the screw once per each following day (0.225 mm activation per day). Maxillary expansion was performed until dental overcorrection. After the expansion was completed, the appliance was kept in the mouth passively for the following 6 months. Subjects in the control group underwent not treatment. Postponing treatment for control group would not change the efficacy of treatment in this group since RME might be easily performed until midpalatal suture maturation at the pubertal growth spurt, which was long ways for the control group.

PSG exam (Embletta - EMBLA, Thornton, CO, U.S.A.) and blood samples for the evaluation of serum levels IGF-1 were collected at T1 and after 12 months (T2).

Outcomes (primary and secondary)

The primary outcomes measure for this trial were the changes in AHI and IGF-1 after RME compared with untreated control group. Secondary outcomes included overall changes in SpO_2 following RME treatment.

Statistical Analysis

The SPSS software, version 22.0 (SPSS® Inc., Chicago, Illinois, USA) was employed to perform the statistical analysis. Shapiro-Wilk test revealed normal distribution of the data. Gender differences were investigated within the same group showing no gender differences. Each group was then analyzed as whole without any gender stratification. Means and SDs were calculated for both groups at T1 (Table 1). No starting forms comparisons were computed at T1 since the patients enrollment followed the established inclusion and exclusion criteria. SpO_2, AHI and IGF-1 changes in the treated group were compared with those that occurred in the control group using Student t-test (Table 2).

RESULTS

For the treated group the mean active expansion period was 1.7± 0.6 months with mean activation of the expansion screw of 6.35 ± 1.25 mm. Overall treatment time lasted 7.2 ± 0.5 months. The mean interval between the timepoints was 12.1±0.5 months for the treated group and 11.2±0.3 months for the control group.

The main differences between groups (Table 2) were reported in AHI and IGF-1. AHI significantly decreased of -1.82 events/hour in the treated group compared to the control. IGF-1 also showed significant increase of 20.68 ng/mol in the treated group compared to control group. No significant differences were reported for SpO_2 indicating no significant changes in oxygen saturation.

	Treated Group (n=16)		**Control Group (n=16)**		
	Mean	***SD***	***Mean***	***SD***	***P***
SpO_2 (%)	0.13	2.50	-0.44	0.43	0.62
AHI (events/hour)	-1.82	0.53	0.32	0.41	0.01*
IGF-1 (ng/mol)	20.68	18.54	2.20	3.03	0.04*

Table 2. Comparisons of the mean differences (T2-T1) between treated group and control group. *Data are shown as Mean and SD. Student t-test was used in order to compare differences between groups and underline which effects are due to treatment or growth. * P<0.05.*

DISCUSSION

The present RCT aimed to evaluate changes in breathing pattern and growth mediators in patients undergone RME compared to control patients undergone no treatment. No negative effects were reported for postponing RME treatment since it might be performed with the same effects until the growth peak, then no ethical implications were indicated of postponing treatment in control group. Several previous studies until recent days (Villa et al., 2011; Fastuca et al., 2015) focused on breathing function and maxillary expansion reporting different results. Furthermore, the positive effects of RME on patients' general health were underlined in terms of increasing nasopharyngeal airway dimensions, leading to improved nasal breathing (McNamara et al., 2015). The present results showed a significant improvement in AHI indicating a decrease of -1.82 events/hour in the treated group compared to control suggesting nasal breathing was at least partially restored after RME. In the present RCT children with normal breathing or mild OSA (0<AHI<5) were included showing transverse maxillary deficiency, as shown by the mean of AHI of both groups at the starting forms (Table 1). The exclusion of moderate and severe OSA patients was performed since in these latter cases surgical treatment might be indicated and an improvement due only to RME treatment might not be detected for the gravity of the original OSA which might need surgical treatment (Guilleminault et al., 2011). Furthermore normal BMI was used among inclusion criteria for the relevant implications of increased BMI on worsening of breathing conditions during night-time. With increased BMI, in fact, a greater amount of fat tissue might lay down the airway then worsening anatomical obstruction with consequences on OSA and general health (Natsios et al. 2016). Previous studies evaluated breathing function in OSA patients using PSG examination finding an overall improvement of AHI and SpO_2. Fastuca et al. (2015) evaluated

changes of respiratory pattern after RME finding an improvement with a reduction in apneic events of 4.2 per hour. Villa et al. (2011) investigated effects of orthodontic treatment with RME in growing OSA patients finding reduced symptoms of OSA and improved polysomnographic variables with an AHI decrease of 3.9 events/hour. Pirelli et al. (2004) performed a long-term follow up of AHI after RME and Guilleminault et al. (2011) compared orthodontic and surgical treatment in different combination suggesting that no significant differences were between the group beginning with orthodontic treatment and the one beginning with surgical treatment after the first intervention. Differently from the present RCT, the previous cited reports (Pirelli et al., 2004; Guilleminault et al., 2011; Fastuca et al., 2015) included patients suffering from moderate to severe OSA and showed larger decrease in AHI if compared to the present results. SpO_2 was the other breathing parameter derived from PSG investigated in the present RCT and did not show significant differences between groups. Even though AHI significantly decreased in the treated group the changes in SpO_2 were not significant. From a clinically point of view changes in AHI, even though statistically significant, probably were not as large to detect a significant improvement in SpO_2, which, on the contrary, showed significant improvement in previous reports along with larger improvements in AHI in patients that presented more severe OSA at baseline if compared to the present sample.

The main original finding of the present RCT was related to the measurement of IGF-1 and its significant increase after RME. To the best of our knowledge no evidence was previously reported on metabolic or hormonal changes involving GH mediators or general growth in patients treated by RME. IGF-I represents primary mediator of the effects of GH and covers relevant roles in growth and development of the whole body during childhood and adulthood. Especially, when measuring GH level two important considerations might be performed:

1. ***Exclusion of patients in the pubertal growth spurt.*** Rose et al. (1991) showed how GH levels increase significantly during pubertal growth spurt. According to their results the increase in mean levels was earlier in girls than boys, was most evident at night, and was due to increased pulse amplitude rather than a change in pulse frequency. The mean nighttime GH level in girls with bone ages (BA) greater than 12 to 14 yr were significantly greater than the mean level in girls with BA less than 8 yr (7.3 ± 3.0 vs. 3.4 ± 1.7 μg/L; $P < 0.01$) and were greatest at breast stage 3 (7.9 ± 2.5 μg/L). GH pulse amplitude increased significantly before pubertal onset in girls and was significantly greater at BA greater than 12 to 14 yr than at BA of 8 yr or less (13.9 ± 6.0 vs. 7.9 ± 4.8 μg/L; $P < 0.01$) and greatest at breast stage 3 (15.0 ± 6.3 μg/L).

The pubertal increase in GH secretion was delayed in boys compared to girls, with the lowest mean 24-h GH and mean nighttime GH values in boys with BA greater than 8 to 11 yr. The mean nighttime GH level at BA greater than 11 to 13 yr in boys was significantly greater than that in the boys with BA greater than 8 to 11 yr (5.8 ± 2.9 vs. 3.5 ±2.1 μg/L; $P < 0.05$) and was greatest at a testicular volume of more than 10 to 15 mL (6.5 ± 2.0 μg/L). The mean nighttime GH pulse amplitude in boys was significantly greater at BA greater than 11 to 13 yr than at BA greater than 8 to 11 yr (13.9 ± 5.1 vs. 7.3 + 2.6 μg/L, $P < 0.05$) and was greatest at a testicular volume greater than 20 mL(15.8 ± 12.0 μg/L).

The evaluation of the GH level should then follow these guidelines but also bone age with hand and wrist radiography will be evaluated since it is considered the most certain method to identify the pubertal growth spurt. The combination of both information might allow to exclude significant changes in GH levels due to pubertal growth spurt and not to treatment;

2. ***Evaluation of significant changes in GH levels.*** The changes in GH levels that the patients might show at the two timepoints should be first compared to control group of the

same age and this should allow the evaluation of significant cut off levels. Moreover GH levels at T1 and T2 should be compared to normal GH values at the same age and should be considered significant if higher than 2 standard deviations from normal increases for age and sex.

Due to the previous considerations only IGF-1 was elected instead of GH to be investigated in the present RCT.

IGF-1 showed significantly higher levels in OSA patients 1 month, 3, 6 and 9 months after T&A (Gümüssoy et al., 2009) but no significant differences right after surgery (Nachalon et al., 2014). When compared to control groups, OSA patients showed significant lower levels of IGF-I at baseline (Zhang et al., 2015) and the significant difference was maintained. All the previous investigations were performed in younger patients and only with surgical treatment (Nachalon et al., 2014; Zhang et al., 2015). The present results showed IGF-1 significantly increased after RME and this original result might be related to the improvement of the AHI. Nevertheless statistically significant, the increase in IGF-1 detected in treated group might not be clinically significant. The evidence of metabolic and/or hormonal changes in patients after RME due to changes of the breathing pattern might open new points of view for diagnosis and treatment planning. The present results should be interpreted with caution for the originality of the subject and the exiguity of the sample, even though satisfying the power analysis. Further patients should be enrolled and further studies should be performed on the effects of RME on general health of growing patients and its possible effects on somatic growth due to restored nasal breathing, especially since RME represents one of the most widespread treatments in orthodontic practice.

Clinical Considerations

This is the first study investigating changes in growth mediators after changes in the brething pattern related to RME. AHI showed statistically significant changes but they were probably not as large to detect a significant improvement in SpO_2. Nevertheless IGF-1 significantly increased after RME and this original result might be related to the improvement of the AHI. The clinical significance of this results, however, should be confirmed by further studies.

CONCLUSIONS

According to the results of the present RCT the following conclusions might be drawn:

- Growing patients presenting mild OSA showed significant improvement of AHI after RME when compared to control, even though the decrease was not clinically followed by a statistically significant improvement of SpO_2;
- AHI significant improvement was accompanied by a significant improvement of IGF-1 in patients undergone RME when compared to untreated control and this was the original finding of the present RCT.

Even though exciting results were carried out from the present RCT further studies should be performed to deepen the knowledge and understanding of the possible effects of RME on patients' general health.

FUTURE PERSPECTIVES

On the basis of the results of the present thesis and previous literature the following research project was developed and will be object of future investigations. The possibility of exploring IGF-1 effects on craniofacial growth and at the same time the effects of orthopedic and functional therapy on these mediators opens new scenarios on the research of mandibular growth, which is of maximum interest in orthotontic research and practice. A brief description of the future project will follow.

Effects of administration of insulin-like growth factor-I on mandibular condylar chondrocytes in different malocclusions.

Background

Class II and Class III malocclusion are associated with different condylar growth patterns suggesting an important genetic key role for some malocclusion, especially for mandibular prognathism. It is still controversy if condylar cartilage might be stimulated or inhibited by orthodontic appliances. The condylar cartilage might play an important role in growth and treatment of these malocclusions. IGF-1 was suggested to be a key growth factor exerting its actions to stimulate proliferation and differentiation of chondrocytes by endocrine and paracrine/autocrine mechanism in association with its receptor (IGF-1R). In previous investigations on condylar hyperplasia chondrocytes (CH) the proliferation capacity of CH chondrocytes was showed to be significantly declined by the supplement of NVP-AEW541, which is a specific inhibitor against IGF-1R, while normal chondrocytes (NC) cells proliferated rapidly with the exposure of IGF-1. IGF-1 induces the sequential activation of MAPK, which then activates 'classical' MAPK family members like extracellular-signal-

regulated kinase 1/2 (ERK1/2), ERK5. Activated ERK1/2 transmits extracellular signals to the nucleus and induces immediate early genes associated with cell-cycle. It is widely accepted that chondrocytes proliferation is initiated by cell-cycle entry, which is mainly promoted by transcription factors and protein kinases, such as Cyclin D1 and CDK2. A previous study demonstrated that such two gene expression levels in CH cells were significantly higher than those in NC cells, which suggests that increased cell-cycle entry signals transmit in CH cell nucleus to start cellular proliferation. Besides, when ERK1/2 was blocked by U0126, Cyclin D1 and CDK2 messenger RNA (mRNA) down-regulated to similar levels of those in NC cells, which indicated that MAPKeERK pathway plays important roles to mediate such signals transmitting from extracellular into CH cellular nucleus.

Growth of the mandibular ramus

Endochondral bone formation in the condylar cartilage and bone apposition in the lower border of the mandible (gonial region) contribute to the growth in height of the mandibular ramus. Studies on mandibular condylar cartilage have shown that the cartilage not only is a passive growth site, but also is endowed with some tissue-separating potential (Copray et al., 1986; Rönning et al., 1991). It has also been maintained to be active in displacing the condylar process downwards (Kantomaa et al., 1984). In addition, the mandibular condylar cartilage seems to be a target and production site of hormonal agents as evidenced by IGF I receptor and IGF I messenger RNA expression in the cartilage (Visnapuu et al., 2001; 2002). Patients with GH deficiency have been shown to have a small posterior face height compared with age and gender-matched healthy controls (Karsila-Tenovuo et al., 2001). Furthermore, administration of GH to patients with GH deficiency, such as those with Turner syndrome or in bone marrow transplant patients, has clearly shown that mandibular growth, and particularly mandibular ramus growth, is accelerated compared with control children (Dahllöf et al., 1991;

Simmons, 1999). The increase in mandibular ramus height by GH can be explained by two, possibilities. Firstly, increased endochondral bone formation in the condylar cartilage and secondly, increased bone apposition in the lower border of the mandible through the anabolic effects of GH on the masseter and medial pterygoid muscles (Vogl et al., 1999).

Effects of IGF-1 on condylar chondrocytes

Insulin-like growth factors 1 (IGF-1) exerts important roles in human growth and development (Maki et al., 2010). IGF-1 regulates the metabolism like increasing lipid, glycogen, and protein synthesis. IGF-1 has effects on muscle and bone by stimulating proliferation and promoting differentiation of myoblastic or osteoblastic tissues (Maki et al., 2010). In the growth plate of longitudinal bone, IGF-1 is a key growth factor exerting its actions to stimulate proliferation and differentiation of chondrocytes by endocrine and paracrine/autocrine mechanism (Wu et al., 2008). The IGF-1 receptor (IGF-1R), acting as a docking protein for the downstream signaling transduction, is overexpressed in many tumors and have vastly different functions like mediates cancer cells proliferation, motility and apoptosis protection (Harrington et al., 1994; Bordt et al., 2000).

Concerning the unique role of the IGF-1 in somatic development, recent studies have started focusing on the relationship between IGF-1 and TMJ condyle cartilage growth. IGF-1 regulated adaptive remodeling of mandibular condylar cartilage by an onset or enhanced proliferation of chondrocytes (Shen et al., 2005). Elevated expressions of IGF-1 and IGF-1R were found in cartilage and bone of active condylar hyperplasia (CH) (Gotz et al., 2007). Also, previous study showed that strong immunostaining of IGF-1 was in the proliferative chondrocyte layer and the hypertrophic chondrocyte layer (Meng et al., 2011), indicating that the abnormality of the cartilage growth in CH is probably attributed to IGF-1 overexpression.

Chondrocytes proliferation in condylar hyperplasia compared to normal condylar cells

In former studies, chondrocytes were proved to have a tendency to dedifferentiate if they grew in monolayer culture (De Ceuninck et al., 2004). Previous authors found the round CH chondrocytes rapidly transformed into flattened fibroblast-like cells in the monolayer culture, and lost their high proliferation capacity as the same as normal condylar (NC) chondrocytes did (Chen et al., 2012). The classic experiments on chondrocyte culture suggested three-dimensional culture offers a scaffolding material maintaining the original chondrocyte phenotype as it facilitates chondrocytes aggregate and mimic vivo environment (De Ceuninck et al., 2004). Therefore, alginate beads culture was preferred in previous study (Chen et al., 2012) as such method avoids passage culture and enables cells continue to proliferate, maintain their phenotypes (Finger et al., 2003). The initial stage of condylar growth and remolding undergoes chondrogenesis, which results from the chondrocytes proliferation. Previous findings (Chen et al., 2012) showed that CH chondrocytes possess higher proliferation capacity than NC chondrocytes, which is in agreement with the histopathological results that the actively growing type of CH condyles was characterized by a broad proliferation zone or mesenchyme layer (Eslami et al., 2003; Farina et al., 2011). In previous study from immunohistochemistry analysis had found that the expressions of IGF-1 were strong in the active CH condyle and presented mainly in the proliferative chondrocyte layer (Meng et al., 2011). In this study, ELISA and western blotting results demonstrated that CH chondrocytes significantly increased IGF-1 and IGF-1R protein production levels than NC chondrocytes.

The proliferation capacity of CH chondrocytes was showed to be significantly declined by the supplement of NVP-AEW541, which is a specific inhibitor against IGF-1R, while NC cells proliferated rapidly with the exposure of IGF-1 (Chen et al., 2012). Furthermore, treatment of NVP-AEW541 significantly suppressed the expression levels of specific genes associated with cellular proliferation control and cell cycling. Thus, these findings demonstrated that the enriched IGF-1 in CH cartilage enhanced CH chondrocytes proliferation. Besides, using NVP-AEW541, IGF-1 induced its own synthesis in chondrocytes. The elevated IGF-1 in CH cartilage is the production of local chondrocytes suggesting that the secreted IGF-1 from CH chondrocytes is utilized by themselves to enhanced chondrocytes proliferation. Subsequently, increased chondrocytes in CH cartilage continue to produce IGF-1, which keeps an aberrant high concentration level in local cartilage. This positive feedback loop indicated that IGF-1 is a potent growth factor in the CH pathological development process. Collectively, the abnormality of cartilage growth in CH is attributed to IGF-1 overexpression for autocrine driven proliferation. Another important factor in the cartilage growth pattern is matrix synthesis (Enlow et al., 1992). Previous findings (Chen et al., 2012) showed an enhanced gene expression level of COL2A1 in CH chondrocytes, and IGF-1 promoted the expression of COL2A1 in chondrocytes, suggesting IGF-1 participates in the CH pathological development partially through augmenting matrix synthesis capacity of chondrocytes. When treated with NVP-AEW541, CH chondrocytes did not remarkably alter the expression levels of COL2A1, indicating that IGF-1 may not be the only critical factor affecting the matrix synthesis of CH chondrocytes. Cellular hypertrophy is an important factor for cartilage interstitial growth (Luder et al., 1988). Collagen Type X is known to be a marker for hypertrophic chondrocytes (Acharya et al., 2012). In previous study (Chen et al., 2012), CH chondrocytes exhibited a low expression of COL10A1 gene and no significant alteration of such gene expression in

chondrocytes when treated with IGF-1 or NVP-AEW541, which suggested that IGF-1 would not mediate chondrocytes toward hypertrophic differentiation in the process of CH development. Some studies have shown that IGF-1 modulates the proliferation of somatic cells, such as tendon cells and costal chondrocytes, by activating two major intracellular signaling pathways, MAPK and PI3K pathway (Hopkins et al., 2010; Feng et al., 2010). It is notable that different cell types comprise the specific signaling pathways involved in IGF-1-induced proliferation. For example, MAPK pathway is exclusively involved in the IGF-1-induced cellular proliferation of myoblasts and adipocytes, while stimulation of MCF-7 mammary tumors and brain capillary cellular proliferation by IGF-1 is mediated via PI3K pathway. In addition, in mammary epithelial cells, IGF-1 induce cellular proliferation via both two pathways. To determine pathways responding to IGF-1-induced CH chondrocytes proliferation, previous study (Chen et al., 2012) used two specific pharmacological inhibitors, U0126 and LY294002. As a result, U0126 but not LY294002, significantly inhibited cellular proliferation indicating MAPKeERK pathway is mainly responsible for IGF-1 induced CH chondrocytes proliferation. IGF-1 induces the sequential activation of MAPK, which then activates 'classical' MAPK family members like extracellular-signal-regulated kinase 1/2 (ERK1/2), ERK5 (Nishimoto et al., 2006; Wang et al., 2006). Activated ERK1/2 phosphorylates transcription factors and protein kinases, thereby transmitting extracellular signals to the nucleus and inducing immediate early genes associated with cell-cycle. It is widely accepted that chondrocytes proliferation is initiated by cell-cycle entry, which is mainly promoted by transcription factors and protein kinases, such as Cyclin D1 and CDK2. The previously cited study (Chen et al., 2012) demonstrated that such two gene expression levels in CH cells were significantly higher than those in NC cells, which suggests that increased cell-cycle entry signals transmit in CH cell nucleus to start cellular proliferation.

Besides, when ERK1/2 was blocked by U0126, Cyclin D1 and CDK2 messenger RNA (mRNA) down-regulated to similar levels of those in NC cells, which indicated that MAPKeERK pathway plays important roles to mediate such signals transmitting from extracellular into CH cellular nucleus. Interestingly, even in the long-term culture, CH chondrocytes proliferation started to stagnated since from the fourth week. By telomeric repeat amplification protocol assay, the authors found no detectable telomerase activity in CH chondrocytes, which suggested CH chondrocyte is not a kind of immortalized cell (Shi et al., 2002). Furthermore, silver staining combined light microscopic examination experiment showed no cytologic and nuclear atypia in CH chondrocytes and no difference in mitotic counts between CH and NC cells. These findings implied that CH chondrocyte is not a kind of immortalized or tumor-like cell.

On the basis of previous studies IGF-1 promotes human TMJ cartilage overgrowth in the CH developing process by enhancing chondrocytes proliferation via MAPK-ERK pathway. These results might be helpful to explore new frontiers in condylar growth.

Role of condylar cartilage growth in orthodontics

Class II and Class III malocclusion in Orthodontics are associated with different skeletal growth pattern involving also condylar growth. Moreover several findings suggested genetic key role for some malocclusion, especially for mandibular prognathism (Doraczynska-Kowalik et al., 2017).

It is still controversy if condylar cartilage might be stimulated or inhibited by orthodontic appliances (Nucera et al., 2016; Deguchi et al., 2002). The condylar cartilage might play an important role in growth and treatment of these malocclusion and the detailed study of the previously mentioned processes might explain the real regulation of chondrocytes proliferation in different malocclusion with different genotypes and phenotypes.

Aim

The aim of the present study is therefore to investigate whether IGF-1 regulates chondrocytes proliferation and the precise molecular mechanism that occurred in chondrocytes harvested from human condyles in different malocclusions. Second aim of the present study will be to deepen the knowledge of the MAPKeERK pathway involved in cellular proliferation of condylar cartilage chondrocytes in different malocclusions, giving the cells stimulation or inhibition factors of cellular proliferation over this pathway.

REFERENCES

Acar YB, Motro M, Everdi N. A new indicator showing maxillary resistance in rapid maxillary expansion cases? Angle Orthod. 2015; 85:109–16.

Acar YB, Motro M, Everdi N. Three-dimensional densitometric analysis of maxillary sutural changes induced by rapid maxillary expansion. Dentomaxillofac. Radiol. 2013; 42, 71798010.

Acharya C, Adesida A, Zajac P, Mumme M, Riesle J, Martin I, et al. Enhanced chondrocyte proliferation and mesenchymal stromal cells chondrogenesis in coculture pellets mediate improved cartilage formation. J Cell Physiol. 2012;227:88e97.

Angell EC. Treatment of irregularity of the permanent or adult teeth. Dental Cosmos. 1860;1:540-44.

Baccetti T, Franchi L, Cameron CG, McNamara JA Jr. Treatment timing for rapid maxillary expansion. Angle Orthodontist 2001;71:343-50.

Ballanti F, Lione R, Fanucci E, Franchi L, Baccetti T, Cozza P. Immediate and Post-Retention Effects of Rapid Maxillary Expansion Investigated by Computed Tomography in Growing Patients. Angle Orthod. 2009;79:24-9.

Bar A, Tarasiuk A, Segev Y, Phillip M , Tal A. The effect of adenotonsillectomy on serum insulin-like growth factor-I and growth in children with obstructive sleep apnea syndrome . Journal of Pediatrics 1999; 135:76-80.

Baratieri C, Alves M Jr, Sant'anna EF, Nojima MC, Nojima LI. 3D mandibular positioning after rapid maxillary expansion in Class II malocclusion. Braz Dent J. 2011; 22(5):428–34.

Baratieri C, Alves M Jr., de Souza MM, de Souza Araújo MT, Maia LC. Does rapid maxillary expansion have long-term effects on airway dimensions and breathing? Am J Orthod Dentofacial Orthop. 2011;140:146-56.

Beebe DW, Gozal D. Obstructive sleep apnea and the prefrontal cortex: towards a comprehensive model linking nocturnal upper airway obstruction to daytime cognitive and behavioral deficits. J Sleep Res. 2002;11:1-16.

Behlfelt K, Linder-Aronson S, McWilliam J, Neander P, Laage-Hellman J. Cranio-facial morphology in children with and without enlarged tonsils. European Journal of Orthod. 1999;12:233–43.

Bell RA, LeCompte EJ. The effects of maxillary expansion using a quad-helix appliance during the deciduous and mixed dentitions. Am J Orthod. 1981;79:152–161.

Blum WF, Albertsson-Wikland K, Rosberg S, Ranke MB. Serum levels of insulin-like growth factor I (IGF-I) and IGF binding protein 3 reflect spontaneous growth hormone secretion. J Clin Endocrinol Metab. 1993;76:1610-6.

Brodt P, Samani A, Navab R. Inhibition of the type I insulin-like growth factor receptor expression and signaling: novel strategies for antimetastatic therapy. Biochem Pharmacol. 2000;60:1101e7.

Brown GVI. The application of orthodontic principles to the prevention of nasal disease. Dent. Cosmos.1903;45:765-75.

Caprioglio A, Bergamini C, Franchi L, Vercellini N, Zecca PA, Nucera R, Fastuca R. Prediction of Class II improvement after rapid maxillary expansion in early mixed dentition. Prog Orthod. 2017 Dec;18(1):9.

Caprioglio A, Fastuca R, Zecca PA, Beretta M, Mangano C, Piattelli A, Macchi A, Iezzi G. Cellular Midpalatal Suture Changes after Rapid Maxillary Expansion in Growing Subjects: A Case Report. Int J Mol Sci. 2017 Mar;11;18(3).

Caprioglio A, Meneghel M, Fastuca R, Zecca PA, Nucera R, Nosetti L. Rapid maxillary expansion in growing patients: Correspondence between 3-dimensional airway changes and polysomnography. Int J Pediatr Otorhinolaryngol. 2014 Jan;78(1):23-7.

Caprioglio A, Zucconi M, Calori G, Troiani V. Habitual snoring, OSA and craniofacial modification. Orthodontic clinical and diagnostic aspects in a case control study. Minerva Stomatol. 1999 Apr;48(4):125-37.

Chan KC, Au CT, Chook P, et al. Endothelial function in children with OSA and the effects of adenotonsillectomy. Chest. 2015;147:132-9.

Chang Y, Koenig LJ, Pruszynski JE, Bradley TG, Bosio JA, Liu D. Dimensional changes of upper airway after rapid maxillary expansion: A prospective cone-beam computed tomography study. Am J Orthod Dentofacial Orthop.2013;143:462-70.

Chen B, Dowlatshahi D, MacQueen GM, et al. Increased hippocampal BDNF immunoreactivity in subjects treated with antidepressant medication. Biol Psychiatry.2001;50:260-5.

Chen Y, Ke J, Long X, Meng Q, Deng M, Fang W, Li J, Cai H, Chen S. Insulin-like growth factor-1 boosts the developing process of condylar hyperplasia by stimulating chondrocytes proliferation. Osteoarthritis Cartilage. 2012 Apr;20(4):279-87.

Cleall, JF, Bayne DI, Posen J, Subtenly JD. Expansion of the midpalatal suture in the monkey. Angle Orthod. 1965;35:23–35.

Copray JC, Brouwer N, Prins AP, Jansen HW. Effects of polypeptide growth factors on mandibular condylar cartilage of the rat in vitro. J Biol Buccale. 1988 Jun;16(2):109-17.

Copray JC, Jansen HW, Duterloo HS. Growth and growth pressure of mandibular condylar and some primary cartilages of the rat in vitro. American Journal of Orthodontics and Dentofacial Orthopedics. 1986; 90:19–28.

Cordasco G, Nucera R, Fastuca R, Matarese G, Lindauer SJ, Leone P, et al. Effects of orthopedic maxillary expansion on nasal cavity size in growing subjects: A low dose computer tomography clinical trial. Int J Pediatr Otorhinolaryngol. 2012;76:1547-51.

Da Silva Filho OG, Montes LA, Torelly LF. Rapid maxillary expansion in the deciduous and mixed dentition evaluated through posteroanterior cephalometric analysis. Am. J. Orthod. Dentofacial. Orthop. 1995;107:268–275.

Dahllöf G Forsberg CM, Näsman M, Mattsson T, Modéer T, Borgström B, Bolme P, Ringdén O. Craniofacial growth in bone marrow transplant recipients treated with growth hormone after total body irradiation. Scandinavian Journal of Dental Research 1991;99:44–47.

De Ceuninck F, Lesur C, Pastoureau P, Caliez A, Sabatini M. Culture of chondrocytes in alginate beads. Methods Mol Med. 2004;100:15e22.

Deguchi T, Kuroda T, Minoshima Y, Graber TM. Craniofacial features of patients with Class III abnormalities: growth-related changes and effects of short-term and long-term chincup therapy. Am J Orthod Dentofacial Orthop. 2002 Jan;121(1):84-92.

Doraczynska-Kowalik A, Nelke KH, Pawlak W, Sasiadek MM, Gerber H. Genetic Factors Involved in Mandibular Prognathism. J Craniofac Surg. 2017 Jul;28(5):e422-e431.

Doruk C, Sökücü O, Biçakçi AA, Yilmaz U, Tas F. Comparison of nasal volume changes during rapid maxillary expansion using acoustic rhinometry and computed tomography. Eur J Orthod 2007;29:251-5.

Ekstrom C. Hericsson C, Jensen R. Mineralization in the midpalate suture after orthodontic expansion. Am J. Orthod Dentofaciqal Orthop.1977;2:449-5.

El H, Palomo JM. Three-dimensional evaluation of upper airway following rapid maxillary expansion. Angle Orthod. 2014; 84(2):265–73.

Enlow DH, Pfister C, Richardson E, Kuroda T. An analysis of Black and Caucasian craniofacial patterns. Angle Orthod. 1982; 52:279e87.

Enoki C, Cardoso F, Campos F, Elias A, Matsumoto M, Terezinha W. Effects of rapid maxillary expansion on the dimension of the nasal cavity and on nasl air resistance. Int J of Pediatric Otorhinol. 2006;70:1225-30.

Eslami B, Behnia H, Javadi H, Khiabani KS, Saffar AS. Histopathologic comparison of normal and hyperplastic condyles. Oral Surg Oral Med Oral Pathol Oral Radiol Endod. 2003;96: 711e7.

Esteitie R, Emani J, Sharma S, Suskind DL, Baroody FM. Effect of fluticasone furoate on interleukin 6 secretion from adenoid tissues in children with obstructive sleep apnea. Arch Otolaryngol Head Neck Surg. 2011;137:576-82.

Farina RA, Becar M, Plaza C, Espinoza I, Franco ME. Correlation between single photon emission computed tomography, AgNOR count, and histomorphologic features in patients with active mandibular condylar hyperplasia. J Oral Maxillofac Surg. 2011;69:356e61.

Fastuca R, Lorusso P, Lagravère MO, Michelotti A, Portelli M, Zecca PA, D' Antò V, Militi A, Nucera R, Caprioglio A. Digital evaluation of nasal changes induced by rapid maxillary expansion with different anchorage and appliance design. BMC Oral Health. 2017 Jul14;17(1):113.

Fastuca R, Meneghel M, Zecca PA, Mangano F, Antonello M, Nucera R, Caprioglio A. Multimodal airway evaluation in growing patients after rapid maxillary expansion. Eur J Paediatr Dent. 2015 Jun;16(2):129-34.

Fastuca R, Perinetti G, Zecca PA, Nucera R, Caprioglio A. Airway compartments volume and oxygen saturation changes after rapid maxillary expansion: a longitudinal correlation study. Angle Orthod. 2015 Nov;85(6):955-61.

Fastuca R, Zecca P, Caprioglio A. Role of mandibular displacement and airway size in improving breathing after rapid maxillary expansion. Progr in Orth. 2014;15:40.

Feng Z, Levine AJ. The regulation of energy metabolism and the IGF-1/mTOR pathways by the p53 protein. Trends Cell Biol. 2010;20:427e34.

Filho R, de Oliveira Ruellas A. Long term maxillary changes in patients with skeletal class II maloclussion treated with slow and rapid palatal expansion. Am J Orthod Dentofacial Orthop. 2008; 134:383-8.

Finger F, Schorle C, Zien A, Gebhard P, Goldring MB, Aigner T. Molecular phenotyping of human chondrocyte cell lines T/C-28a2, T/C-28a4, and C-28/I2. Arthritis Rheum. 2003;48:3395e403.

Flores-Mir C, Korayem M, Heo G, Witmans M, Major MP, Major PW 2013. Craniofacial morphological characteristics in children with obstructive sleep apnea syndrome: A systematic review and meta-analysis. J Am Dent Assoc 144:269-77.

Franchi, L.; Baccetti, T.; Lione, R.; Fanucci, E.; Cozza, P. Modifications of midpalatal sutural density induced by rapid maxillary expansion: A low-dose computed-tomography evaluation. Am. J. Orthod. Dentofacial. Orthop. 2010;137:486–88.

Furlanetto RW. Insulin-like growth factor measurements in the evaluation of growth hormone secretion. Horm Res. 1990;33:25-30.

Garib DG, Menezes MHO, da Silva Filho OG, dos Santos PBD. Immediate periodontal bone plate changes induced by rapid maxillary expansion in the early mixed dentition: CT findings. Dental Press J Orthodontics. 2014;19(3):36–43.

Garrett B, Caruso J, Rungcharassaeng K, Farrage J, Kim J and Taylor G. Skeletal effects to the maxilla after rapid maxillary expansion assessed with cone-beam computed tomography. Am J Orthod Dentofacial Orthop. 2008;134:8.e1-8.e11.

Giuliani A. Analysis of bone response to dental bone grafts by advanced physical techniques. In: Piattelli A, editor. Bone response to dental implant materials: Elsevier Ltd; 2016. p. 229–46.

Görgülü S, Gokce SM, Olmez H, Sagdic D, Ors F. Nasal cavity volume changes after rapid maxillary expansion in adolescents evaluated with 3-dimensional simulation and modeling programs. Am J Orthod Dentofacial Orthop. 2011;140:633-40.

Gotz W, Lehmann TS, Appel TR, Rath-Deschner B, Dettmeyer R, Luder HU, et al. Distribution of insulin-like growth factors in condylar hyperplasia. Ann Anat. 2007;189:347e9.

Gozal D, Kheirandish-Gozal L, Serpero LD, Sans Capdevila O, Dayyat E. Obstructive sleep apnea and endothelial function in school-aged nonobese children: effect of adenotonsillectomy. Circulation. 2007;116:2307-14.

Guest SS, McNamara JA Jr, Baccetti T, Franchi L. Improving Class II malocclusion as a side-effect of rapid maxillary expansion: a prospective clinical study. Am J Orthod Dentofacial Orthop. 2010;138(5):582–91.

Guilleminault C, Monteyrol PJ, Huynh NT, Pirelli P, Quo S, Li K. Adeno-tonsillectomy and rapid maxillary distraction in pre-pubertal children, a pilot study. Sleep Breath. 2011;15:173–7.

Gümüssoy M, Atmaca S, Bilgici B, Unal R. Changes in IGF-I, IGFBP-3 and ghrelin levels after adenotonsillectomy in children with sleep disordered breathing. Int J Pediatr Otorhinolaryngol 2009;73:1653-6.

Haas AJ. Palatal expansion:just the beginning of Dentofacial orthodpedics. Am J. Orthod Dentofaciqal Orthop. 1970;57:219-55.

Haas AJ. Rapid Expansion of The Maxillary Dental Arch And Nasal Cavity By Opening The Midpalatal Suture. Angle Orthod. 1961;31:73-90.

Harrington EA, Bennett MR, Fanidi A, Evan GI. c-Myc-induced apoptosis in fibroblasts is inhibited by specific cytokines. EMBO J. 1994;13:3286e95.

Haskell JA, McCrillis J, Haskell BS, Scheetz JP, Scarfe WC and Farman AG. Effects of mandibular advancement device (MAD) on airway dimensions assessed with cone-beam computed tomography. Semin Orthodo. 2009;15:132-58.

Hershey HG, Stewart BL, Warren DW. Changes in nasal airway resistance associated with rapid maxillary expansion. Am J Orthod. 1976;69:274-84.

Hopkins A, Crowe PJ, Yang JL. Effect of type 1 insulin-like growth factor receptor targeted therapy on chemotherapy in human cancer and the mechanisms involved. J Cancer Res Clin Oncol. 2010;136:639e50.

Hou, B.; Fukai, N.; Olsen, B.R. Mechanical force-induced midpalatal suture remodeling in mice. Bone. 2007, 40, 1483–93.

Isaksson OG, Lindahl A, Nilsson A, Isgaard J. Mechanism of the stimulatory effect of growth hormone on longitudinal bone growth. Endocrinol Rev. 1987;8:426-38.

Iwasaki T, Saitoh I, Takemoto Y, Inada E, Kakuno E, Kanomi R, et al. Tongue posture improvement and pharyngeal airway enlargement as secondary effects of rapid maxillary expansion: A cone-beam computed tomography study. Am J Orthod Dentofacial Orthop. 2013;143:235-45.

Iwasaki T, Saitoh I, Takemoto Y, Inada E, Kanomi R, Hayasaki H, et al. Improvement of nasal airway ventilation after rapid maxillary expansion evaluated with computational fluid dynamics. Am J Orthod Dentofacial Orthop. 2012;141:269-78.

Izuka EN, Feres MF, Pignatari SS. Immediate impact of rapid maxillary expansion on upper airway dimensions and on the quality of life of mouth breathers. Dental Press J Orthod. 2015;20(3):43–9.

Jelic S, Padeletti M, Kawut SM, et al. Inflammation, oxidative stress, and repair capacity of the vascular endothelium in obstructive sleep apnea. Circulation. 2008;117:2270-8.

Johal A, Patel SI, Battagel JM. The relationship between craniofacial anatomy and obstructive sleep apnea: A case controlled study. J Sleep Res. 2007;16:319-26.

Juul A, Bang P, Hertel NT, et al. Serum insulin-like growth factor-I in 1030 healthy children, adolescents, and adults: relation to age, sex, stage of puberty, testicular size, and body mass index. J Clin Endocrinol Metab. 1994;78:744-52.

Kang JM, Auo HJ, Yoo YH, Cho JH, Kim BG. Changes in serum levels of IGF-1 and in growth following adenotonsillectomy in children. Int J Pediatr Otorhinolaryngol. 2008;72:1065-9.

Kantomaa T. Effect of functional change on cell differentiation in the condylar cartilage. J Anat. 1987 Jun;152:133-43.

Kantomaa T. The role of the mandibular condyle in the facial growth . Proceedings of the Finnish Dental Society. 1984; 80 : 1 – 57.

Karsila-Tenovuo S, Jahnukainen K, Peltomäki T, Minn H, Kulmala J, Salmi TT, Rönning O. Disturbances in craniofacial morphology in children treated for solid tumors. Oral Oncology 2001; 37:586 – 92.

Kerr WJ, McWilliam JS, Linder-Aronson S. Mandibular form and position related to changed mode of breathing--a five-year longitudinal study. Angle Orthod. 1989 Summer;59(2):91-6.

Lagravere MO, Major PW, Flores-Mir C. Long term skeletal changes with rapid maxillary expansion: a systematic review. Angle Orthod. 2005;75:1046-52.

Lee H, Ting K, Nelson M, Sun N, Sung S. Maxillary expansion in customized finite element method models. Am J Orthod Dentofacial Orthop. 2009;136:367-74.

Lenza MG, De Lenza MM, Dalstra M, Melsen B, Cattaneo PM. An analysis of different approaches to the assessment of upper airway morphology: a CBCT study. Orthod raniofac Rws. 2010;13:96-105.

Leonardi R, Caltabiano M, Cavallini C, Sicurezza E, Barbato E, Spampinato C, Giordano D. Condyle fossa relationship associated with functional posterior crossbite, before and after rapid maxillary expansion. Angle Orthod. 2012;82(6):1040–6.

Leonardi R, Sicurezza E, Cutrera A, Barbato E. Early post-treatment changes of circumaxillary sutures in young patients treated with rapid maxillary expansion. Angle Orthod. 2011;81:36-41.

Leonardi R, Sicurezza E, Cutrera A, Barbato E. Early post-treatment changes of circumaxillary sutures in young patients treated with rapid maxillary expansion. Angle Orthod. 2011 Jan;81(1):36-41.

Linder-Aronson S 1970 Adenoids: their effect on mode of breathing and nasal airflow and their relationship to characteristics of the facial skeleton and the dentition. Acta Oto-Laryngologica. Supplementum 265:pp.1-132.

Linder-Aronson S, Woodside D G , Lundström A. Mandibular growth direction following adenoidectomy . American Journal of Orthodontics. 1986; 89: 273 -84.

Linder-Aronson S. Respiratory function in relation to facial morphology and the dentition. British Journal of Orthodontics. 1979; 6:59–71.

Liu S, Xu T, Zou W. Effects of rapid maxillary expansion on the midpalatal suture: A systematic review. Eur. J. Orthod. 2015;37:651–55.

Luder HU, Leblond CP, von der Mark K. Cellular stages in cartilage formation as revealed by morphometry, radioautography and type II collagen immunostaining of the mandibular condyle from weanling rats. Am J Anat. 1988;182:197e214.

Madani D, Fariden Madani D: Definitions, abbreviations, and acronyms of sleep apnea. Atlas Oral Maxillofacial Surg N Am. 2007;15:69-80.

Maki RG. Small is beautiful: insulin-like growth factors and their role in growth, development, and cancer. J Clin Oncol. 2010;28:4985e95.

Marcus CL, Brooks LJ, Draper KA, et al. Diagnosis and management of childhood obstructive sleep apnea syndrome. Pediatrics. 2012;130:576–84.

Marcus CL, Moore RH, Rosen CL, et al. A randomized trial of adenotonsillectomy for childhood sleep apnea. N Engl J Med 2013; 368:2366.

Matsumoto MA, Itikawa CE, Valera FC, Faria G, Anselmo-Lima WT. Long-term effects of rapid maxillary expansion on nasal area and nasal airway resistance. Am J Rhinol Allergy. 2010;24:161-5.

McCrillis J, Haskell J, Haskell BS, Brammer M, Chenin D, Scarfe W and Farman A. Obstructive sleep apnea and the use of cone beam computed tomography in airway imaging: a review 2009;15:63-9.

McNamara JA Jr, Lione R, Franchi L, Angelieri F, Cevidanes LH, Darendeliler MA, Cozza P. The role of rapid maxillary expansion in the promotion of oral and general health. Prog Orthod. 2015;16:33.

McNamara JA, Sigler LM, Franchi L, Guest SS, Baccetti T. Changes in occlusal relationships in mixed dentition patients treated with rapid maxillary expansion. Angle Orthod. 2010;80:230–38.

McNamara Jr JA. 1981 Influence of respiratory pattern on craniofacial growth. Angle Orthodontist 51: 269 – 300.

Melsen, B. A histological study of the influence of sutural morphology and skeletal maturation on rapid palatal expansion in children. Trans. Eur. Orthod. Sot. 1972; 499–507.

Melsen, B. Palatal growth studied on human autopsy material. Am. J. Orthod. 1975; 68: 42–54.

Meng Q, Long X, Deng M, Cai H, Li J. The expressions of IGF-1, BMP-2 and TGF-beta1 in cartilage of condylar hyperplasia. J Oral Rehabil. 2011;38:34e40.

Montgomery WM, Vig PS, Staab EV, Matteson SR. Computed tomography: A three-dimensional study of the nasal airway. Am J Orthod. 1979;76:363-75.

Murray, J.M.; Cleall, J.F. Early tissue response to rapid maxillary expansion in the midpalatal suture of the rhesus moneky. J. Dent. Res. 1971,50:1654.

Nachalon Y, Lowenthal N, Greenberg-Dotan S, Goldbart AD. Inflammation and growth in young children with obstructive sleep apnea syndrome before and after adenotonsillectomy. Mediators Inflamm. 2014;2014:146893.

Natsios G, Pastaka C, Vavougios G, Zarogiannis SG, Tsolaki V, Dimoulis A, Seitanidis G, Gourgoulianis KI. Age, Body Mass Index, and Daytime and Nocturnal Hypoxia as Predictors of Hypertension in Patients With Obstructive Sleep Apnea. J Clin Hypertens (Greenwich). 2016 Feb;18(2):146-52.

Nieminen P, Löppönen T, Tolonen U, Lanning P, Knip M, Löppönen H. Growth and biochemical markers of growth in children with snoring and obstructive sleep apnea . Pediatrics. 2002;109:e55.

Nishimoto S, Nishida E. MAPK signalling: ERK5 versus ERK1/2. EMBO Rep 2006;7:782e6.

Nucera R, Lo Giudice A, Rustico L, Matarese G, Papadopoulos MA, Cordasco G. Effectiveness of orthodontic treatment with functional appliances on maxillary growth in the short term: A systematic review and meta-analysis. Am J Orthod Dentofacial Orthop. 2016 May;149(5):600-11.e3.

O'Brien LM, Serpero LD, Tauman R, Gozal D. Plasma adhesion molecules in children with sleepdisordered breathing. Chest. 2006;129:947-53.

Ohshima, O. Effect of lateral expansion force on the maxillary structure in Cynomolgus monkey. J. Osaka Dent. Univ. 1972;6:11–50.

Peltomäki T. The effect of mode of breathing on craniofacial growth--revisited. Eur J Orthod. 2007 Oct; 29(5):426-9.

Pirelli P, Saponara M, Guilleminault C. Rapid maxillary expansion in children with obstructive sleep apnea syndrome. Sleep. 2004;27:761–6.

Pirinen S, Majurin A, Lenko HL, Koski K. Craniofacial features in patients with deficient and excessive growth hormone. J Craniofac Genet Dev Biol. 1994 Jul-Sep;14(3):144-52.

Proffit. WR, Fields HW Jr. Contemporary orthodontics, ed 4. St Louis: Mosby;2007.

REFERENCES

Ribeiro AN, de Paiva JB, Rino-Neto J, Illipronti-Filho E, Trivino T, Fantini SM. Upper airway expansion after rapid maxillary expansion evaluated with cone beam computed tomography. Angle Orthod. 2012;82:458-63.

Ronchi P, Cinquini V, Ambrosoli A, Caprioglio A. Maxillomandibular advancement in obstructive sleep apnea syndrome patients: a restrospective study on the sagittal cephalometric variables. J Oral Maxillofac Res. 2013; 4(2):e5. eCollection 2013.

Rönning O , Peltomäki T. Growth potential of the rat mandibular condyle as an isogeneic transplant traversing the interparietal suture . Archives of Oral Biology. 1991; 36:203– 10.

Rosa M, Lucchi P, Manti G, Caprioglio A. Rapid palatal expansion in the absence of posterior cross-bite to intercept maxillary incisor crowding in the mixed dentition: a CBCT evaluation of spontaneous changes of untouched permanent molars. Eur J Paediatr Dent 2016;17:286-94.

Rose SR, Municchi G, Barnes KM, Kamp GA, Uriarte MM, Ross JL, Cassorla F, Cutler GB Jr Spontaneous GH secretion increases during puberty in normal girls and boys. J Clin Endocrinol Metab. 1991 Aug;73(2):428-35.)

Rosen CL, Storfer-Isser A, Taylor HG, et al. Increased behavioral morbidity in school-aged children with sleep-disordered breathing. Pediatrics 2004; 114:1640.

Rosenfeld RG, Hwa V, Wilson L, et al. The insulin-like growth factor binding protein superfamily: new perspectives. Pediatrics. 1999;104:1018-21.

Rungcharassaeng K, Caruso J, Kan J, Kim J, Taylor G. Factors affecting buccal bone changes of maxillary posterior teeth after rapid maxillary expansion. Am J Orthod Dentofacial Orthop 2007;132:428.e1-428.e8.

Sánchez-de-la-Torre M, Campos-Rodriguez F, Barbé F. Obstructive sleep apnoea and cardiovascular disease. Lancet Respir Med. 2013;1:61-72.

Selimoğlu E, Selimoğlu MA, Orbak Z. Does adenotonsillectomy improve growth in children with obstructive adenotonsillar hypertrophy? J Int Med Res 2003;31:84-7.

Sharabi Y, Dagan Y, Grossman E. Sleep apnea as a risk factor for hypertension (Review). Curr Opin Nephrol Hypertens 2004;13:359-64.

Shen G, Darendeliler MA. The adaptive remodeling of condylar cartilage e a transition from chondrogenesis to osteogenesis. J Dent Res 2005;84:691e9.

Shi S, Gronthos S, Chen S, Reddi A, Counter CM, Robey PG, et al. Bone formation by human postnatal bone marrow stromal stem cells is enhanced by telomerase expression. Nat Biotechnol. 2002;20:587e91.

Simmons K E. Growth hormone and craniofacial changes: preliminary data from studies in Turner’s syndrome . Pediatrics. 1999; 104:1021–24.

Simmons KE. Growth hormone and craniofacial changes: preliminary data from studies in Turner's syndrome. Pediatrics. 1999 Oct;104(4 Pt 2):1021-4.

Smith T, Ghoneima A, Stewart K, Liu S, Eckert G, Halum S, et al. Three-dimensional computed tomography analysis of airway volume changes after rapid maxillary expansion. Am J Orthod Dentofacial Orthop. 2012;141:618-26.

Solow B, Kreiborg S. Soft-tissue stretching: a possible control factor in craniofacial morphogenesis. Scandinavian Journal of Dental Research. 1977; 85: 505 – 07.

Solow B, Siersbæk-Nielsen S, Greve E. Airway adequacy, head posture, and craniofacial morphology. American Journal of Orthodontics. 1984; 86: 214–23.

Storey, E. Bone changes associated with tooth movement: A histological study of the effect of force in the rabbit, guinea pig and rat. Aust. Dent. J. 1955;59:147.

Subtelny JD 1954 The significance of adenoid tissue in orthodontia. Angle Orthodontist. 24:59–69.

Suresh KP, Chandrashekara S. Sample size estimation and power analysis for clinical research studies. J Hum Reprod Sci. 2012;5(1):7–13.

Tapanainen P, Knip M. Evaluation of growth hormone secretion and treatment. Ann Med 1992;24:237-47.

Tatlıpınar A, Atalay S, Esen E, Yılmaz G, Köksal S, Gökçeer T. The effect of adenotonsillectomy on serum insulin like growth factors and the adenoid/nasopharynx ratio in pediatric patients: a blind, prospective clinical study. Int J Pediatr Otorhinolaryngol. 2012;76:248-52.

Trotman CA , McNamara Jr JA, Dibbets JM , van der Weele LT. 1997 Association of lip posture and the dimensions of the tonsils and sagittal airway with facial morphology. Angle Orthodontist. 67:425–32.

Ugolini A, Cerruto C, Di Vece L, Ghislanzoni LH, Sforza C, Doldo T, et al. Dental arch response to Haas-type rapid maxillary expansion anchored to deciduous vs permanent molars: a multicentric randomized controlled trial. Angle Orthod. 2015;85(4):570–6.

Vig KWL. 1998 Nasal obstruction and facial growth: the strength of evidence for clinical assumptions. American Journal of Orthodontics and Dentofacial Orthopedics. 113: 603 – 11.

Villa MP, Rizzoli A, Miano S, Malagola C. Efficacy of rapid maxillary expansion in children with obstructive sleep apnea syndrome: 36 months of follow-up. Sleep Breath. 2011;15:179–84.

Visnapuu V, Peltomäki T, Rönning O, Syrjänen S. 2002 Distribution of insulin-like growth factor-I mRNA in the mandibular condyle and rib cartilage of the rat during growth . Archives of Oral Biology. 47:791–98.

Visnapuu V, Peltomäki T, Rönning O, Vahlberg T, Helenius H 2001 Growth hormone and insulin-like growth factor I receptors in the temporomandibular joint of the rat . Journal of Dental Research. 80:1903–07.

Vogl C ,Atchley WR ,Cowley DE , Crenshaw P ,Murray JD ,Pomp D. The epigenetic infl uence of growth hormone on skeletal development .Growth, Development, and Aging. 1993; 57: 163–82.

Wang X, Tournier C. Regulation of cellular functions by the ERK5 signalling pathway. Cell Signal. 2006;18:753e60.

Wang Y, Wang JJ, Zhao MQ, Liu SM, Li YZ. Changes of serum brain-derived neurotrophic factor in children with obstructive sleep apnoea-hypopnoea syndrome following adenotonsillectomy. J Int Med Res 2010;38:1942-51.

Warren D W, Spalding P M 1991 Dentofacial morphology and breathing: a century of controversy. In: Melsen B (ed.). Current controversies in orthodontics. Quintessence Publishing, Chicago, pp. 45–76.

Warren DW, Hershey HG, Turvey TA, Hinton VA, Hairfield WM. The nasal airway following maxillary expansion. Am J Orthod Dentofacial Orthop. 1987;91:111-6.

Wertz RA. Changes in nasal airflow incident to rapid maxillary expansion. Angle Orthod. 1968;38:1-11.

Wertz RA. Skeletal and dental changes accompanying rapid midpalatal suture opening. Am J Orthod. 1970;58:41-66.

Worsnop C, Kay A, Kim Y, Trinder J, Pierce R. Effect of age on sleep onset-related changes in respiratory pump and upper airway muscle function. Journal of Applied Physiology. 2000; 88:1831-9.

Wu S, Fadoju D, Rezvani G, De Luca F. Stimulatory effects of insulin-like growth factor-I on growth plate chondrogenesis are mediated by nuclear factor-kappaB p65. J Biol Chem. 2008;283:34037e44.

Zeng J, Gao X. A prospective CBCT study of upper airway changes after rapid maxillary expansion. Int J Pediatr Otorhinolaryngol. 2013;77(11):1805–10.

Zettergren-Wijk L, Forsberg CM, Linder-Aronson S. Changes in dentofacial morphology after adeno-/tonsillectomy in young children with obstructive sleep apnoea--a 5-year follow-up study. Eur J Orthod. 2006 Aug;28(4):319-26.

Zhang XM, Shi J, Meng GZ, et al. The effect of obstructive sleep apnea syndrome on growth and development in nonobese children: a parallel study of twins. J Pediatr 2015;166:646-50.e1.

Zhao Y, Nguyen M, Gohl E, Mah JK, Sameshima G, Enciso R. Oropharyngeal airway changes after rapid palatal expansion evaluated with cone-beam computed tomography. Am J Orthod Dentofacial Orthop. 2010;137 4 Suppl:S71-8.